

# Immunohistochemistry and next-generation sequencing for NTRK fusion detection in differentiated thyroid cancer of children, adolescents and young adults

Imunohistoquímica e sequenciamento nova geração para detecção de fusão NTRK em câncer diferenciado de tireoide em crianças, adolescentes e adultos jovens

Ana Clara Oliveira Tosta Telles<sup>1</sup>, Gabriel Jeferson Rodríguez Machado<sup>1</sup>, Juliana Lima von-Ammon<sup>1</sup>, Rafael Reis Campos da-Matta<sup>1</sup>, Taíse Lima Cerqueira de-Oliveira<sup>1</sup>, Fabyan Esberard de Lima Beltrão<sup>2</sup>, Alexandre Rolim da-Paz<sup>2</sup>, Fabio Hecht<sup>3</sup>, Guilherme de Castro Lopes<sup>4</sup>, Leonardo Freitas Boaventura Rios<sup>5</sup>, Bruno da Silva Lisboa<sup>5</sup>, Helton Estrela Ramos<sup>1</sup>

## ABSTRACT

**Introduction:** Pan-TRK immunohistochemistry staining can assess the protein expression from NTRK gene fusions. A little is known about its utility in differentiated thyroid cancer samples from children, adolescents, and young adults patients. **Objective:** Investigate pan-TRK immunohistochemistry sensitivity and specificity in differentiated thyroid cancer samples from children, adolescents, and young adults patients. **Methods:** Tumor samples obtained from 79 children, adolescents, and young adults patients (age <21 years) diagnosed with differentiated thyroid cancer between January, 2010 and January, 2021 were retrospectively recruited from four health centers from state of Bahia e Paraíba, Brazil. NTRK gene fusion testing of all archival FFPE tumor samples: pan-TRK immunohistochemistry staining for TRKA, TRKB and TRKC protein expression were performed and then analyzed with RNA-based next-generation sequencing assay to confirm immunohistochemistry pan-TRK result and elucidate fusion partner. **Results:** Pan-TRK immunohistochemistry: 3 of 79 cases had positive pan-TRK expression: next-generation sequencing; 4 were identified with NTRK gene fusion, pan-TRK immunohistochemistry was negative in all 4 NTRK next-generation sequencing-positive cases. 25 of 79 NTRK next-generation sequencing-negative control cases had concordant negative pan-TRK immunohistochemistry results. Therefore, our rate of false positive pan-TRK immunohistochemistry results was 3/25 (12%). The overall results for pan-TRK immunohistochemistry in our cohort of next-generation sequencing-negative cases was: (i) sensitivity (0%), (ii) specificity (96%), (iii) positive predictive value (94.7%), (iv) negative predictive value (91%). **Conclusion:** Pan-TRK immunohistochemistry was not a tissue-efficient screen for NTRK fusions in differentiated thyroid cancer from children, adolescents, and young adults patients. This is the largest cohort of from children, adolescents, and young adults differentiated thyroid cancer cases stained with pan-TRK immunohistochemistry, and it is the first to detail the sensitivity and specificity of pan-TRK immunohistochemistry regarding the data obtained by targeted RNA-based next-generation sequencing panel in differentiated thyroid cancer.

**Keywords:** Immunohistochemistry; Thyroid cancer, Papillary; Child; Adolescent.

1. Federal University of Bahia, Department of Biorregulation, Health & Sciences Institute - Salvador - Bahia - Brazil.
2. Federal University of Paraíba, Lauro Wanderley University Hospital - João Pessoa - Paraíba - Brazil.
3. Federal University of Rio de Janeiro, The Institute of Biophysics Carlos Chagas Filho - Rio de Janeiro - Rio de Janeiro - Brazil.
4. Pardini Group, Department of Molecular Genetics - Vespasiano - Minas Gerais - Brazil.
5. State University of Feira de Santana, Department of Health - Feira de Santana - Bahia - Brazil.

**Financial support:** none to declare.

**Conflicts of interest:** The authors declare no conflict of interest relevant to this manuscript.

**Correspondence author:** Helton Estrela Ramos.

E-mail: ramoshelton@gmail.com

**Received on:** November 17, 2023 | **Accepted on:** March 19, 2024 | **Published on:** May 2, 2024

**DOI:** <https://doi.org/10.5935/2526-8732.20240456>

## RESUMO

**Introdução:** A coloração imuno-histoquímica Pan-TRK pode avaliar a expressão proteica de fusões de genes NTRK. Pouco se sabe sobre sua utilidade em amostras diferenciadas de câncer de tireoide de crianças, adolescentes e adultos jovens. **Objetivo:** Investigar a sensibilidade e especificidade da imuno-histoquímica pan-TRK em amostras diferenciadas de câncer de tireoide de pacientes crianças, adolescentes e adultos jovens. **Métodos:** Amostras tumorais obtidas de 79 pacientes crianças, adolescentes e adultos jovens (idade <21 anos) com diagnóstico de câncer diferenciado de tireoide entre janeiro de 2010 e janeiro de 2021 foram recrutadas, retrospectivamente, em quatro centros de saúde dos estados da Bahia e Paraíba, Brasil. Teste de fusão genética NTRK de todas as amostras de tumor FFPE arquivadas: coloração imuno-histoquímica pan-TRK para expressão da proteína TRKA, TRKB e TRKC foi realizada e depois analisada com ensaio de sequenciamento de próxima geração baseado em RNA, para confirmar o resultado imuno-histoquímico pan-TRK e elucidar o parceiro de fusão. **Resultados:** Imunohistoquímica pan-TRK: 3 de 79 casos tiveram expressão pan-TRK positiva: sequenciamento de próxima geração; 4 foram identificados com fusão do gene NTRK, a imuno-histoquímica pan-TRK foi negativa em todos os 4 casos positivos para sequenciamento de próxima geração de NTRK. 25 dos 79 casos de controle negativo para sequenciamento de próxima geração de NTRK tiveram resultados de imuno-histoquímica pan-TRK negativos concordantes. Portanto, nossa taxa de resultados de imuno-histoquímica pan-TRK falsos positivos foi de 3/25 (12%). Os resultados gerais da imuno-histoquímica pan-TRK em nossa coorte de casos negativos para sequenciamento de próxima geração foram: (i) sensibilidade (0%), (ii) especificidade (96%), (iii) valor preditivo positivo (94,7%), (iv) valor preditivo negativo (91%). **Conclusão:** A imuno-histoquímica pan-TRK não foi uma triagem tecidualmente eficiente para fusões de NTRK em pacientes com câncer diferenciado de tireoide em crianças, adolescentes e adultos jovens. Esta é a maior coorte de casos de câncer diferenciado de tireoide de crianças, adolescentes e adultos jovens corados com imunohistoquímica pan-TRK, e é a primeira a detalhar a sensibilidade e especificidade da imunohistoquímica pan-TRK em relação aos dados obtidos por RNA direcionado baseado em um painel de sequenciamento de próxima geração no câncer diferenciado de tireoide.

**Descritores:** Imunohistoquímica; Câncer papilífero de tireoide; Criança; Adolescente.

## INTRODUCTION

Differentiated thyroid carcinoma (DTC) is rare in children, ranging from 0.3-0.5% of all pediatric neoplasms, but remains the most common endocrine malignancy in this age group and represents the third most common pediatric solid tumor.<sup>[1,2]</sup> DTC in children and young adult patients seems to behave differently from tumors in adults, as they are more advanced and have more aggressive characteristics at diagnosis and in their clinical course. It is important to recognize the oncogenic drivers involved in this population so that a specific treatment can be offered for these neoplasms in this population.<sup>[3,4]</sup>

More recently, rearrangements of other proto-oncogenes have also been observed in papillary thyroid cancer (PTC) in association with exposure to ionizing radiation, with gene fusions activating the MAPK signaling pathway: the three NTRK genes (NTRK1, NTRK2, and NTRK3) each encode a distinct TRK protein, such as TRKA, TRKB and TRKC, respectively.<sup>[5,6]</sup> NTRK fusions have been identified

with low prevalence ranging from 2,28%-18% in DTC, except from a high prevalence demonstrated in a United States cohort, but few studies have analyzed NTRK fusions in children, adolescents and young adults (CAYA) patients.<sup>[7-11]</sup> There are four options for testing NTRK fusions, in order of complexity and cost: immunohistochemistry (IHC), FISH (fluorescence in situ hybridization), RT-PCR (reverse transcription polymerase chain reaction) and NGS (next-generation sequencing). In contrast to these assays, the use of IHC provides several benefits like a quick turnaround time, lower cost, wide availability, and use of very limited tissue.<sup>[12-14]</sup>

Pan-TRK IHC staining using clone EPR17341 (Abcam, Cambridge, MA), a rabbit recombinant monoclonal antibody, can assess the protein expression and has been used in several recent studies with a sensitivity and specificity of around 85-90% and 80%, respectively. Although this method is widely used, its effectiveness is still questionable, and another method is needed to confirm the

positive cases. The most used confirmation method is the NGS that has a high sensitivity of virtually 100% in RNA based sequencing.<sup>[15,16]</sup>

In order to evaluate the main tests used in clinical practice for *NTRK* fusion detection in pediatric thyroid cancer, the objective of this study was to investigate pan-TRK IHC sensitivity and specificity in DTC samples from CAYA patients correlated with NGS method. In our study, IHC were chosen for *NTRK* fusion screening because of its low cost, easy execution and availability and NGS was elected as the second method considering the sensitivity of this technique.

## MATERIAL AND METHODS

### *Subjects, samples and study design*

We performed a retrospective multicenter cross-sectional study with 79 cases of DTC in CAYA patients 21 years or younger diagnosed and treated at four centers: (i) Aristides Maltez Hospital (HAM), Salvador-Brazil; (ii) IT - Instituto Integrado de Endocrinologia e Cirurgia, Salvador, Brazil; (iii) Santa Casa de Misericórdia (SCMFS), Feira de Santana, Brazil; and Lauro Wanderley University Hospital (HULW), João Pessoa, Brazil; between January 2010 and March 2021. Non-consecutive patients were selected (non-probabilistic sampling, for convenience) and their tumor samples, fixed in formalin and preserved in paraffin (FFPE) blocks, resulting from surgical resections of the thyroid performed by the head and neck surgery services of the respective hospitals.

The cases were selected after researching patients who were diagnosed with malignant thyroid neoplasms on anatomopathological examination (code C.73, according to the International Statistical Classification of diseases and Related Health Problems; ICD) and who were registered in a database available in the internal electronic system of the services of pathological anatomy from participating centers with diagnosis of DTC. After the selection of patient, a search was performed for the respective slides stained with hematoxylin-eosin (HE), previously prepared at the time of the anatomopathological diagnosis, as well as the respective paraffin blocks containing tumor tissue. Both blocks and blades were kept in their respective services. On occasions when slides were absent or inadequate for evaluation and identification of the tumor area, new slides were made and stained with HE. To confirm the diagnosis of DTC, the HE slides were subjected to blind-review by two pathologists linked to the institutions participating in the study (M.V.P., R.S.).

Tumor slides were classified according to the World Health Organization's World Tumor Classification criteria and staged according to the AJCC Cancer Staging Manual, 8<sup>th</sup> edition.<sup>[17,18]</sup> From the microscopic evaluation of the sample by the pathologists, the tumor area was described by direct marking on the slide stained with HE. During the review of the slides, the data related to the patient

and the tumor were recorded in a structured form. Based on the information collected, all patients were classified according to the risk of tumor recurrence according to the protocols developed and published by the ATA (American Thyroid Association).<sup>[19]</sup>

Tumor tissue was obtained through histological sections of paraffin blocks containing samples of carcinomas stored in the archives of the respective pathology services of the participating institutions. Four sequential 10µm-thick histological sections were performed for each case/block to make new slides, which were superimposed on their corresponding HE slides, with the tumor areas previously marked. The areas of tumor tissue from the new slides were manually dissected with sterile 6 disposable razors (Leica Biosystems, Germany) and transferred to microtubes (1.5ml), previously autoclaved and identified, and stored at room temperature until processing. In cases of multifocality, all tumor foci were selected, but only the most extensive focus was used in the study.

### *Pan-TRK immunohistochemistry (IHC) staining analysis*

IHC staining for expression of TRK A, B and C was performed with pan-TRK monoclonal antibody (mAb) clone EPR17341 (Abcam, Cambridge, MA). The antibody is reactive to a homologous region of TRK-A, -B, and -C near the C-terminus. IHC was performed using 4µm thick slides of sections of paraffinized tumor tissue from selected tumor blocks with representative material. EPR17341 was used at 6µg/ml, at 1:200 dilution. All assays were performed on a Dako Autostainer Link 48 automated staining platform (Agilent, Santa Clara, CA) using a heat-based antigen retrieval method and high pH buffer (EnVision Flex High pH, Agilent). Testicular tissue, submucosal colonic plexus ganglia, and cortical brain tissue were used as positive control tissues non-neoplastic lymphocytes, hepatocytes, colorectal epithelium, alveolar epithelium, and renal cortex were used as negative external controls. Available cases with *NTRK* rearrangements, as well as 10 consecutive tumors with no evidence of *NTRK* fusion, were stained as controls. The slides were evaluated and reviewed by 2 pathologists. Label positivity was defined as any unambiguous cytoplasmic and/or nuclear immunopositivity with clear contrast with the surrounding non-tumor tissue. The percentage of stained cells positivity and staining intensity were documented: (i) Pan-TRK negative: 0% stained cells; and (ii) Pan-TRK positive: 1% stained cells. All 79 IHC pan-TRK tested samples were then analyzed with a RNA-based NGS assay in order to confirm IHC pan-TRK result and elucidate fusion partner.

### *Targeted next generation sequencing (NGS) panel*

NGS was performed using the Illumina platform with the OncoPrint Focus Assay kit for RNA fusion analysis, capable of evaluating all classes of relevant targets, including point mutations, short insertions,

or deletions (indels), copy number variants (CNVs) and gene fusions, adapted for formalin-fixed and paraffin-embedded (FFPE) tissues. Three FFPE slides with a section of 5µm thickness were obtained per tumor sample, sufficient to provide about 10ng of DNA or RNA per reaction. This allowed analysis even on small-sized or inferior-quality tumor samples. Three 5µm FFPE cuts were used to extract DNA of somatic origin with the ReliaPrep™ FFPE RNA Miniprep System, Promega (Madison, WI, USA). Quality was verified with Qubit™ RNA HS Assay Kit assay (LifeTechnologies, USA). cDNA synthesis was performed with 7 Ampliseq™ cDNA Synthesis for Illumina® (USA), according to the manufacturer's recommendations. Genotyping of target genes *ABL1*, *ALK*, *AKT3*, *AXL*, *BRAF*, *EGFR*, *ERBB2*, *ERG*, *ETV1*, *ETV5*, *ETV4*, *FGFR1*, *FGFR2*, *FGFR3*, *NTRK1*, *NTRK2*, *NTRK3*, *PDGFRA*, *PPARG*, *RAF1*, *RET*, *ROS1* and *MET* were performed by NGS on the iSeq 100 Sequencing System platform, Illumina Inc (USA), mean sequencing depth 300x. Bioinformatics analyzes were conducted on the cloud-based Varstation™ platform with a standardized pipeline exclusively for technology and laboratory, considering the rules of the Association for Molecular Pathology (AMP).

### Statistical analysis

The following variables will be analyzed: age at the time of surgery, sex, tumor size, histological subtype, multifocality, extrathyroidal extension, presence of tumor capsule and capsular invasion, angiolymphatic invasion, perineural invasion, Hashimoto's thyroiditis (TH), lymph node metastases, cancer staging, recurrence risk stratification, positivity for *BRAF*<sup>V600E</sup> mutation. Data processing and data analysis will be performed with the assistance of the *Statistical Package for the Social Sciences* (SPSS), version 22, using nonparametric tests, according to the categorical variables of the research.

The normal distribution analysis will be evaluated using the *Shapiro-Wilk* test. Univariate analyzes ( $\chi^2$  test and Fisher's exact test) will be performed to assess the associations between clinical and pathological aspects and the presence of *NTRK* or *PTC* fusions. The implication between such associations will be based on the *p*-value  $\leq 0.05$ , determined with confidence intervals of 95%.

### Ethical aspects

This work was carried out in accordance with Resolution No. 466/2012 of the National Health Council (CNS). The project was submitted for ethical analysis in the electronic system of *Plataforma Brasil*, a national and unified database of research involving human beings, and was evaluated and approved by the Ethics and Research Committees in Human of the Health Sciences Institute, Federal University of Bahia (CEP/ICS), HAM, SCFMS and HULW, according to Opinion No. 4.319.796 (CAAE:34192920.6.0000.5662).

### Financial support

This research was carried out with financial resources from the pharmaceutical company Bayer under contract number BR135321023503P, managed by the intervener FAPEX, case number 23066.020493/2020-97.

## RESULTS

### Demographic and clinical characteristics

The median age at diagnosis observed in the sample studied was 18 years (range: 6-21 years). Thirty patients (38%) were under 18 years and forty-nine (62%) were aged between 18 and 21 years. Relation to gender, the vast majority were female (77%). Clinical-pathological characteristics of the patients are presented in Table 1.

### Pan-TRK IHC screening

All 79 tumors samples were submitted to pan-TRK IHC for *NTRK* fusion screening. Most tumor samples 64/79 (81%) were negative. Only 03 (3,8%) cases had positive pan-TRK expression and 12 of 79 (15%) cases had indeterminate staining (Table 2). Among positive cases: 1 case with 1% of staining cells and 2 samples with 10% staining cells. All positive samples demonstrated weak, focal, and nuclear staining (Figure 1).

### NGS-RNA fusion panel testing

NGS was performed on the 3 pan-TRK IHC positive cases and on 64 pan-TRK IHC negative samples, including 21 cases with MAPK pathway activation by known mutations (*BRAF p.V600E*, *KRAS/NRAS* hotspot). 39/74 (52.7%) had inconclusive results, 10/74 (13.5%) were positive for a rearrangement and 25/74 (33.8%) were classified as wild type.

Only 35 of 79 NGS-RNA sequencing tests were considered valid: 10 samples had positivity for gene fusions. Among the 10 positive cases for gene fusions: 04 were of the *NTRK* gene; 03 were of the *RET* gene; 02 were of *PAX8::PPARG* rearrangement; and 01 of the *STRN:ALK* gene fusion (Table 3).

*NTRK* gene fusion was detected in 04/35 valid tests (11,4%): (i) 03/35 (8,5%) *ETV6::NTRK3* and (ii) 01/35 (2,8%) *TPR::NTRK1*.

### IHC vs. NGS results

Pan-TRK IHC was negative in all 4 *NTRK* NGS-positive cases. Pan-TRK IHC and NGS concordance analysis: 25 of 79 *NTRK* NGS-negative control cases had concordant negative pan-TRK IHC results. Therefore, our rate of false positivity to pan-TRK IHC result was 3/25 (12%) (Table 4).

The overall results for pan-TRK IHC in our cohort of NGS-negative cases was: (i) sensitivity (0%), (ii) specificity (96%), (iii) positive predictive value (94.7%), and (iv) negative predictive value (91%) (Table 5).

**Table 1.** Demographics and Clinicopathological features of differentiated thyroid cancer in children, adolescents, and young adults (n=79).

Variables	Total	<18 years	>18 years
	79 (100.0%)	30 (37,9%)	49 (62,1%)
<b>Age (years), median</b>	18 (6-21)	17 (6-17)	19 (18-21)
<b>Sex, n(%)</b>			
Female	61 (77,2)	14	47
Male	18 (22,8)	8	10
<b>Histological subtype, n(%)</b>			
CPTC	66 (83,5)	14	52
FVPTC	9 (11,4)	2	7
FTC	3 (3,8)	1	2
DSPTC	1 (1,3)	1	0
<b>T staging, n(%)</b>			
T1a	9 (11,3)	3	6
T1b	22 (27,8)	4	18
T2	22 (27,8)	5	17
T3a	6 (7,5)	4	2
T3b	17 (21,5)	4	13
T4	3 (3,7)	0	3
<b>N staging, n(%)</b>			
N0	38 (48,1)	12	26
N1a	21 (26,5)	3	18
N1b	20 (25,3)	5	15
<b>M staging, n(%)</b>			
M1	8 (10,2)	1	7
<b>Tumor size(cm), median</b>	2.2 (0,3-7,5)	2 (0,5-7,5)	2,3 (0,3-6,8)
<b>Focality, n (%)</b>			
Multifocal	28 (35,5)	10	18
<b>Extrathyroidal invasion, n(%)</b>			
Positive	21 (26,5)	7	14
<b>Angiolymphatic invasion, n(%)</b>			
Positive	7 (8,8)	2	5
<b>ATA risk, n(%)</b>			
low risk	34 (43)	8	26
intermediate risk	16 (20,2)	3	13
high risk	29 (36,7)	8	21

Legend: ATA - American Thyroid Association; CPTC - classic papillary thyroid carcinoma; DSPTC- diffuse sclerosing papillary thyroid carcinoma; FTC - follicular thyroid carcinoma; FVPTC - follicular variant papillary thyroid carcinoma

**Table 2.** Pan-TRK Immunohistochemistry Screening (n=79).

Age (y)	n (%)	indeterminate	positive	negative
	79 (100%)	12/79 (15%)	3/79 (3,8%)	64/79 (81%)
<18	28	4	1	23
> 18	51	8	2	41

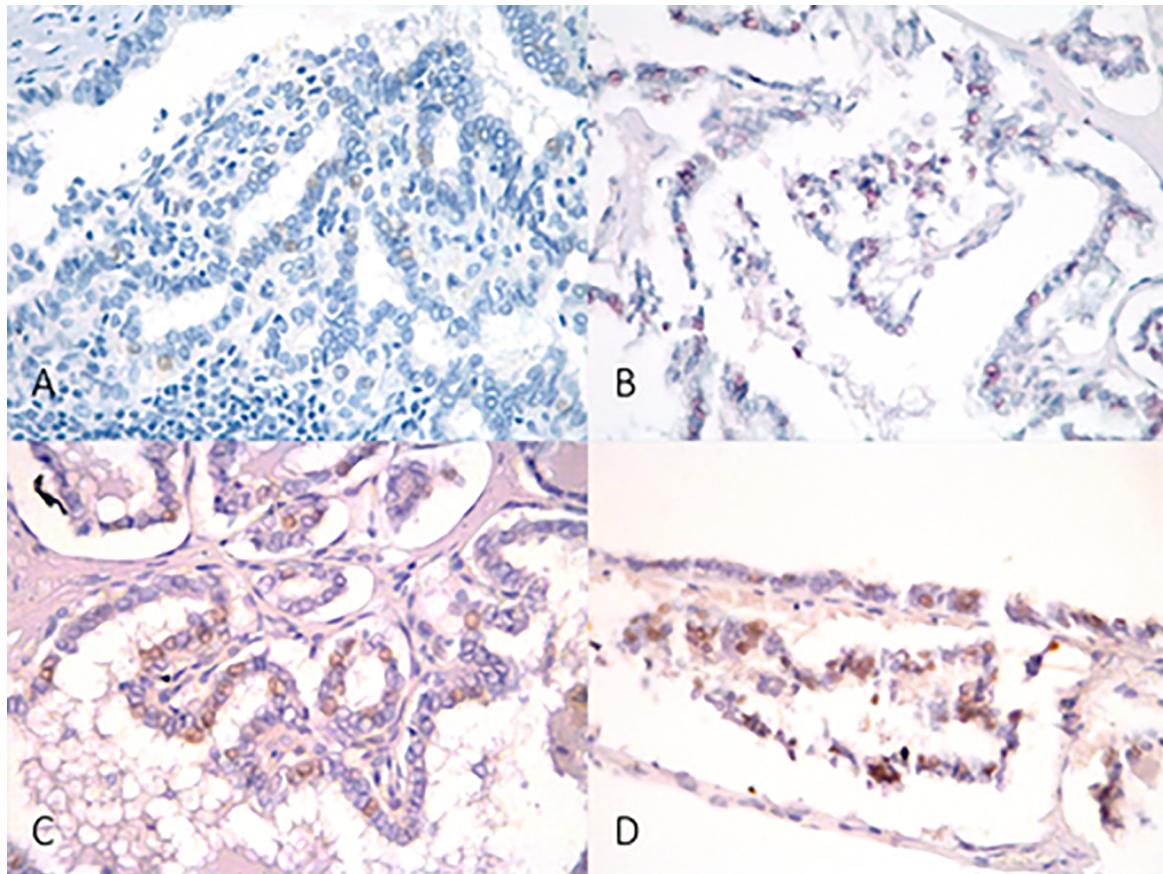


Figure 1. Pan-TRK immunohistochemistry. A. 200x, negative case; B. 200x, weak nuclear staining (1% cells); C and D. 200x, weak nuclear staining (10% cells).

Table 3. Gene fusions detected by Next Sequencing Generation (n=10).

Age	Sex	Histological Subtype	TNM staging	Fusion detected
20	F	CPTC	T2N1bM1	ETV6::NTRK3
15	F	CPTC	T1bN0M0	ETV6::NTRK3
13	F	CPTC	T1aN0M0	ETV6::NTRK3
12	F	CPTC	T3N1bM1	TPR::NTRK1
18	F	FTC	T2N0M0	PAX8::PPARG
17	F	CPTC	T2N0M0	PAX8::PPARG
14	F	CPTC	T2N1bM0	CCDC6::RET
11	F	CPTC	T1bN1bM0	TRIM24::RET
6	F	SDPTC	T3bN1bM0	NCOA4::RET
11	F	CPTC	T3bN0M0	STRN::ALK

Legend: ALK - Anaplastic Lymphoma Kinase; CCD6 - Coiled-Coil Domain Containing 6; CPTC - Classic variant of papillary thyroid carcinoma.; FTC - follicular thyroid carcinoma; SDPTC - Scleroing diffuse variant of papillary thyroid carcinoma; ETV6 - ETS variant transcription factor 6; NCOA4 - nuclear receptor coactivator 4; NTRK1 - neurotrophic receptor tyrosine kinase1; NTRK3 - neurotrophic receptor tyrosine kinase 3; PAX8 - Paired box gene 8 - peroxisome proliferator-activated receptor; PPARG - peroxisome proliferator activated receptor gamma; RET - Rearranged during transfection; TPR - translocated promoter region; TRIM24 - Tripartite motif-containing 24; STRN - striatin, calmodulin binding protein.

Table 4. Summary of Pan-TRK immunohistochemistry and NGS analysis (n=79).

	IHC positive	IHC negative
NGS positive	0	4
NGS negative	3	25
False positive	0	03 / 25 (12%)

**Table 5.** Calculation of sensitivity, specificity, positive and negative predictive values of Pan-TRK immunohistochemistry (vs. NGS results).

Sensitivity	0%
Specificity	96%
Positive predictive value	94,7%
Negative predictive value	91%

## DISCUSSION

The study aimed to determine the IHC sensitivity and specificity in DTC *NTRK* gene fusions in CAYA patients. This is the largest cohort of CAYA DTC cases stained with pan-Trk IHC, and it is the first to detail the sensitivity and specificity of pan-TRK IHC regarding the data obtained by targeted RNA-based NGS panel in DTC.

All *NTRK* positive tumors in our casuistry was papillary histological subtype, most frequent neoplasm found in pediatric population and the most related to *NTRK* fusions. Despite the majority (62%) were aged between 18 and 21 years, in our study, gene fusions were more detected in young patients (under 18-year-old), with a median of 14 years. This gene fusion greater occurrence in younger age is in accordance with the literature.<sup>[7-9]</sup>

Due to the multiple technologies available for the detection of *NTRK* fusions, one question is whether there is a better method for its evaluation, if we consider cost-effectiveness, given the high cost of performing these diagnostic tests, especially for NGS. Choosing the most appropriate method depends on the type of tumor being studied and the broader strategy for detecting other biomarkers of this neoplasm, as well as the clinical situation.<sup>[20,21]</sup> In our study, the cost of performing the IH and NGS tests for each tumor sample was R\$135.00 (one hundred and thirty-five reais) and R\$1,885.00 (one thousand eight hundred and eighty and five reais), respectively.

In the rare case of tumor types with a high frequency of specific and pathognomonic *NTRK* fusions, investigation with initial IHC is the cheapest, quickest, and most effective way of screening. This is a plausible screening option; however, a second method of investigation, such as RT-PCR, FISH or NGS, is recommended.<sup>[22-24]</sup>

Although there are several TRK antibodies available, the EPR 17341 clone has been the most widely used. This antibody detects the C-terminal region of TRK proteins A, B and C, therefore being considered pan-TRK. Overall, pan-TRK IHC is a sensitive technique for identifying *NTRK* fusions, with a reported overall sensitivity of 85 to 90% and specificity around 80%, but detection of TRKC is less sensitive.<sup>[25-28]</sup>

Ideally, positive cases should also be confirmed again by a second technique.<sup>[22]</sup> Albert et al. (2019)

<sup>[15]</sup> suggest a frequency-adapted approach in pediatric cases. In tumors with a high frequency of known *ETV6::NTRK3* fusions, the authors recommend starting with IHC/FISH (*ETV6* and/or *NTRK3*)/RT-PCR. However, advocating RT-PCR is challenging due to the plethora of fusion partners and how the fusions are assembled, makes generating probes for each possible fusion problematic. Therefore, negative results need to be reassessed by the NGS. In tumors considered with intermediate incidence, such as papillary carcinoma (PTC), screening for TRK fusion should be performed by IHC/NGS. High-grade gliomas should be tested with the NGS technique because glial tissues can physiologically express the TRK. Undifferentiated or spindle cell sarcoma should also be assessed with NGS.<sup>[10,20,29,30]</sup>

In this study, all 79 tumor samples from this series were submitted to IHC for TRK overexpression. Only 03 (3.7%) tumor samples were pan-TRK positive (3.7%): 1 sample with 1% positive cells and 2 samples with 10% positive cells. In our sample, samples were classified as pan-TRK positive when they had at least 1% of antibody-positive cells. The positive cellularity found was 1% in 1 case and 10% in other 2 cases. All samples positive for IHC showed a nuclear staining pattern with weak intensity in the reaction.

The cutoff point for determining whether a case is positive ranges from 1 to 10%, and there are several patterns of positivity for pan-TRK on IHC. While most *NTRK* fusions show cytoplasmic labeling, the pattern of labeling in thyroid tissue is variable and depends on the partner where the specific fusion is present and can be nuclear, cytoplasmic, and membranous, or demonstrate a combination of patterns.<sup>[9,11,22]</sup> In samples of paraffin-embedded thyroid tissue, Rudzinski et al. (2018)<sup>[31]</sup> found that the staining pattern differs between *NTRK1/2* fusions and *NTRK3* fusions. *NTRK1/2* positive cases show only cytoplasmic staining, whereas *NTRK3* fusions show nuclear +/- cytoplasmic staining.<sup>[31]</sup> In the studies by Solomon et al. (2019)<sup>[12]</sup> and Fazeli et al. (2020)<sup>[32,33]</sup>, *ETV6::NTRK3* typically demonstrate strong nuclear staining as a peculiar feature, with weak diffuse cytoplasmic staining, virtually diagnostic of this fusion.

However, in our study, none of them was *NTRK* fusion confirmed, with 1 tumor with negative results and 2 tumors with inconclusive results at NGS, configuring false-positive results. Thus, the frequency of *NTRK* fusions in the 3 tumor samples from patients with IHC-positive DTC was 0%.

Overall, the sensitivity in detect raised TRK expression by pan-TRK IHC is higher in *NTRK1* and *NTRK2* fusions, where sensitivity is usually 90%, than in detecting *NTRK3*. In fact, the *ETV6::NTRK3* fusion probably has the lowest detection rate of all fusion proteins, at around 50%.<sup>[12,16]</sup>

The specificity is very variable, depending on the type of tumor. While the antibody demonstrates 100% specificity in colon, lung, thyroid, pancreas

and biliary tract carcinomas, specificity decreases in breast and salivary gland carcinomas.<sup>[12]</sup> False positives generally occur in tumors with muscle and neural differentiation (sarcomas, gliomas, and neuroendocrine tumors); and false negatives, occur with cancers with *NTRK3* fusions.<sup>[32]</sup>

Using the same pan-TRK monoclonal antibody (mAb) clone EPR17341 (Abcam, Cambridge, MA), Hechtman et al reported high sensitivity (95.2%) and specificity (100%) of IHC in paraffin-embedded samples from several types of cancer (intestinal, brain, lung, secretory carcinoma, melanoma and sarcoma) (16). In agreement, Rudzinski et al. (2018)<sup>[31]</sup> obtained a sensitivity of 97% and a specificity of 98%, also using the Abcam clone EPR17341. In this study, the TRKA IHC antibody (EP1058Y), also from Abcam, had a sensitivity of 100% and a specificity of 63% (31). Gatalica et al. (2019)<sup>[8]</sup> investigated a large cohort including 4,136 cases, with 28 *NTRK* gene fusions, using the Abcam clone EPR17341, and found a lower sensitivity of 75% and a comparable specificity of 95.9%.

DNA-based NGS has about 70% sensitivity for *NTRK3* fusion whereas RNA-based NGS has virtually 100% sensitivity, but it is an expensive technology with a long lead time of about two weeks to perform. It is important to keep in mind that the absence of labeling does not exclude the possibility of this diagnosis, as there is a high rate of false-negative results in the detection of the *ETV6-NTRK3* fusion, for example.<sup>[16,25,27]</sup>

In the NGS gene fusion panel, the frequency of *NTRK* fusions was 11.4% (04 cases), with all cases being pan-TRK negative, suggesting a low sensitivity of IHC as a fusion tracking method *NTRK*. The overall results for pan-TRK IHC in our cohort of NGS-negative cases was: (i) sensitivity (0%), (ii) specificity (96%). However, it is possible that some cases considered false-positive by IHC may be false-negative results by the NGS fusion panel.

Although IHC is a technique capable of detecting increased levels of the TRK protein, and can be a very useful screening technology to reduce costs, in this study, given the presented data, IHC alone has not proven to be a definitive diagnostic methodology to detect *NTRK* gene fusions in pediatric and young adult DTC in the evaluated population. Even so, due to the great practicality of using IHC, this method should not be excluded as a method of screening *NTRK* fusions in clinical practice, however it is suggested that the investigation of the *NTRK* fusion by NGS should be, whenever possible, the preferred technique in tracking this fusion in DTC of children, adolescents and young adults.

### Limitations of the study

It's possible that the prevalence of *NTRK* fusions in this present casuistry was underestimated, considering the large number of inconclusive results in NGS. Out of the 79 included samples,

only 35 were evaluated (less than half of the initial sample size).

The reasons for this were little availability of tumor sample or degraded tumor material: low-quality, inadequate conservation, small sample, degraded RNA, fixing time and paraffin block age. Additionally, methodological fragility as non-probability sampling may have contributed for *NTRK* fusion underestimation in our study. Despite that, the obtained sample size can be considered sufficient for the final conclusions considering the ultimate pediatric cohort series in the literature.<sup>[7,9-11]</sup>

## CONCLUSION

Pan-TRK IHC was not a tissue-efficient screen for *NTRK* fusions in DTC from CAYA patients. In our study, there was absolute disagreement between the IHC and NGS tests for tracking *NTRK* fusion in DTC. All *NTRK* fusions were identified only by the NGS method, with a negative result prior to IHC and in no tumor sample positive by IHC there was confirmation of the fusion by NGS. Therefore, the IHC screening test was not able to identify tumors carrying the *NTRK* fusion in the tumor samples of our study, suggesting a low sensitivity of the IHC as a *NTRK* fusion screening method.

### Key points:

- . The frequency of *NTRK* fusions was 11.4% in this study.
- . There was disagreement between the IHC and NGS tests for tracking *NTRK* fusion.
- . NGS should be the preferred technique in tracking *NTRK* fusion in DTC from CAYA patients.

### Ethical approval

This work was carried out in accordance with Resolution No. 466/2012 of the *Conselho Nacional de Saúde* (CNS). The project underwent ethical review in the electronic system of Plataforma Brasil, a unified national database for research involving human subjects. It was assessed and approved by the Ethics Committees for Research at the Institute of Health Sciences of the Federal University of Bahia (CEP/ICS), *Liga Baiana Contra o Câncer* (CEP/LBCC/HAM), and *Gerência de Ensino e Pesquisa* (GEP/HULW), as per Substantiated Opinion No. 5,470,375.

### Declaration of interest

The authors declare that there is no conflict of interest that could be perceived as prejudicing the impartiality of the research reported.

### Funding

This work was financially supported by Bayer, under contract number BR135321023503P, administered by the intermediary Foundation for Research and Extension Support Funda (FAPEX), project number 200038.

<b>ABBREVIATIONS</b>	<b>FULL NAMES</b>
AJCC	American Joint Committee on Cancer
ANVISA	National Agency of Sanitary Monitoring
ATA	American Thyroid Association
BRAF	V-raf murine sarcoma viral oncogene
CEP	Ethics and Research Committees in Human
CNS	National Health Council
CPTC	Classic variant of papillary thyroid carcinoma
DNA	Deoxyribonucleic acid
DTC	Differentiated Thyroid Cancer
FDA	U.S Food and Drug Administration
FFPE	Formalin-fixed paraffin-embedded
FTC	Follicular Thyroid Carcinoma
HAM	Aristides Maltez Hospital
HE	Hematoxilina-eosina
HULW	Lauro Wanderley University Hospital
ICD	International Statistical Classification of Diseases and Related Health Problems
ICS	Institute of Health Sciences
FISH	Fluorescence in situ hybridization
IHC	Immunohistochemistry
NGS	Next generation sequence
NTRK	Neurotrophic receptor tyrosine kinase
RT-PCR	Reverse transcription polymerase chain reaction
PTC	Papillary thyroid carcinoma
RNA	Ribonucleic acid
SCMFS	Santa Casa de Misericórdia de Feira de Santana
SDPTC	Sclerosing diffuse variant of papillary thyroid carcinoma
TNM	Classification of malignant tumors
TRK	Tropomyosin receptor kinase
UFBA	Federal University of Bahia
WT	Wild type

## AUTHORS' CONTRIBUTIONS

ACOTT	Collection and assembly of data, Manuscript writing
GJRM	Collection and assembly of data, Data analysis and interpretation, Manuscript writing
JLVA	Collection and assembly of data, Data analysis and interpretation, Manuscript writing
RRCM	Collection and assembly of data, Manuscript writing
TLCO	Collection and assembly of data, Data analysis and interpretation, Manuscript writing
FELB	Data analysis and interpretation, Manuscript writing
ARP	Provision of study materials or patient, Manuscript writing
FH	Data analysis and interpretation, Manuscript writing
GCL	Data analysis and interpretation, Manuscript writing
LFBR	Provision of study materials or patient, Manuscript writing
BSL	Provision of study materials or patient, Manuscript writing
HER	Conception and design, Data analysis and interpretation, Final approval of manuscript, Manuscript writing

## REFERENCES

- Tamam M, Uyanik E, Edís N, Mulazimoglu M, Ozpacaci T. Differentiated thyroid carcinoma in children: clinical characteristics and long-term follow-up. *World J Nucl Med.* 2020;19(1):28-35.
- Prasad PK, Mahajan P, Hawkins DS, Mostoufi-Moab S, Venkatramani R. Management of pediatric differentiated thyroid cancer: an overview for the pediatric oncologist. *Pediatr Blood Cancer.* 2020;67(6):e28141.
- Russo M, Malandrino P, Moleti M, Vermiglio F, D'Angelo A, La Rosa G, et al. Differentiated thyroid cancer in children: Heterogeneity of predictive risk factors. *Pediatr Blood Cancer.* 2018;65(9):e27226.
- Vriens MR, Moses W, Weng J, Peng M, Griffin A, Bleyer A, et al. Clinical and molecular features of papillary thyroid cancer in adolescents and young adults. *Cancer.* 2011;117(2):259-67.
- Beimfohr C, Klugbauer S, Demidchik EP, Lengfelder E, Rabes HM. NTRK1 re-arrangement in papillary thyroid carcinomas of children after the Chernobyl reactor accident. *Int J Cancer.* 1999;80(6):842-7.
- Nakagawara A. TRK receptor tyrosine kinases: a bridge between cancer and neural development. *Cancer Lett.* 2001;169:107-14.

7. Sassolas G, Hafdi-Nejjari Z, Ferraro A, Decaussin-Petrucci M, Rousset B, Borson-Chazot F, et al. Oncogenic alterations in papillary thyroid cancers of young 77 patients. *Thyroid*. 2012;22(1):17-26.
8. Gatalica Z, Xiu J, Swensen J, Vranic S. Molecular characterization of cancers with *NTRK* gene fusions. *Mod Pathol*. 2019;32(1):147-53.
9. Prasad ML, Vyas M, Horne MJ, Virk RK, Morotti R, Liu Z, et al. *NTRK* fusion oncogenes in pediatric papillary thyroid carcinoma in northeast United States. *Cancer*. 2016;122(7):1097-110.
10. Pekova B, Dvorakova S, Sykorova V, Vacinova G, Vaclavikova E, Moravcova J, et al. Somatic genetic alterations in a large cohort of pediatric thyroid nodules. *Endocr Connect*. 2019;8(6):796-805.
11. Pekova B, Sykorova V, Mastnikova K, Vaclavikova E, Moravcova J, Vlcek P, et al. *NTRK* fusion genes in thyroid carcinomas: clinicopathological characteristics and their impacts on prognosis. *Cancers*. 2021;13:1932.
12. Solomon JP, Benayed R, Hechtman JF, Ladanyi M. Identifying patients with *NTRK* fusion cancer. *Ann Oncol*. 2019;30(Suppl 8):viii16-viii22.
13. Cui C, Shu W, Li P. Fluorescence in situ hybridization: cell-based genetic diagnostic and research applications. *Front Cell Dev Biol*. 2016;4:89.
14. Lee YC, Chen JY, Huang CJ, Chen HS, Yang AH, Hang JF. Detection of *NTRK1/3* rearrangements in papillary thyroid carcinoma using immunohistochemistry, fluorescent in situ hybridization, and next-generation sequencing. *Endocrine Pathol*. 2020 Dec;31(4):348-58.
15. Albert CM, Davis JL, Federman N, Casanova M, Laetsch TW. *TRK* fusion cancers in children: a clinical review and recommendations for screening. *J Clin Oncol*. 2019;37(6):513-24.
16. Hechtman JF, Benayed R, Hyman DM, Drilon A, Zehir A, Frosina D, et al. Pan-*TRK* Immunohistochemistry. Is an efficient and reliable screen for the detection of *NTRK* Fusions. *Am J Surg Pathol*. 2017;41(11):1547-51.
17. Amin MB, Edge SB, Greene FL, Byrd DR, Brookland RK, Washington MK, et al. *AJCC cancer staging manual* [Internet]. US: Springer; 2017; [access in Y2023 April 10]. Available from: <http://www.springer.com/la/book/9783319406176>
18. Lloyd RV, Osamura RY, Klöppel G, Rosai J. *Cancer IA for R on 2017. WHO Classification of Tumours of Endocrine Organs*. 4<sup>th</sup> ed. France: Lyon; 2017.
19. Haugen BR, Alexander EK, Bible KC, Doherty GM, Mandel SJ, Nikiforov YE, et al. American thyroid association management guidelines for adult patients with thyroid nodules and differentiated thyroid cancer: The American Thyroid association guidelines task force on thyroid nodules and differentiated thyroid cancer. *Thyroid*. 2016;26(1):1-133.
20. Marchiò C, Scaltriti M, Ladanyi M, Iafrate AJ, Bibeau F, Diel I, et al. ESMO recommendations on the standard methods to detect *NTRK* fusions in daily practice and clinical research. *Ann Oncol*. 2019;30(9):1417-27.
21. Jennings LJ, Arcila ME, Corless C, Kamel-Reid S, Lubin JM, Pfeifer J, et al. Guidelines for validation of next-generation sequencing based oncology panels: a joint consensus recommendation of the Association for Molecular Pathology and College of American Pathologists. *J Mol Diagn*. 2017;19(3):341-65.
22. Märkl B, Hirschbühl K, Dhillon C. *NTRK*-Fusions - a new kid on the block. *Pathol Res Pract*. 2019;215(10):152572.
23. Lassen U. How I treat *NTRK* gene fusion-positive cancers. *ESMO Open*. 2019;4(Suppl 2):e000612.
24. Abel HJ, Duncavage EJ. Detection of structural DNA variation from next generation sequencing data: a review of informatic approaches. *Cancer Genet*. 2013;206(12):432-40.
25. Brzeziańska E, Pastuszek-Lewandoska D, Lewiński A. Rearrangements of *NTRK1* oncogene in papillary thyroid carcinoma. *Neuro Endocrinology Letters*. 2007;28(3):221-9.
26. Grego A, Miranda C, Pierotti MA. Rearrangements of *NTRK1* gene in papillary thyroid carcinoma. *Mol Cell Endocrinol*. 2010;321(1):44-9.
27. Sabour L, Sabour M, Ghorbian S. Clinical applications of next-generation sequencing in cancer diagnosis. *Pathol Oncol Res*. 2017;23(2):225-34.
28. Ronsley R, Rassekh SR, Shen Y, Lee AF, Jantzen C, Halparin J, et al. Application of genomics to identify therapeutic targets in recurrent pediatric papillary thyroid carcinoma. *Cold Spring Harb Mol Case Stud*. 2018;4(2):a002568.
29. Hsiao SJ, Zehir A, Sireci AN, Aisner DL. Detection of tumor *NTRK* gene fusions to identify patients who may benefit from tyrosine kinase (*TRK*) inhibitor therapy. *J Mol Diagn*. 2019;21(4):553-71.
30. Kummar S, Lassen UN. *TRK* Inhibition: a new tumor-agnostic treatment strategy. *Target Oncol*. 2018;13(5):545-56.
31. Rudzinski ER, Lockwood CM, Stohr BA, Vargas SO, Sheridan R, Black JO, et al. Pan-*TRK* Immunohistochemistry identifies *NTRK* rearrangements in pediatric mesenchymal tumors. *Am J Surg Pathol*. 2018;42(7):927-35.
32. Solomon JP, Linkov I, Rosado A, Mullaney K, Rosen EY, Frosina D, et al. *NTRK* fusion detection across multiple assays and 33,997 cases: diagnostic implications and pitfalls. *Mod Pathol*. 2020 Jan;33(1):38-46.
33. Fazeli S, Dadu R, Waguespack SG, Sherman SI, Busaidy NL, Hu MI, et al. MON-491 *TRK*-fusion thyroid cancer: a clinical overview in a large population at a single cancer center. *J Endocr Soc*. 2020;4(Suppl 1):491.