







Iatrogenic tension pneumocephalus complication of osteoradionecrosis in the treatment of nasopharyngeal carcinoma. A case report and critical literature review

Complicação iatrogênica do pneumoencéfalo hipertensivo da osteoradionecrose no tratamento do carcinoma nasofaríngeo. Um relato de caso e revisão crítica da literatura

Isidro Miguel Martín Pérez^{1,2}, Sebastián Eustaquio Martín Pérez^{1,2,3,4}, Adolfo Vérguez Muñoz⁵, Nart Keituqwa Yáñez⁵, María Carmen Dolado Correa⁵, Carolina Rodríguez González^{1,6}, Fidel Rodríguez Hernández¹

ABSTRACT

Nasopharyngeal carcinoma typically originates in the fossa of Rosenmüller within the mucosal epithelium directly underlying the lymphatic tissue, and commonly presents clinically with symptoms such as headache, dizziness, and rhinorrhea. In this case study, we describe a 61-year-old man diagnosed with nasopharyngeal carcinoma who underwent radiation therapy with a total dose of 50 Gy administered at a rate of 2 Gy per day, along with chemotherapy consisting of cisplatin at a dose of 100 mg/m². Surgical intervention was deemed unsuitable due to the size of the tumors. Five months later, the patient developed a tension pneumocephalus due to a clival fistula “corking effect,” which resulted in the infiltration of air bubbles into the brain and culminating in his death 2 weeks after admission to the intensive care unit.

Keywords: Nasopharyngeal carcinoma; Radiotherapy; Pneumocephalus; Osteoradionecrosis.

1. Universidad de La Laguna, Departamento de Farmacología y Medicina Física - Santa Cruz de Tenerife - Santa Cruz de Tenerife - Spain.
2. Universidad de La Laguna, Escuela de Doctorado y Estudios de Posgrado - Santa Cruz de Tenerife - Santa Cruz de Tenerife - Spain.
3. Universidad Europea de Canarias, Musculoskeletal Pain and Motor Control Research Group - Santa Cruz de Tenerife - Santa Cruz de Tenerife - Spain.
4. Universidad Europea de Madrid, Musculoskeletal Pain and Motor Control Research Group - Villaviciosa de Odón - Comunidad de Madrid - Spain.
5. Hospital Universitario de Canarias, Radiation Oncology Service - Santa Cruz de Tenerife - Santa Cruz de Tenerife - Spain.
6. Hospital Universitario de Canarias, Hospital Universitario de Canarias - Santa Cruz de Tenerife - Santa Cruz de Tenerife - Spain.

Financial support: none to declare.

Conflicts of interest: The authors declare no conflict of interest relevant to this manuscript.

Correspondence author: Fidel Rodríguez Hernández.

E-mail: frguezh@ull.edu.es

Received on: October 17, 2023 | **Accepted on:** March 21, 2024 | **Published on:** May 16, 2024

DOI: <https://doi.org/10.5935/2526-8732.20240449>



This is an open-access article distributed under the terms of the Creative Commons Attribution License.

RESUMO

O carcinoma nasofaríngeo normalmente se origina na fossa de Rosenmüller, dentro do epitélio da mucosa diretamente subjacente ao tecido linfático, e comumente se apresenta clinicamente com sintomas como dor de cabeça, tontura e rinorreia. Neste estudo de caso, descrevemos um homem de 61 anos com diagnóstico de carcinoma de nasofaringe que foi submetido à radioterapia com dose total de 50 Gy administrada a uma taxa de 2 Gy por dia, juntamente com quimioterapia composta por cisplatina na dose de 100 mg/m². A intervenção cirúrgica foi considerada inadequada devido ao tamanho dos tumores. Cinco meses depois, o paciente desenvolveu pneumoencéfalo hipertensivo devido a um “efeito rolha” de fístula clival, que resultou na infiltração de bolhas de ar no cérebro e culminou em sua morte 2 semanas após a admissão na unidade de terapia intensiva.

Descritores: Carcinoma nasofaríngeo; Radioterapia; Pneumoencéfalo; Osteoradionecrose.

INTRODUCTION

Nasopharyngeal carcinoma (NPC) is an uncommon malignant tumor that originates from the epithelial cells lining the surface of the nasopharynx. The prevalence of NPC is typically less than 1 per 100,000 person-years, accounting for approximately 0.25% of all cancers diagnosed worldwide.^[1] The incidence of NPC is moderately high in Asian, North American, and Mediterranean populations.^[2]

Patients often manifest nonspecific symptoms in the early stages of NPC, including headache, dizziness, and unexplained weight loss, which can further delay diagnosis and appropriate intervention.^[3] In addition, tumor invasion into nearby cranial structures can lead to severe complications such as hydrocephalus, cerebrospinal fluid fistula syndrome (CFS), and tension pneumocephalus (TPN).

The treatment of cancer requires a comprehensive strategy that includes radiotherapy (RDT), chemotherapy (CHT), and sometimes surgery. The choice of treatment depends on factors such as the size of the tumor, whether it has spread, and the patient's overall health.

We present the case of a 61-year-old man who was diagnosed with locally advanced nasopharyngeal squamous cell carcinoma.^[1,2] During the treatment of NPC, the patient experienced a concurrent iatrogenic injury related to osteoradionecrosis. Because of the uncommon nature of NPC, we conducted an extensive literature review to help identify this pathology and more effectively manage similar cases. The study methodology involved an exhaustive search of major databases (MEDLINE [PubMed], Cochrane Database, CINAHL, Scopus, and Elsevier) from August 3, 2023, to September 1, 2023. Various search terms, including “nasopharyngeal carcinoma,” “radiotherapy,” “pneumocephalus,” and “osteoradionecrosis,” were carefully combined by using the Boolean operators AND, OR, and NOT.

CASE REPORT

A 61-year-old man, a heavy smoker, presents with symptoms of headache, dizziness, and significant weight loss over a 4-month period. Upon worsening of his symptoms, he sought medical attention in the emergency room where a CT scan of the skull revealed a malignant process in the nasopharynx characterized by infiltration and destruction of surrounding structures including the clivus, second cervical vertebra, and involving the right sphenoid sinus with associated lysis of its posterior wall. In addition, partial obstruction of the ipsilateral intrapetrous canal was noted. Figure 1 illustrates frontal and sagittal views from a CT scan, highlighting the tumor-induced destruction of the clivus and associated damage to the bony barrier.

Although neurological examination yielded asymptomatic results, laboratory tests revealed hyponatremia due to pituitary involvement secondary to the syndrome of inappropriate antidiuretic hormone secretion (SIADH). Furthermore, a biopsy subsequently confirmed luminal epidermoid carcinoma with a staging of cT4 cN0 M0, which indicates local tumor spread with no regional lymph node involvement or distant metastases.

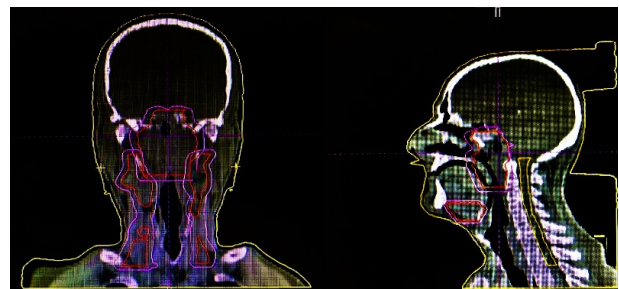


Figure 1. Illustrates frontal and sagittal views from a CT scan, highlighting the tumor-induced destruction of the clivus and the accompanying damage to the bony barrier.

Upon diagnosis, the treatment consisted of RDT with 70 Gy applied by LINAC Siemens ONCOR® plan with multilayer collimator and a 3DRT plan (PCRT system) with the aim of targeting the localized tumor spread while minimizing damage to surrounding healthy tissues. The planning target volume (PTV) encompassed the nasopharyngeal region with both ganglion chains receiving a total dose of 50 Gy delivered at a rate of 2 Gy per day. Figure 2 shows the 3D CT plan showing the destruction of the clivus and the bone barrier caused by the neoplasm. Concurrent chemotherapy (CHT) with cisplatin was administered at a dose of 100 mg/m². However, because of the severity of hyponatremia after the first cycle, CHT was discontinued. Figure 3 exhibits non-contrast computed tomography and magnetic resonance imaging, offering visual confirmation of the existence of air bubbles within the brain.

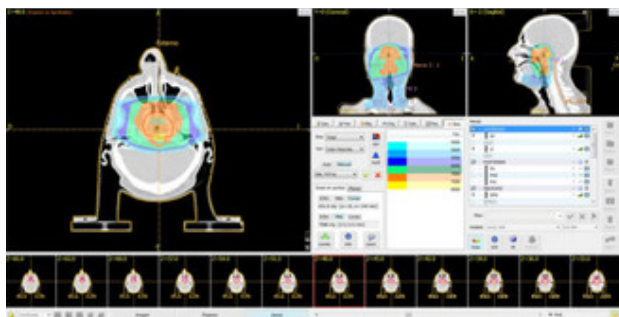


Figure 2. Depicts the CT 3D planning, revealing the destruction of the clivus and the bone barrier caused by the neoplasm.

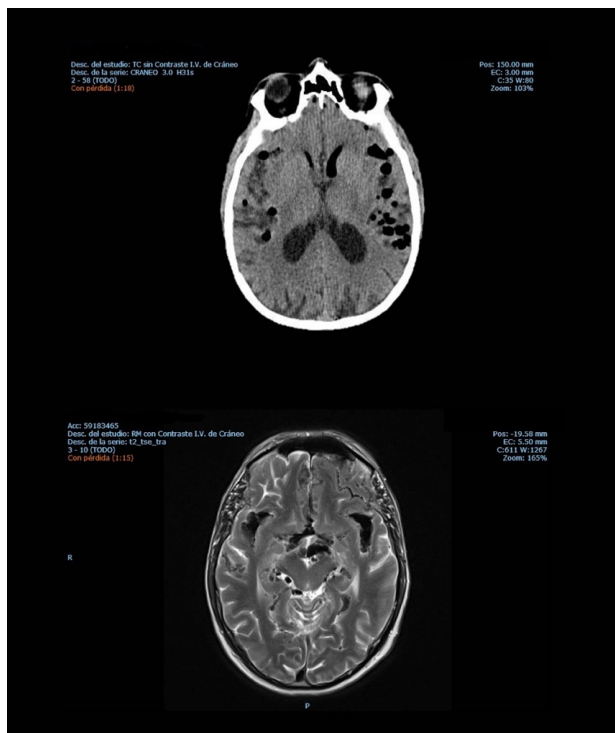


Figure 3. Displays non-contrast computed tomography and magnetic resonance imaging, providing visual evidence of the presence of air bubbles within the brain.

During the first weeks of treatment, the patient experienced fatigue, dysphagia, and mild xerostomia with negligible eyelid drooping. After 6 weeks of treatment, CT scans showed an incomplete regression of the NPC due to the presence of significant residual tumor. He was hospitalized for 4 months with headache, fluctuating level of consciousness, spatial disorientation, drowsiness, left-sided paralysis of the sixth and twelfth cranial nerves, and rhinorrhea suggestive of respiratory infection.

Two weeks later, with no noticeable clinical changes, CT and MRI scans showed a significant improvement in the previously reported tumor remnants; however, scattered bubbles were detected throughout the brain mass. After the tumor disappeared, residual effects persisted as the tumor could still act as a plug obstructing the outflow of cerebrospinal fluid. Subsequently, a fistula formed requiring drainage to the nasopharyngeal area, creating the potential for air bubbles to enter the central nervous system and leading to tension pneumocephalus (TPN).

Direct rhinoscopy revealed persistent cerebrospinal fluid drainage from the fistula, which was identified as the cause of the rhinorrhea. Neurosurgeons and otolaryngologists were consulted regarding a trans-maxillary approach and placement of dural fragments or other materials, but this recommendation was quickly rejected due to insufficient compliance of the irradiated area. The patient died within 2 weeks.

DISCUSSION

Several environmental factors, including exposure to chemical carcinogens, alcohol consumption, dietary habits, and nitrosamines, as well as genetic predisposition, have been associated with NPC.^[4,5] In addition, infectious etiologies, particularly Epstein-Barr virus (EBV) involvement, are often implicated, as evidenced by the presence of viral copies, free viral DNA, or the CYFRA21 marker.^[4,5] While the monitoring of treatment response and detection of relapses typically involves assessment of immunoglobulin levels against EBV viral capsid or early antigen and nuclear antigen, endoscopy with targeted biopsy remains the primary diagnostic procedure.^[6]

NPC typically originates in the fossa of Rosenmüller, located superior and posterior to the torus tubarius, where the mucosal epithelium directly overlies the underlying lymphoid tissue.^[7,8] Clinical manifestations of NPC encompass a spectrum of symptoms, such as epistaxis, nasal obstruction, unilateral hearing loss, otalgia, otorrhea, headache, cranial nerve involvement, and vascular injury.^[9,10] NPCs are endemic in Southeast Asia and among Eskimo populations in Alaska and Greenland, with an annual incidence of 30 cases per 100,000 people, attributed to childhood consumption of salted fish and exposure to nitrosamines^[11] and

polycyclic hydrocarbons in salt-preserved foods.^[12,13] The incidence of NPC is estimated to be 1 case per 100,000 in the United States, Europe, and Spain, with an uneven distribution in different regions of the world.^[14,15] Intermediate-risk areas such as the Maghreb and Central Africa demonstrate an incidence of 5 and 7 cases per 100,000 individuals, respectively.^[16] NPC has a slight male predominance, with a male-to-female ratio of 3:1, and is known for its clinically atypical behavior.^[17] Depending on the location of the NPC, its locoregional extent, and its high metastatic potential, the clinical presentation varies.

In our case, pneumocephalus (PN) emerged as a rare complication, adding a layer of complexity to the clinical presentation of NPC. PN is a neurological emergency characterized by the accumulation of compressed air within the cranial cavity, often associated with accidental decompression, surgical trauma, and impacts involving the face and skull.^[18,19] PN is commonly associated with various events such as post-craniotomy or surgical interventions, barotrauma, ear infections, exposure to nitrous oxide or induced nitrogen anesthesia, and diagnostic procedures (e.g., lumbar puncture).^[20,21] While the location of PN may vary, it typically manifests with the presence of air in the apical space and encompasses intraventricular, intraparenchymal, subarachnoid, subdural, and epidural areas.

Despite significant advances in understanding the pathophysiology of PN, the documentation remains limited, with only six confirmed cases of PN and only four cases of TPN properly documented regarding patients with NPC.^[19-21] Several mechanisms have been identified to explain the occurrence of TPN, with barotrauma being one of the most studied. In this regard, Kankane et al. (2016) reported the case of a 50-year-old man who developed TPN due to high air pressure (hyperbaric) following epidural steroid injections for the treatment of cervical radiculopathy.^[20]

Furthermore, in our case study, we note that osteoradionecrosis (ORN) may have played a significant role in the development of the clivus fistula. Although uncommon, ORN must be considered as a potential contributing factor to TPN associated with NPC. Extensive literature supports the notion of delayed, spontaneous onset of TPN following radiotherapy (RDT). Insights provided by Wu and Lee (1999) and Sumitsawan et al. (2009) shed light on the occurrence of TPN in patients who underwent RDT to the skull base.^[6,22]

In contrast, the mechanism underlying these changes in blood vessels after ionizing radiation exposure is not yet fully understood, leading to nutrient deprivation in the bone marrow and hindering osteoblast production.^[23] Consequently, diminished osteoclastic activity results in impaired resorption of bone tissue, culminating in necrosis. Regarding this phenomenon, another author noted

that ORN correlates with factors such as radiation dose, reirradiation, and tumor size^[6]. In addition, severe erosion of the internal carotid artery due to hemorrhage and generalized weakness emerges as an independent factor contributing to necrosis.^[24]

In addition, the delayed onset of TPN, observed in our case approximately 5 months after RDT treatment, contrasts with the findings of other studies in which TPN typically manifests approximately 12 months after treatment.^[24-26] While the exact cause of this early presentation remains uncertain, it seems reasonable to infer that the onset of TPN cannot be solely attributed to the presence of the tumor, but rather to ORN. This conclusion is supported by the evidence of almost complete remission of the tumor mass and the onset of rhinorrhea symptoms due to the skull base fistula.

Regardless of the etiology, we are confident that at least two mechanisms can contribute to the formation of TPN. One mechanism, known as "inverted ink bottle," involves a continuous cerebrospinal fluid (CSF) leak resulting in fluid loss and subsequent intracranial depression.^[9,27] This increase in intracranial pressure poses a potentially fatal risk if not treated promptly with trepanation or if the fluid crosses the fistula autonomously.^[28] The second mechanism, known as the "ball valve," occurs when air enters the cavity due to extracranial pressure exceeding intracranial pressure, typically during actions such as sneezing, coughing, straining, or the Valsalva maneuver.^[29]

In our patient, the constellation of symptoms (headache, fluctuating level of consciousness, spatial disorientation, and drowsiness) appears to be pathophysiological linked to decreased intracranial pressure^[30] resulting from CSF drainage through fistulas. We did not directly measure CSF pressure because we hypothesized that a dual mechanism was at play. However, we note that transient pressure normalization (TPN) may occur initially, followed by a spontaneous reduction in fistula tone due to fluid loss, leading to hypotension and eventual fistula closure.^[42] Some authors have suggested that hypotension might coincide with impaired cognitive function and, in severe cases, coma.^[31-33] Of note is the finding that 76% of our patients reported worsening headache in the upright position and worsening of neurological symptoms in various body positions, including the upright, horizontal, and Trendelenburg positions.^[34-36]

Alternatively, another theory states that intracranial negative pressure (INP) results from excessive CSF loss due to iatrogenic physiological drainage.^[37] In our case, standard treatment of RDT with concurrent CHT was performed as previously described to ensure eventual tumor regression, resulting in an acceptable survival and quality of life for the patient. The clinical course was variable, highlighting the unpredictable nature of these tumors, with the initial development of rhinorrhea

fistulas, followed by TPN, leading to severe neurological deterioration, coma, and ultimately the patient's death.

While CT serves as the reference test, in our case report, its combination with MRI represents the optimal approach for diagnosing and monitoring both NPC and complications associated with TPN. Initially, the onset of rhinorrhea was mistakenly attributed to a cold, while the CT scan provided limited information. Abdel and King established CT as the primary modality for staging NPC, providing details on the extent tumor of invasion (T and N), albeit with limitations in imaging intracranial, orbital, and nerve sheath extensions.^[38] CT imaging allows for a more accurate assessment of osteolytic lesions, which are commonly attributed to trauma.^[39] In patients with trauma-related TPN, the Mount Fuji sign refers to compression and separation of the two frontal lobes, manifested by widening of the interhemispheric fissure.^[40-42]

Moreover, MRI addresses these limitations, with studies demonstrating its superior efficacy in detecting early-stage NPC due to its accuracy in detecting cervical and retropharyngeal lymph nodes and facilitating patient follow-up due to its ability to differentiate between soft tissue and bone changes.^[11] This feature makes MRI indispensable for the follow-up management of patients with recurrent disease.

While previous findings may have provided validation for our treatment decisions, it is imperative to remain cognizant of the critical role that RDT dose plays in preventing ORN-associated complications. This case report serves as a poignant reminder of the delicate balance required in administering RDT, particularly in the context of NPC. By carefully considering the optimal dosage levels and adhering to established protocols, healthcare professionals can reduce the risk of adverse effects such as osteoradionecrosis while ensuring effective tumor control.

CONCLUSIONS

In summary, RDT proves to be effective in treating NPC, even when the tumor invades the skull base and may cause complications (e.g., ORN). This suggests that the therapeutic approach used has yielded promising results. However, it is unfortunate that the patient in this clinical case died. This underscores the importance of close monitoring and comprehensive management of complications such as tension pneumocephalus to increase the survival of patients in similar circumstances.

ETHICAL STANDARDS

Because of the nature of this report, formal approval by an ethics committee was not required. Informed consent was obtained from all patients for inclusion in the study.

AUTHORS' CONTRIBUTIONS

IMMP	Conception and design, Data analysis and interpretation, Final approval of manuscript, Manuscript writing.
SEMP	Conception and design, Data analysis and interpretation, Final approval of manuscript, Manuscript writing
AVM	Collection and assembly of data, Conception and design, Final approval of manuscript, Provision of study materials or patient
NKY	Final approval of manuscript
MCDC	Collection and assembly of data, Conception and design, Final approval of manuscript
CRG	Manuscript writing
FRH	Conception and design, Final approval of manuscript, Manuscript writing

ACKNOWLEDGEMENTS

The authors thank the University of La Laguna for funding to develop this research.

REFERENCES

1. Chua MLK, Wee JTS, Hui EP, Chan ATC. Nasopharyngeal carcinoma. *Lancet*. 2016 Mar;387(10022):1012-24.
2. Stiller CA. International variations in the incidence of childhood carcinomas. *Cancer Epidemiol Biomarkers Prev*. 1994 Jun;3(4):305-10.
3. Zeng L, Tian YM, Huang Y, Sun XM, Wang FH, Deng XW, et al. Retrospective analysis of 234 nasopharyngeal carcinoma patients with distant metastasis at initial diagnosis: therapeutic approaches and prognostic factors. *PLoS One*. 2014 Sep;9(9):e108070.
4. Hatakeyama H, Fujima N, Tsuchiya K, Mizoguchi K, Mizumachi T, Sakashita T, Kano S, Homma A, Fukuda S. Osteoradionecrosis of the hyoid bone after intra-arterial chemoradiotherapy for oropharyngeal cancer: MR imaging findings. *Cancer Imaging*. 2017 Jul 27;17(1):22. doi: 10.1186/s40644-017-0123-7. PMID: 28750685; PMCID: PMC5531026.
5. Kim YI, Jeun SS. Successful prevention of cerebrospinal fluid leakage after endoscopic endonasal transsphenoidal surgery. *J Neurol Surg B Skull Base*. 2013;74:A048.
6. Wu CT, Lee ST. Delayed spontaneous tension pneumocephalus caused by radionecrosis of the skull base. *Br J Neurosurg*. 1999 Apr;13(2):214-6.
7. Le C, Strong EB, Luu Q. Management of Anterior Skull Base Cerebrospinal Fluid Leaks. *J Neurol Surg B Skull Base*. 2016 Oct;77(5):404-411.
8. Munakata H, Higashi M, Tamura T, Adachi YU. Fatal airway obstruction due to a ball-valve clot with identical signs of tension pneumothorax. *Acute Crit Care*. 2020 Nov;35(4):298-301.

9. Monceaux G, Périé S, Montravers F, Angelard B, Corlieu P, St Guily JL. Osteoradionecrosis of the hyoid bone: A report of 3 cases. *Am. J. Otolaryngol.* 1999 Nov/Dec;20(6):400-4.
10. Wang S, Stanisce L, Begun Z, Wilson T, Ahmad N, Kubicek GJ, et al. Osteoradionecrosis of the hyoid presenting as acute airway compromise. *Head Neck.* 2021 Sep;43(9):E41-E4.
11. Tabuchi K, Nakayama M, Nishimura B, Hayashi K, Hara A. Early Detection of Nasopharyngeal Carcinoma. *Int J Otolaryngol.* 2011;2011:638058.
12. Archer JB, Sun H, Bonney PA, Zhao YD, Hiebert JC, Sanclement JA, et al. Extensive traumatic anterior skull base fractures with cerebrospinal fluid leak: classification and repair techniques using combined vascularized tissue flaps. *J Neurosurg.* 2016 Mar;124(3):647-56.
13. Mallen RW, Shandro WG. Nasopharyngeal carcinoma in Eskimos. *Can J Otolaryngol.* 1974;3(2):175-9.
14. Hurst EE. Malignant tumors in alaskan eskimos: Unique predominance of carcinoma of the esophagus in alaskan eskimo women. *Cancer.* 1964 Sep;17(9):1187-96.
15. Melbye M, Ebbesen P, Levine PH, Bennike T. Early primary infection and high Epstein-Barr virus antibody titers in Greenland Eskimos at high risk for nasopharyngeal carcinoma. *Int J Cancer.* 1984 Nov;34(5):619-23.
16. Shahidi N, Maleki H. Epidemiology, clinical presentations and radiologic findings of nasopharyngeal cancers. *Med J Tabriz Univ Med Sci Health Serv.* 2021;42(6):642-8.
17. Quer M, León X, Orús C, Recher K, Gras JR. Head and neck carcinoma: Analysis of 2.500 cases. *Acta Otorrinolaringol Esp.* 2001 Apr;52(3):201-5.
18. Martinez-Perez R, Gómez E, Rayo N. Spontaneous Tension Pneumocephalus: A Rare Complication of Shunting. *World Neurosurg.* 2017 Apr;100:710.e11-3.
19. Jain C, Rewatkar A, Roy AK, Devi BI. Delayed Posttraumatic Tension Pneumocephalus: Case Report and Review of Literature. *IJNT.* 2023;20(2):151-4.
20. Kankane V, Jaiswal G, Gupta T. Posttraumatic delayed tension pneumocephalus: Rare case with review of literature. *Asian J Neurosurg.* 2016 Oct/Dec;11(4):343-7.
21. Dalolio M, Cordier D, Al-Zahid S, Bennett WO, Prepageran N, Waran V, et al. The Role of Endonasal Endoscopic Skull Base Repair in Posttraumatic Tension Pneumocephalus. *J Craniofac Surg.* 2022 May;33(3):875-81.
22. Sumitsawan Y, Chaiyasate S, Chitapanarux I, Anansuthiwara M, Roongrotwattanasiri K, Vaseenon V, et al. Late complications of radiotherapy for nasopharyngeal carcinoma. *Auris Nasus Larynx.* 2009 Apr;36(2):205-9.
23. Jimenez E, Sabater S, Martos A, Carrizo M, Honrubia V, Fernández J, et al. Tension pneumocephalus related to nasopharyngeal carcinoma: A case report. *Rep Pract Oncol Radiother.* 2013;18:S255.
24. Chezian N, Ganapathy D, Jain AR. Management of osteoradionecrosis of oral cavity. *Drug Discov Today.* 2019;12(1):48-52.
25. Huang WB, Wong STS, Chan JYW. Role of surgery in the treatment of osteoradionecrosis and its complications after radiotherapy for nasopharyngeal carcinoma. *Head Neck.* 2018 Feb;40(2):369-76.
26. Yoo JS, Rosenthal DI, Mitchell K, Ginsberg LE. Osteoradionecrosis of the hyoid bone: imaging findings. *Am J Neuroradiol.* 2010 Apr;31(4):761-6.
27. Németh Z, Somogyi A, Takácsi-Nagy Z, Barabás J, Németh G, Szabó G. Possibilities of preventing osteoradionecrosis during complex therapy of tumors of the oral cavity. *Pathol Oncol Res.* 2000;6(1):53-8.
28. Risso A, Zoia C, Gianformaggio C, Pagella F, Pusateri A, Benazzo M, et al. Tension pneumocephalus secondary to osteoradionecrosis of the clivus. *Rep Pract Oncol Radiother.* 2016 Jan/Feb;21(1):71-5.
29. Romero ADCB, Nora JE, Topczewski TE, Aguiar PHP, Alobid I, Rodríguez EF. Cerebrospinal fluid fistula after endoscopic transsphenoidal surgery: Experience in a spanish center. *Arq Neuropsiquiatr.* 2010 Jun;68(3):414-7.
30. Ranwaka AA, Mehta AS. Tension Pneumocephalus after Frontal Sinus Fracture: Mount Fuji Sign. *Int J Otorhinolaryngol Clin.* 2017; 9(2):79-80.
31. Kondo T, Kishida Y, Watanabe T, Nagatani T, Seki Y. Combined Transcranial-endonasal Reconstructive Surgery for Cerebrospinal Fluid Leakage Resulting from Traumatic Anterior Skull Base Fractures Involving the Parasellar Region. *Neurol Med Chir (Tokyo).* 2021 Sep;61(9):557-62.
32. Loya JJ, Mindea SA, Yu H, Venkatasubramanian C, Chang SD, Burns TC. Intracranial hypotension producing reversible coma: A systematic review, including three new cases. A review. *J Neurosurg.* 2012 Sep;117(3):615-28.
33. Wang D, Sharma M. The State of Spontaneous Intracranial Hypotension in 2020: A Mini-Review. *J Neurol Neuromedicine.* 2020;5(4):1-5.
34. Merali Z, Witiw CD, Wang S, Phan N, Yang V. Spontaneous intracranial hypotension resulting in coma: Case report and review of the literature. *Interdiscip Neurosurg.* 2018;11:51-6.
35. Çelik Y, Tekataş A, Albayram S, Asıl T, Ünlü E, Köse H. Spontaneous intracranial hypotension presenting with coma: A case report and literature review. *Agri.* 2015;27(3):160-2.
36. Wang HC, Hwang JC, Peng JP, Hsieh CH, Liliang PC. Tension pneumocephalus: a rare complication of radiotherapy: a case report. *J Emerg Med.* 2006 Nov;31(4):387-9.
37. Healy J, Grant M, Melnyk S, Boldt B. Tension pneumocephalus – A rare complication of cerebrospinal fluid leak. *Radiol Case Rep.* 2019 Mar;14(3):365-7.

38. AbdelRazek AAK, King A. MRI and CT of nasopharyngeal carcinoma. *AJR Am J Roentgenol.* 2012 Jan;198(1):11-18.
39. Michel SJ. The Mount Fuji sign. *Radiology.* 2004 Aug;232(2):449-50.
40. Dardari R, Khyatti M, Cordeiro P, Odda P, ElGueddari B, Hassar M, et al. High frequency of latent membrane protein-1 30-bp deletion variant with specific single mutations in Epstein-Barr virus-associated nasopharyngeal carcinoma in Moroccan patients. *Int J Cancer.* 2006 Apr;118(8):1977-83.
41. Himeno T, Takeshima S, Kubo S, Hara N, Takamatsu K, Kuriyama M. Tension pneumocephalus complicated from bacterial meningitis: a report of case presenting "Mount Fuji sign" in brain CT. *Clin Neurol.* 2013;53(6):478-81.
42. Mammis A, Agarwal N, Eloy JA, Liu JK. Intraventricular tension pneumocephalus after endoscopic skull base surgery. *J Neurol Surg A Cent Eur Neurosurg.* 2013 Dec;74(Suppl 1):e96-e99.