

Medullary colon carcinoma with microsatellite instability: case report

Carcinoma medular do cólon com instabilidade de microssatélites: relato de caso

Mayra Wilma Martins Cardoso Soares¹, José Walter Feitosa Gomes¹, Elam Vasconcelos de Aquino¹, Igor Santos Costa², Gabriel Sampaio Feitosa³, Mariana Macambira Noronha³, Leonardo Saraiva Pontes⁴

ABSTRACT

Colorectal cancer is the third most common neoplasm and the second most lethal worldwide. The most common histological type is adenocarcinoma, characterized by its glandular pattern. Medullary colon carcinoma is a rare histological variant of colorectal cancer, characterized by a predominantly solid architecture, poorly differentiated or undifferentiated morphology, often associated with an anomalous immunophenotype and microsatellite instability. The present study reports a case in an academic service of general surgery of a 74-year-old patient who presented with a tumor of the ascending colon, histologically with an exuberant lymphocytic infiltrate, suggestive of large cell lymphoma, but which was revealed by subsequent immunohistochemistry to be medullary carcinoma of the colon with microsatellite instability.

Keywords: Colonic neoplasms; Microsatellite instability; Carcinoma, Medullary.

1. Instituto Doutor José Frota, General Surgery Center - Fortaleza - Ceará - Brazil.
2. Argos, Pathology Laboratory - Fortaleza - Ceará - Brazil.
3. Federal University of Ceará, Faculty of Medicine - Fortaleza - Ceará - Brazil.
4. Walter Cantídio University Hospital, Clinical Oncology Service - Fortaleza - Ceará - Brazil.

Financial support: none to declare.

Conflicts of interest: The authors declare no conflict of interest relevant to this manuscript.

Correspondence author: Mariana Macambira Noronha.

E-mail: mariananoronha@alu.ufc.br

Received on: October 13, 2023 | **Accepted on:** January 4, 2024 | **Published on:** February 7, 2024

DOI: <https://doi.org/10.5935/2526-8732.20240447>



This is an open-access article distributed under the terms of the Creative Commons Attribution License.

RESUMO

O câncer colorretal é a terceira neoplasia mais comum e a segunda mais letal no mundo. O adenocarcinoma é o tipo histológico mais comum, caracterizado pelo seu padrão glandular. O carcinoma medular do cólon é uma variante histológica rara do câncer colorretal, caracterizada por uma arquitetura predominantemente sólida, morfologia pouco diferenciada ou indiferenciada, frequentemente associada a um imunofenótipo anômalo e instabilidade de microssatélites. O presente estudo relata um caso em um serviço acadêmico de cirurgia geral de um paciente de 74 anos que apresentou tumor de cólon ascendente, histologicamente com infiltrado linfocitário exuberante, sugestivo de linfoma de grandes células, mas que foi revelado através de exame subsequente imunohistoquímico como carcinoma medular do cólon com instabilidade de microssatélites.

Palavras-chave: Neoplasias colônicas; Instabilidade de microssatélites; Carcinoma medular.

INTRODUCTION

Colorectal cancer (CRC) is the third most common neoplasm and the second most lethal worldwide.^[1,2] South America occupies eighth place in the ranking of regions with the highest incidence and mortality globally,^[1] and in Brazil, an estimated incidence of 46 thousand new cases for the three-year period from 2023 to 2025.^[3]

The most common histological type is adenocarcinoma, characterized by its glandular pattern.^[4] Medullary colon carcinoma (MCC) is a rare histological variant of CRC, characterized by a predominantly solid architecture, poorly differentiated or undifferentiated morphology, often associated with an anomalous immunophenotype and microsatellite instability,^[5,6] most frequently in combination with *BRAF* mutations. According to several studies, the incidence of MCC is less than 0.03%^[7,8] and corresponds to between 0.1 and 3% of all CRC.^[5,9] It mainly affects elderly women and has a predilection for the right colon, with patients typically presenting characteristic symptoms of abdominal pain and changes in bowel habits.^[10]

MCC morphologically presents itself with layers of malignant cells with vesicular nuclei, prominent nucleoli, and infiltration by intraepithelial lymphocytes, with little or no glandular differentiation.^[10] Neoplastic cells frequently present epigenetic silencing of *MLH1* and microsatellite instability, of somatic or germline origin (lynch syndrome), as well as mutation of the *BRAF* V600 gene.^[8]

Due to its clinical, immunohistology, and genetic peculiarities, and because it has recently been recognized by the World Health Organization (WHO) as a histological variant distinct from the others,^[10] the diagnosis of MCC constitutes a challenge and can be mistakenly diagnosed as poorly differentiated adenocarcinoma or undifferentiated, such as lymphoproliferative neoplasia and, occasionally, as a neuroendocrine tumor or metastasis of non-colonic origin.^[4,6,9,11]

The present study reports a case in an academic general surgery service of a 74-year-old patient who presented with a tumor of the ascending colon, histologically with exuberant lymphocytic infiltrate, suggestive of large cell lymphoma, but which by subsequent immunohistochemistry was revealed to be medullary colon carcinoma with microsatellite instability (MSI).

Furthermore, due to the rarity of the pathology, a literature review was carried out on the subject to contribute to the knowledge of the disease, facilitating the recognition of the pathology and the management of future similar cases.

Retrospective cross-sectional observational study, carried out by collecting data from medical records and reviewing narrative literature, searching for articles, and using related keywords, on the main medical research platforms (PubMed and SciELO). Furthermore, an informed consent form was provided, with guidance on the possible risks of the research, guaranteeing data anonymity and authorization to analyze data from the patient's medical records to report the case.

CASE REPORT

A 74-year-old female patient with a history of hypertension presented with a history of anorexia, asthenia, and weight loss of 14kg over a period of 3 months, without other associated symptoms. During physical examination, an abdominal mass was identified at the epigastrium-umbilical transition, which continued the investigation with abdominal ultrasound and subsequent contrast-enhanced CT scan of the abdomen, which revealed an expansive lesion in the right iliac fossa measuring 68x66mm.

A colonoscopy was performed, which revealed a lesion with a neoplastic appearance, ulcerative-infiltrative in the topography of the cecum (Figure 1), with a biopsy and positive histological result for chronic lymphoplasmacytic inflammatory infiltrate in the lamina propria and focal active colitis.

A surgical approach was chosen for the patient, and a large tumor mass located in the cecum was found intraoperatively, with a segment of the small intestine attached to it and multiple lymph nodes adjacent to the mesentery. An enterectomy of approximately 40cm was performed, involving the small segments and lymph nodes attached to the tumor mass, followed by an extended right ileocelectomy in oncology with subsequent lateral-lateral ileoanastomosis.

The anatomopathological result of the surgical specimen showed, on macroscopy, an ulcerative tumor lesion in the ceco-colon mucosa, measuring 7.6x7.0cm, infiltrating the muscularis wall and ileocecal valve.

Microscopy of the specimen showed extensive proliferation of lymphoid cells, of medium and large cells, with oval nuclei, irregular chromatin, and evident nucleoli, arranged in sheets, with foci of necrosis, infiltrating to the subserosa, suggestive of lymphoma, in addition to the presence of lymph nodes reactive hyperplastic.

To establish the differential diagnosis, immunohistochemistry was performed on the analyzed pieces, demonstrating positivity for CK7 and CK POLL (see Tables 1 and Figure 1). Thus, the definitive pathological diagnosis was medullary carcinoma of the colon T3N0M0, stage II (AJCC, 8th edition, 2017), with microsatellite instability, based on the negativity of the repair proteins of the *MLH1* and *PMS2* genes (see Tables 1 and Figure 1).

Table 1. Antibody panel studies.

Antibody Panel Studies
Expression by Antibody
CD20 (-) CD3 (-) CD5 (-) BCL2 (-) BCL6 (-) CD30 (-) MUM-1 (-) CD23 (-) CD10 (-) CHROMOGRANIN A (-) SYNAPTOPHYSIN (-) CD56 (-) DESMOSINE (-) CD1A (-) TDT (-) CD34 (-) CD117 (-) CD138 (-) MYOGENIN (-), VIMENTINA (-) CD45 (-) PAX-5 (-) OCT 3/4 (-) DOG-1 (-) S100 (-) HMB-45 (-) CD68 (-) CD43 (-) MYELOPEROXIDASE(-) CK20 (-) TTF-1 (-) CDX2 (-) PSA (-) CK5/6 (-) CALRETENINA (-) MLH1 (-) PMS2 (-)
KI-67 (+) 95% , CYCLIN D1 (+) in few cells, C-MYC (+) in few cells, CD99 (+) in few cells, CK POOL (+) diffused, CK7 (+) focal MSH2 (+) MSH6 (+)

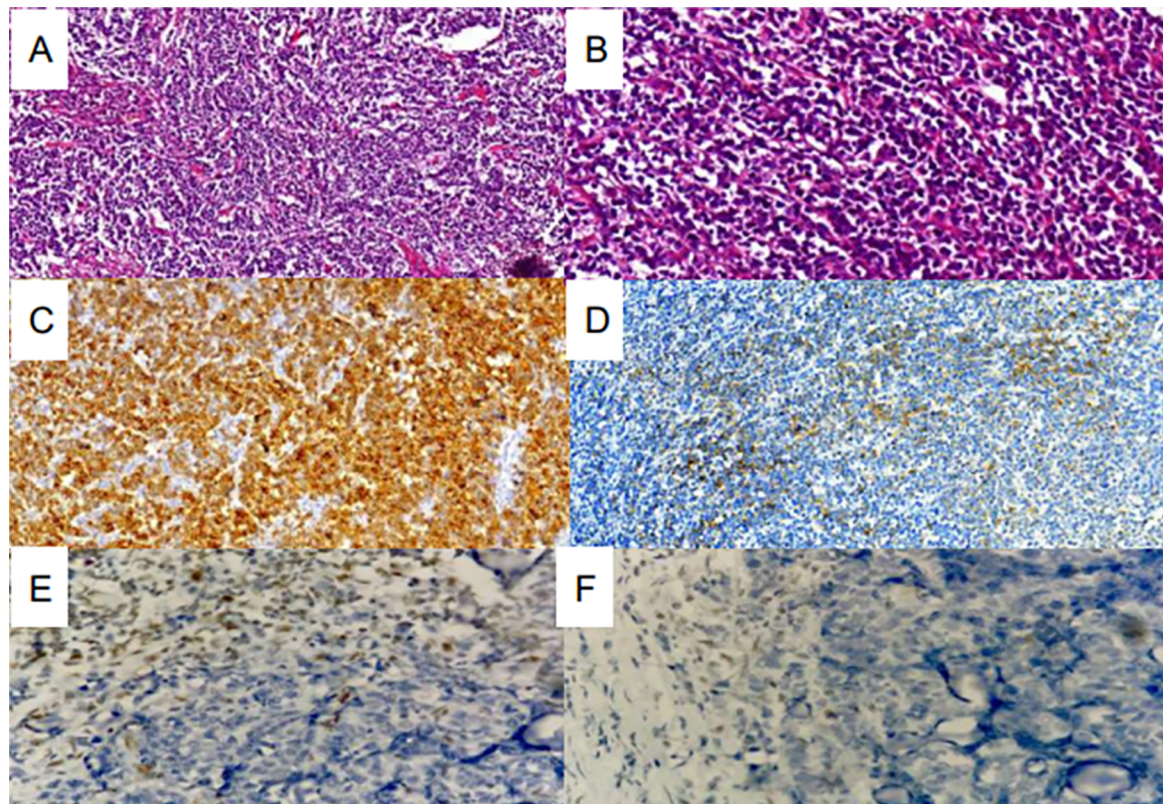


Figure 1. Histopathological and immunohistochemistry findings. Table 2. (A and B) MCC sections showed an infiltrative edge-pushing pattern and a focal anaplastic and discohesive appearance (H&E. x 100 and x 400, respectively). (C and D) CK Pool with diffuse positivity and CK7 with focal positivity (immunohistochemistry). (E And F) neoplastic cell nuclei in both images completely devoid of immunohistochemical staining, while adjacent lymphocytes that permeate the tumor show nuclear staining for MLH1 and PMS2 respectively.

Subsequently, the patient was referred to clinical oncology for adjuvant evaluation, opting for clinical observation every three months.

DISCUSSION

MCC is a rare subtype of colorectal carcinoma first described in 1999 by Jessurun et al.^[6] Between 5-8/10,000 colon cancers present the histological characteristics of MCC^[8], a solid growth pattern, with poorly differentiated or undifferentiated, non-glandular sheets of eosinophilic neoplastic cells with vesicular nuclei, prominent nucleoli, and abundant eosinophilic cytoplasm, generally associated with a significant amount of lymphocytic tumor infiltrate^[12]

The lack of glandular differentiation can be misinterpreted as a poorly differentiated or undifferentiated adenocarcinoma, among other unusual patterns that may be present and lead it to be characterized as lymphoma, neuroendocrine tumor, or metastasis, and its real incidence may be underestimated.^[4] According to a retrospective study carried out by Scott et al. (2021)^[9] of samples from surgical resections of CRC, only one-third of medullary carcinomas were correctly identified, with the other two-thirds classified as poorly differentiated adenocarcinomas without other specifications.

MCC of the colon has a predilection for the right side of the colon in 70 to 100%, more precisely in the proximal portion (74%), affecting female patients with an average age of 69.3 years, typically associated with abdominal pain and change in bowel habits.^[4,10,13] Furthermore, it usually presents as a larger mass compared to adenocarcinoma without other specificities (NOS) and is generally classified as stage II and with little differentiation (72% of cases).^[13] In general, they are diagnosed in stage II, with a favorable prognosis and with fewer lymph nodes and distant metastases compared to poorly differentiated adenocarcinomas.^[10]

The treatment of MCC of the colon is very similar to colon adenocarcinoma, with the surgical approach as the gold standard. Adjuvant chemotherapy is not usually applied, since patients with IMS do not usually respond to fluoropyrimidines.^[1]

According to a recent edition of the WHO Classification of Gastrointestinal Tumors, medullary carcinomas present an aberrant phenotype, with loss of CDX2 and CK20^[12], in addition, they frequently present microsatellite instability, with loss of MLH1 expression and mutation of V600E *BRAF*.

Despite these defined characteristics, diagnosis can be challenging. Additional studies reported more detailed characterization to improve the diagnostic algorithm. Winn et al.^[14] explored an extensive panel including calretinin, CK7, CK20, p53, trefoil factor 3 (TFF3), MLH1, MUC1, and MUC2 to differentiate medullary carcinomas from poorly differentiated colon carcinomas.

In conclusion, the case reports the presence of a rare colon cancer in the population. Due to the limited knowledge about this disease and the few cases reported in the literature, the clinical findings may be inconclusive, and the diagnosis difficult. Thus, further studies are needed to elucidate the management and molecular analysis of this type of cancer.

AUTHORS' CONTRIBUTIONS

MWMCS	Collection and assembly of data, Conception and design, Manuscript writing
JWFG	Collection and assembly of data, Conception and design, Final approval of manuscript, Provision of study materials or patient
EVA	Data analysis and interpretation, Provision of study materials or patient
ISC	Collection and assembly of data, Conception and design, Final approval of manuscript, Manuscript writing, Provision of study materials or patient
GSF	Collection and assembly of data, Data analysis and interpretation, Manuscript writing
MMN	Collection and assembly of data, Conception and design, Data analysis and interpretation, Manuscript writing
LSP	Final approval of manuscript, Provision of study materials or patient

REFERENCES

- Sung H, Ferlay J, Siegel RL, Laversanne M, Soerjomataram I, Jemal A, et al. Global Cancer Statistics 2020: GLOBOCAN Estimates of Incidence and Mortality Worldwide for 36 Cancers in 185 Countries. *CA: a Cancer Journal for Clinicians*. 2021 Feb 4;71(3):209–49.
- Keum N, Giovannucci E. Global burden of colorectal cancer: emerging trends, risk factors and prevention strategies. *Nature Reviews Gastroenterology & Hepatology*. 2019 Aug 27;16(12).
- Ministério da Saúde (BR). Instituto Nacional de Câncer (INCA). Estimativa 2023: incidência de câncer no Brasil [Internet]. Brasília (DF): Ministério da Saúde/ INCA; 2023; [access in 2023 November 20]. Available from: <https://www.inca.gov.br/publicacoes/livros/estimativa-2023-incidencia-de-cancer-no-brasil>
- Nguyen J, Coppola D, Yuan S, Zhang L. Poorly differentiated medullary carcinoma of the colon with an unusual phenotypic profile mimicking high grade large cell lymphoma - a unique case report and review of the literature. *PubMed*. 2014 Jan 1;

5. Remo A, Fassan M, Vanoli A, Bonetti LR, Barresi V, Tatangelo F, et al. Morphology and Molecular Features of Rare Colorectal Carcinoma Histotypes. *Cancers*. 2019 Jul 23;11(7):1036.
6. Jessurun J, Romero-Guadarrama M, J. Carlos Manivel. Medullary adenocarcinoma of the colon: Clinicopathologic study of 11 cases. *Human Pathology*. 1999 Jul 1;30(7):843-8.
7. Pyo JS, Sohn JH, Kang G. Medullary carcinoma in the colorectum: a systematic review and meta-analysis. *Human Pathology*. 2016 Jul;53:91-6.
8. Fatima Z, Sharma P, Youssef B, Krishnan K. Medullary Carcinoma of the Colon: A Histopathologic Challenge. *Cureus*. 2021 Jun 22;
9. Scott N, West NP, Cairns A, Rotimi O. Is medullary carcinoma of the colon underdiagnosed? An audit of poorly differentiated colorectal carcinomas in a large national health service teaching hospital. *Histopathology*. 2021 Apr 19;
10. Kelly ML. Medullary carcinoma in the colon. *ANZ J Surg* [Internet]. 2023 Mar 1 [cited 2023 Apr 17];93(3). Available from: <https://pubmed.ncbi.nlm.nih.gov/35789052/>
11. Martinotti M, Cirillo F, Ungari M, Tanzi G, Rolando G, Tarasconi A, et al. Microsatellite Instability in Medullary Carcinoma of the Colon. *Rare Tumors*. 2016 Mar 1;9(1):23-5.
12. Nagtegaal ID, Odze RD, Klimstra D, Paradis V, Rugge M, Schirmacher P, et al. The 2019 WHO classification of tumours of the digestive system. *Histopathology* [Internet]. 2019 Nov 13 [cited 2019 Dec 22];76(2):182-8. Available from: <https://onlinelibrary.wiley.com/doi/pdf/10.1111/his.13975>
13. Knox RD, Luey N, Sioson L, Kedziora A, Clarkson A, Watson N, et al. Medullary Colorectal Carcinoma Revisited: A Clinical and Pathological Study of 102 Cases. *Annals of Surgical Oncology*. 2015 Jan 9;22(9):2988-96.
14. Winn B, Tavares R, Fanion J, Noble L, Gao J, Sabo E, et al. Differentiating the undifferentiated: immunohistochemical profile of medullary carcinoma of the colon with an emphasis on intestinal differentiation. *Human Pathology*. 2009 Mar;40(3):398-404.