

# Littoral cell splenic angioma, a rare diagnosis of abdominal pain in a child: case report and literature review

Angioma esplênico de células litorais, um diagnóstico raro de dor abdominal em criança: relato de caso e revisão de literatura

Sandra Mara Witkowski<sup>1,2</sup>, Aline Fernanda Pereira<sup>1</sup>, Nathália Riboli da-Silva<sup>1</sup>, Nicole Hoffmann Longa<sup>1</sup>, Rafaela Ramos<sup>1</sup>, Joana Buratto<sup>2</sup>, Caio Raicher<sup>2</sup>

## ABSTRACT

Littoral cell splenic angioma is a rare tumor, especially in the pediatric age group. Patients may experience mild chronic abdominal pain, that does not improve with usual treatments, and is mostly asymptomatic, a challenge for the pediatrics. This article describes the clinical features of a 10-year-old female pediatric patient who had intermittent chronic abdominal pain, diagnosed with littoral cell splenic angioma. This kind of tumor is usually an incidental finding due to its mostly asymptomatic or nonspecific presentation. Splenectomy is the choice due to the possibility of malignant evolution.

**Keywords:** Spleen; Splenectomy; Abdominal pain.

1. Universidade do Vale do Itajaí, Medicine - Itajaí - Santa Catarina - Brazil.
2. Hospital Infantil Pequeno Anjo, Pediatrics - Itajaí - Santa Catarina - Brazil.

**Financial support:** none to declare.

**Conflicts of interest:** The authors declare no conflict of interest relevant to this manuscript.

**Correspondence author:** Sandra Mara Witkowski.

E-mail: sandrawtk@gmail.com

**Received on:** September 16, 2023 | **Accepted on:** November 30, 2023 | **Published on:** December 29, 2023

**DOI:** <https://doi.org/10.5935/2526-8732.20230444>



This is an open-access article distributed under the terms of the Creative Commons Attribution License.

## RESUMO

O angioma esplênico de células litorais é um tumor raro, especialmente na faixa etária pediátrica. Os pacientes podem apresentar dor abdominal crônica leve, que não melhora com os tratamentos habituais e é em sua maioria assintomática, um desafio para a pediatria. Este artigo descreve as características clínicas de uma paciente pediátrica de 10 anos de idade que apresentava dor abdominal crônica intermitente, com diagnóstico de angioma esplênico de células litorais. Esse tipo de tumor geralmente é um achado incidental devido à sua apresentação geralmente assintomática ou inespecífica. A esplenectomia é a escolha devido à possibilidade de evolução maligna.

**Palavras-chave:** Baço; Esplenectomia; Dor abdominal.

## INTRODUCTION

Primary spleen tumors have a low-incidence pathology. They present nonspecific manifestations that can make diagnosis difficult, and are normally only found after surgical removal of the organ and subsequent anatomopathological study.<sup>[1]</sup> They can be classified as either white pulp (lymphatic) or red pulp (vascular). Red pulp is divided into hemangiomas, angiosarcomas, and littoral cell angioma and others.<sup>[2]</sup> Littoral cell angioma (LCA) is a rare tumor, especially in the pediatric age group, with only 12 cases described in the pediatric population to date.

The purpose of this case report is to address the clinical features, diagnosis, treatment, and literature review of a pediatric patient who was diagnosed with littoral cell splenic angioma and investigated at a university pediatric service in southern Brazil. This case report was approved by the ethics committee (approval number 6748222390000120) in 2023.

## CASE REPORT

Ten years old white female patient with diffuse, sporadic, low-intensity abdominal pain for two years was treated at a pediatric outpatient clinic. Three months prior, pain in the left hypochondrium developed, with occasional irradiation of the right hypochondrium. The use of dipyron had no effect, and the pain interfered with her daily activities associated with inappetence and loss of three kilograms (6.61lb) in one month, however normal bowel movements were reported. She presented with no fever, vomiting, nausea, or pathological background.

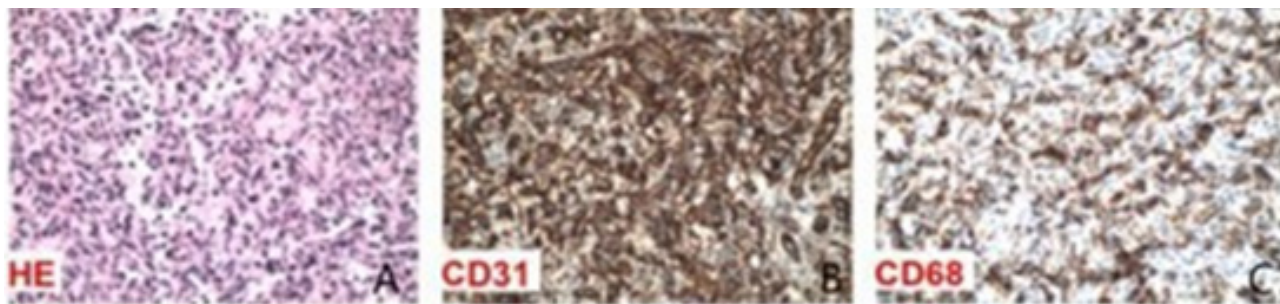
On physical examination, only pale skin and a painful abdomen were observed, as deep palpation was performed on the left hypochondrium.

Laboratory tests, total abdominal ultrasound, and abdominal and pelvic computed tomography were performed. Laboratory tests showed no significant changes (erythrocyte sedimentation speed; glycemia; hepatic, renal, pancreatic, and thyroid function tests;

ferritin; lipidogram; total immunoglobulin A, M, G, and protein electrophoresis), a hemoglobin of 11,6g/% and a hematocrit of 35,4% below expected levels. Total abdominal ultrasound showed a spleen of the usual size, with a nodular hypoechoic image inside, with well-defined and regular contours, measuring approximately 4.41x3.90x4.41 centimeters (cm), volume 39,65cm<sup>3</sup> (Figure 1). Computed tomography of the abdomen and pelvis revealed a solid nodule with hypervascular enhancement, homogeneous and persistent by contrast, located in the upper spleen region, 4,5x4,7cm (Figure 2). On the basis of these results, the patient was referred for surgery.

The surgery was performed without complications. Starting with a left subcostal incision in the layers, a small spleen with a voluminous hilar circulation was observed. Spleen dislocation and detachment along the splenorenal and splenocolic ligaments were performed, in addition to dissection, identification, and ligation of the splenic artery, splenic vein, and short vessels. The surgical specimen was extracted, followed by a review of hemostasis and closure by layers. The spleen, weighing 90 grams and measuring 10,0x5,0 centimeters with the presence of a well-defined and firm light brown lesion measuring 3,5x3,5x3,0 centimeters, was referred to histopathological study and immunohistochemical examination, which showed, in the histological sections, a spleen containing proliferation of monotonous anastomosing vascular channels that resembled splenic sinuses, lined by high endothelial cells. The channels had irregular lumens and solid areas (Figure 3A). Antibody study: positive for Ki-67 - cellular proliferation antigen - (clone M1B1), CD68 - lysosomal protein - (clone KP1), CD34 - hematopoietic cell antigen and pericytes (clone QBEnd10), CD31 - PECAM-1 adhesion molecule, endothelial cells - (JC/70A), and CD163 - hemoglobin-haptoglobin complex - (clone MRQ-26), and negative for CD21 - receptor for C3d, dendritic cells and B lymphocytes - (clone 1F8), and CD8 - cytotoxic T cell antigen - (clone C8/144B) antibodies. The patient was diagnosed with splenic littoral cell angioma that was positive for antibodies against CD31 and CD 68 (Figures 3B and 3C).





**Figure 3A, 3B and 3C.** A. Findings in the histological section of the sample using hematoxylin eosin. Histological sections of the spleen lesion show proliferation of monotonous anastomosing vascular channel lined by tall endothelial cells; B. Immunohistochemical findings. Positive CD68 observed; C. Immunohistochemical findings. Positive CD31 observed.

## DISCUSSION

Littoral cell angioma is a vascular tumor of unknown etiology that arises from cells that line the venous sinuses of the splenic red pulp.<sup>[3]</sup> This primary tumor has dual endothelial and histiocytic differentiation when compared to other red pulp tumors, which express only one endothelial component.<sup>[2]</sup> The pathogenesis is unknown, but it has been proposed to be associated with immune dysregulation or chronic inflammation.<sup>[5]</sup> It was first described in 1991 from a study of 200 cases of benign splenic tumors, identified by a different histology from previously known tumors, such as hemangiomas, lymphangiomas, and hamartomas. It is a condition that occurs at any age and without a sex-based predilection.<sup>[6]</sup> Most cases are of benign origin and unusual in children.<sup>[3,7]</sup> Literature reviews indicate that only 12 cases have been described in the pediatric age range.<sup>[4]</sup>

It is asymptomatic in 55% of cases; however, when symptomatic, it can cause diffuse abdominal pain and fever, splenomegaly, anemia, thrombocytopenia,<sup>[7]</sup> hepatitis, cirrhosis, and portal hypertension.<sup>[2]</sup> Our patient had abdominal pain that had been limiting activities for the last few months, a normal-sized spleen, and unaltered hematological test results despite a hemoglobin of 11,6g/%. It is difficult to radiologically define the diagnosis of littoral cell angioma because of its similarity to other benign tumors.<sup>[6]</sup> Ultrasonographic findings include a single or heterogeneous echotexture mass that may feature cystic areas. On early phase contrast-enhanced computed tomography, it may appear as multiple or solitary hypodense lesions and show changes in density during delayed image testing.<sup>[7,8]</sup> In contrast to the literature, computed tomography has led to a correct diagnostic hypothesis.<sup>[6]</sup> Most littoral cell angiomas have multiple nodules. The patient in question presented with solitary nodules, which are rare. The final diagnosis was histological.<sup>[7]</sup>

The differential diagnoses included hemangioma, hamartoma, lymphoma, and angiosarcoma. Benign tumors of the spleen include hemangiomas and hamartomas. The most common hemangiomas are of vascular origin, and ultrasound imaging reveals homogeneous hypoechoic or hyperechoic lesions.

A rare lesion is a hamartoma, and sonography reveals homogeneous lesions with or without a cystic center. The most prevalent malignant neoplasm is lymphoma, and angiosarcoma of vascular origin is rare and is more susceptible to metastasis and rupture.<sup>[5]</sup>

Histologically, littoral cells are normally found around sinusoids of the red pulp of the spleen. When these cells increase in size, they can become precursors of tumor.<sup>[4]</sup> Immunohistochemistry is the most widely used test for diagnosis, particularly for each tumor.<sup>[9]</sup> Littoral cell angiomas have a combined pattern of endothelial and histiocytic cells.<sup>[11]</sup> In this test, CD34 and CD8 markers are usually negative, while CD31, CD68, and CD21 can be positive.<sup>[4,7-9]</sup> The patient in question was positive for CD31 and CD68 markers, indicating a littoral cell angioma.

In the case reported by Bedir et al. (2014),<sup>[8]</sup> in an 11-year-old girl with upper left quadrant abdominal pain and an ultrasound finding of a solid lesion, measuring 3.7x3.2cm, characterizing isoechoic and echogenic patterns and a magnetic resonance suspicious of a hemangioma, there was no response to clinical management. Only after splenectomy and immunohistochemical tests were positive for CD31 and CD68, but negative for CD34, littoral cell angioma was diagnosed. Accordingly, this patient underwent an immunohistochemical examination similar to ours.<sup>[8]</sup>

Total splenectomy is the best treatment option due to the possibility of malignant lesions. This approach was used in the case described here. Both open and laparoscopic surgeries are options to be considered, although the laparoscopic approach has a shorter operating time and less blood loss during the procedure. Of the 12 patients reported in the pediatric age group, all were investigated with ultrasound, nine underwent total splenectomy, two underwent partial splenectomy, and one underwent biopsy and active follow-up.<sup>[4]</sup>

In addition, it is important that the patient be monitored during the postoperative period to evaluate recurrence or metastasis.<sup>[10,11]</sup> A study by Bisceglia et al. (1998)<sup>[12]</sup> showed that five of the twenty-one cases studied were associated with other malignancies, thus demonstrating the need for

post-surgical follow-up. Postoperative complications can be prevented with prophylactic measures such as patient education, chemoprophylaxis, and immunoprophylaxis. The first comprises guidelines regarding the risks of the splenic condition, the second is the use of antibiotics, and the third is the administration of the anti-pneumococcal vaccine for at least 14 days before elective surgery.<sup>[13]</sup> Antibiotic prophylaxis against pneumococcal infection in splenic patients in the first two years after splenectomy, especially in children, is an important part of preventing fulminant infection.<sup>[14]</sup>

## CONCLUSION

In this case report of littoral cell angioma, the only symptom the patient presented with was abdominal pain, and the treatment was surgery. Awareness of this rare diagnostic possibility is important because of the possibility of malignant evolution. It is usually an incidental finding owing to its mostly asymptomatic or nonspecific presentation. Littoral cell angioma is a rare condition in the pediatric age group, the cause of which is still unknown, and its pathogenesis is uncertain.

Therefore, the few cases reported in the literature should be followed for a better understanding of the pathophysiology of the disease. In addition, further studies are needed to investigate the prevalence of littoral cell angioma of the spleen in pediatric patients, corroborating early diagnosis and appropriate management to avoid possible progression to malignancy.

## AUTHORS' CONTRIBUTIONS

SMW	Collection and assembly of data, Conception and design, Data analysis and interpretation, Final approval of manuscript, Manuscript writing, Provision of study materials or patient
AFP	Collection and assembly of data, Conception and design, Data analysis and interpretation, Final approval of manuscript, Manuscript writing, Provision of study materials or patient
NHL	Collection and assembly of data, Conception and design, Data analysis and interpretation, Final approval of manuscript, Manuscript writing, Provision of study materials or patient
RR	Collection and assembly of data, Conception and design, Data analysis and interpretation, Final approval of manuscript, Manuscript writing, Provision of study materials or patient
JB	Collection and assembly of data, Conception and design, Final approval of manuscript, Provision of study materials or patient
CR	Collection and assembly of data, Final approval of manuscript, Provision of study materials or patient

## REFERENCES

- Roseira LFT, Loiola FC, Guedes VR. Neoplasias primárias do baço. *Rev Patol Tocantins*. 2017 Jun; [cited 2020 Jan 30]; 4(2):21-4. Available from: <https://sistemas.uft.edu.br/periodicos/index.php/patologia/article/view/3461>
- Roldan-Vasquez E, Roldan-Vasquez A, Jarrin-Estupiñan X, Roldan-Crespo J. Case report: Infrequent littoral cell angioma of the spleen. *Int J Surg Case Rep*. 2021;85:106242. DOI: <https://doi.org/10.1016/j.ijscr.2021.106242>
- Rai M, Gupta N. Littoral cell splenic angioma [Internet]. Bethesda: StatPearls; 2021; [access in 2022 Jan 30]. Available from: <https://www.ncbi.nlm.nih.gov/books/NBK553085/>
- Liagat N, Madani AA, Kausar N, Almainani MOA, Mahomed A. Littoral cell angioma of the spleen in a child with Cornelia De Lange syndrome. *J Pediatr Surg Case Rep*. 2021;69:101868. DOI: <https://doi.org/10.1016/j.epsc.2021.101868>
- Zeng QY, Liao J, Song Y, Zhang DQ, Li H, Wang J. Multimodality imaging findings of splenic littoral cell angioma: a case description and analysis of literature. *Quant Imaging Med Surg*. 2023 Apr;13(4):2740-3. DOI: <https://doi.org/10.21037/qims-22-897>
- Arcuri PP, Taglianetti ST, Vavalà B, Battaglia C, Laganà D, Manti D. Incidental littoral cell angioma of the spleen: cross-sectional imaging findings and review of the literature. *Radiol Case Reports*. 2022 Oct;17(10):3545-50. DOI: <https://doi.org/10.1016/j.radcr.2022.06.063>
- Matuszczak E, Reszec J, Debek W, Hermanowicz A, Chyczewski L. Is littoral cell angioma of the spleen as rare as previously believed in the pediatric population?. *Folia Histochem Cytobiol*. 2012;50(3):480-5. DOI: <https://doi.org/10.5603/19761>
- Bedir R, Sehitoglu I, Calapoglu AS, Yurdakul C. A rare case of splenic littoral cell angioma in a child. *J Lab Physicians*. 2014;6(2):117-20. DOI: <https://doi.org/10.4103/0974-2727.141511>
- Bouzayan L, Rachid J, Mabrouk MY, Ayoub M, Abdali G, Haloui A, et al. Littoral cell angioma of spleen: a rare case report. *Ann Med Surg*. 2022 Jul;79:103904. DOI: <https://doi.org/10.1016/j.amsu.2022.103904>
- Pillay Y, Shokeir MO. Case report of a littoral cell angioma of the spleen and accessory spleens: a benign vascular tumour. *Int J Surg Case Reports*. 2017;40:109-12. DOI: <https://doi.org/10.1016/j.ijscr.2017.09.017>
- Cai YQ, Wang X, Ran X, Liu XB, Peng B. Laparoscopic splenectomy for splenic littoral cell angioma. *World J Gastroenterol*. 2015 Jun;21(21):6660-4. DOI: <https://doi.org/10.3748/WJG.V21.I21.6660>
- Bisceglia M, Sickel JZ, Giangaspero F, Gomes V, Amini M, Michal M. Littoral cell angioma of the spleen: an additional report of four cases with emphasis on the association with visceral organ cancers. *Tumor J*. 1998 Sep/Oct;84(5):595-9. DOI: <https://doi.org/10.1177/030089169808400516>

13. Moreira C. Esplenectomias não traumáticas em adultos e crianças: um estudo comparativo [dissertation] [Internet]. Florianópolis: Universidade Federal de Santa Catarina (UFSC); 2002; [access in 2022 Feb 10]. Available from: <https://repositorio.ufsc.br/handle/123456789/114176>
14. Marques RG, Petroianu A. Infecção fulminante pós-esplenectomia. *Arq Gastroenterol.* 2003 Mar;40(1):1-8. DOI: <https://doi.org/10.1590/S0004-28032003000100011>