

Uterine carcinosarcoma with microsatellite instability - does immunotherapy modify the therapeutic scenario? A case report and literature review

Carcinossarcoma uterino com instabilidade de microssatélite - a imunoterapia modifica o cenário terapêutico? Relato de caso e revisão da literatura

Diocesio Alves Pinto Andrade^{1,2}, Eduardo Paulino^{2,3}, Isabela Panzeri Carlotti Buzatto⁴, Danilo Tadao Wada⁴, Warne Pedro Andrade⁵, Andreia Cristina Melo^{2,3,6}, Angelica Nogueira-Rodrigues^{2,5,7}

ABSTRACT

Carcinosarcomas were reclassified by World Health Organization as high-grade uterine carcinomas in 2014. Due to its rare histology, comprising only 5% of uterine carcinomas, there is a small representation of this tumor in studies that evaluate metastatic uterine carcinomas treatment. In 2022, the treatment of metastatic uterine carcinomas has changed dramatically with the inclusion of immunotherapy in the therapeutic arsenal, either as a monotherapy or in combination with lenvatinib. The status of microsatellites is paramount in the therapeutic decision for this tumor; carcinosarcoma patients haven't been included in randomized trials so far. Here we report the case of a 60-year-old woman diagnosed with recurrent carcinosarcoma metastatic to the liver and pelvis. Immunohistochemistry demonstrated microsatellite instability (loss of MLH1 and PMS2 nuclear staining). She received immunotherapy with pembrolizumab every three weeks as monotherapy and after 4 cycles, she achieved a complete radiological response in the liver and a partial response in the pelvis.

Keywords: Microsatellite instability; Carcinosarcoma; Immunotherapy; Endometrial neoplasms.

1. Oncoclínicas - Ribeirão Preto, Brazil, Oncology - Ribeirão Preto - São Paulo - Brazil.
2. EVA - Brazilian Gynecologic Oncology Group, Oncology - São Paulo - São Paulo - Brazil.
3. Brazilian Nacional Cancer Institute - INCA, Rio de Janeiro, Brazil, Oncology - Rio de Janeiro - Rio de Janeiro - Brazil.
4. Universidade de São Paulo, Ribeirão Preto, Brazil, Oncology - Ribeirão Preto - São Paulo - Brazil.
5. Oncoclínicas - Belo Horizonte, Brazil, Oncology - Belo Horizonte - Minas Gerais - Brazil.
6. Oncoclínicas - Rio de Janeiro, Brazil, Oncology - Rio de Janeiro - Rio de Janeiro - Brazil.
7. Universidade Federal de Minas Gerais, Belo Horizonte, Brazil, Oncology - Belo Horizonte - Minas Gerais - Brazil.

Financial support: none to declare.

Conflicts of interest: The authors declare no conflict of interest relevant to this manuscript.

Correspondence author: Diocesio Alves Pinto Andrade.

E-mail: diocesio@yahoo.com

Received on: May 27, 2023 | **Accepted on:** July 20, 2023 | **Published on:** August 31, 2023

DOI: <https://doi.org/10.5935/2526-8732.20230423>

RESUMO

Os carcinossarcomas foram reclassificados pela Organização Mundial de Saúde como carcinomas uterinos de alto grau em 2014. Devido à sua rara histologia, compreendendo apenas 5% dos carcinomas uterinos, há uma pequena representatividade desse tumor em estudos que avaliam o tratamento de carcinomas uterinos metastáticos. Em 2022, o tratamento dos carcinomas uterinos metastáticos mudou drasticamente com a inclusão da imunoterapia no arsenal terapêutico, seja em monoterapia ou em combinação com lenvatinibe. O estado dos microssatélites é fundamental na decisão terapêutica para este tumor; pacientes com carcinossarcoma não foram incluídos em estudos randomizados até o momento. Aqui relatamos o caso de uma mulher de 60 anos com diagnóstico de carcinossarcoma recidivado metastático para o fígado e pelve. A imuno-histoquímica demonstrou instabilidade microssatélite (perda da coloração nuclear MLH1 e PMS2). Ela recebeu imunoterapia com pembrolizumabe a cada três semanas em monoterapia e após 4 ciclos obteve resposta radiológica completa no fígado e resposta parcial na pelve.

Descritores: Instabilidade de microssatélites; Carcinossarcoma; Imunoterapia; Neoplasias endometriais.

INTRODUCTION

After GOG 209, the first line treatment of metastatic endometrial cancer is based on carboplatin plus paclitaxel chemotherapy. As of second line, monotherapy such as doxorubicin or gemcitabine demonstrates low response rates, progression-free survival, and overall survival.^(1,2) Recently, this scenario has changed positively following the results of immunotherapy in second-line treatment. After failure to platinum, KEYNOTE-775 study confirmed pembrolizumab plus lenvatinib as the standard of care for patients with microsatellite stable tumors.⁽³⁾ For patients whose tumors have microsatellite instability-high (MSI-H) or mismatch repair deficiency (dMMR), anti-PD-1 (pembrolizumab or dostarlimab) have shown excellent results as monotherapy and is considered the preferred choice in this clinical context.^(4,5)

Since the 2014 World Health Organization (WHO) classification, carcinosarcomas have been reclassified as uterine carcinomas (previously they were classified as uterine sarcomas). This change considers that carcinosarcomas are metaplastic carcinomas with the presence of sarcomatous metaplasia in their embryonic epithelial origin.⁽⁶⁾ However, this histology was not usually included in immunotherapy studies for the treatment of metastatic endometrial cancer.

The frequency of MSI-H or dMMR is uncertain in carcinosarcomas, as well as the benefit of immunotherapy for these patients. A recent Korean series published by Noh et al. (2022)⁽⁷⁾ showed up to 30% prevalence of MSI-H or dMMR in this subtype of endometrial cancer. Herein we report a case of MSI-H recurrent metastatic uterine carcinosarcoma that has responded to immunotherapy treatment.

CASE REPORT

A 60-year-old woman with a history of regular gynecological follow-ups initiated with vaginal bleeding in December 2019. A transvaginal ultrasound was performed in January 2020 and showed an endometrial thickening of 15.5 millimeters. Hysteroscopy was indicated, but due to the COVID-19 pandemic, the patient postponed the exam to October 2020.

The patient underwent hysteroscopy in October 2020, which showed a fragmented fibrous structure exteriorizing in the external cervical orifice. The histopathology demonstrated an endometrial neoplasm composed of well-differentiated endometrioid adenocarcinoma associated with atypical spindle cells with frequent mitotic figures. Immunohistochemistry panel confirmed carcinosarcoma (desmin, EMA, AE1/AE3, CA-125, vimentin, and p53 positive). Clinical staging confirmed disease confined to the uterus and no lymph node enlargement.

The patient was submitted to surgery with hysterectomy, bilateral salpingo-oophorectomy and pelvic lymphadenectomy in November 2020. The final report confirmed a 4.8x2.4cm lesion affecting from the uterine fundus to the cervical isthmus and infiltrating the entire thickness of the myometrium, presence of lymphovascular invasion, and 3 out of 7 left pelvic lymph nodes and 3 out of 3 right pelvic lymph nodes compromised (clinical stage IIIC1 – pT1bN1M0). She received six cycles of adjuvant chemotherapy (carboplatin AUC 6 plus paclitaxel 175mg/m² every three weeks) between December 2020 to March 2021. Subsequently, she received adjuvant external beam radiotherapy (4,500cGy at 180cGy/fraction in 25 fractions between March 2021

to May 2021) and brachytherapy (3 insertions of 800cGy in July 2021).

In May 2022 she developed right iliac fossa pain. The abdominal MRI showed an irregular heterogeneous mass of 3.6x2.7cm in the right pelvic region between psoas muscle and vertebral body of L4 and an enlarged lymph node in the left peri-aortocaval chain measuring 2.4x1.4cm. The pelvic lesion was in contact with iliac vessels and right ureter leading to moderate ipsilateral hydronephrosis. A double-J stent was inserted, and a somatic and germline genetic panel was performed. The somatic panel was inconclusive due to the quality of the tumor sample. The germline panel had no mutations with clinical significance. The immunohistochemistry for the microsatellite proteins showed loss of MLH1 and PMS2 nuclear staining.

The patient persisted with severe pain in the lower abdomen, needing painkillers on an ongoing basis (morphine 15mg every 4 hours; dipyron 1,000mg every 6 hours; pregabalin 75mg every 12 hours). New imaging was performed before starting the systemic treatment (May 2022). Chest computed tomography scan (CT) showed no evidence of disease, but abdominal MRI revealed multiple liver lesions (at least 25), the two largest in segments V and VI measuring 2.5cm and 3.0cm respectively; heterogeneous expansive formation located in the right pelvic region measuring 3.8x3.6cm; para-aortic and infrarenal lymphadenopathy measuring 2.7x1.8cm. The patient was started on pembrolizumab 200mg intravenously every 3 weeks as monotherapy. After the third cycle in mid-September 2022, the patient experienced complete pain resolution and discontinued ongoing analgesics (morphine and pregabalin; she continued to use dipyron if there was mild pain). A new abdominal MRI was performed in October 2022 showing complete disappearance of the multiple

hepatic nodular lesions, and partial response in the heterogeneous mass located in the right pelvic region measuring 3.4x2.7cm (prior: 3.8x3.6cm); complete regression was also observed in para-aortic and infrarenal lymphadenopathy (prior: 2.7x1.8cm) (Figure 1). Considering the assessment by RECIST version 1.1 (Response Evaluation Criteria in Solid Tumors), the patient achieved a partial response.

No grade 3 or 4 toxicities were experienced during treatment. She remained asymptomatic and new imaging tests were performed in March 2023, maintaining complete disappearance of the liver lesions and a decrease in the right pelvic mass - partial response by RECIST version 1.1 (Figure 2).

DISCUSSION

Uterine carcinosarcoma is a rare tumor accounting for approximately 5% of all uterine carcinomas. It is a biphasic tumor where the sarcomatous component develops from a de-differentiation of the epithelial element.⁽⁸⁾ Recent SEER (the Surveillance, Epidemiology, and End Results) data demonstrate that the proportion of carcinosarcomas cases among all uterine carcinomas has been increasing in recent decades, ranging from 1.7% to 5.6% between the years 1973 to 2013. These results are associated with an increase in the number of black women and a drop in the number of white women in the studied database.⁽⁹⁾ Therefore, it is necessary to include this histological subtype in endometrial carcinoma studies since its prevalence is becoming more frequent in the daily routine of oncologists.

We describe a woman with carcinosarcoma stage IIIC1 treated with surgery followed by chemotherapy and radiotherapy who had an abdominal recurrence approximately 12 months after the end of the treatment. Following current scientific evidence, this patient should receive first-line palliative

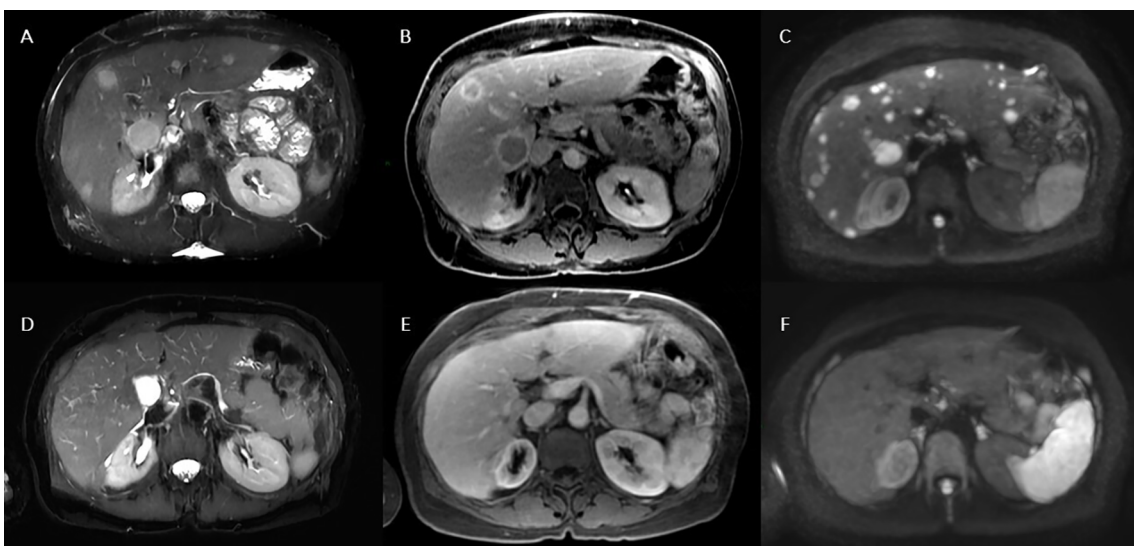


Figure 1. Liver metastases response at MRI exam. Axial plane images showing multiples liver metastasis in both hepatic lobes (upper images) at T2 fat-sat (A and D), portal-phase post-contrast T1 fat-sat (B and E) and diffusion-weighted images (C and F) with complete response after immunotherapy (bottom images).

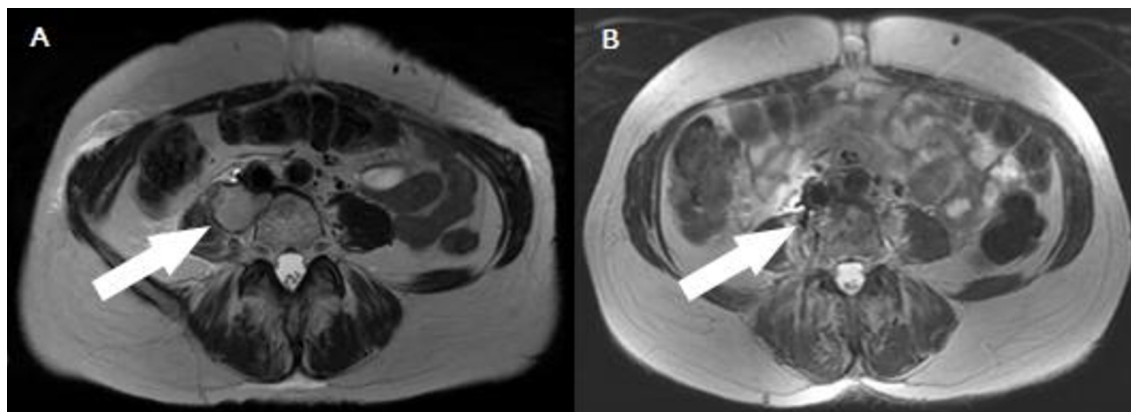


Figure 2. Axial image of MRI exam of October 2022 showing right pelvic mass (narrow A); exam of March 2023 with partial response of the lesion (narrow B).

chemotherapy with a median overall survival of 10 months.⁽²⁾ However, when we carried out microsatellite instability research, this patient had loss of MLH1 and PMS2 nuclear staining. Disregarding the fact that this patient was a carcinosarcoma, the results of immunotherapy studies for metastatic endometrial carcinoma with microsatellite instability showed an objective response rate ranging between 45% and 57.1% and median overall survival not achieved in the KEYNOTE-158 study.^(4,5)

The Cancer Genome Atlas (TCGA) of uterine carcinosarcoma published in 2017 evaluated genomic, epigenomic, transcriptomic, and proteomic characteristics of this tumor. In addition to classic mutations seen in other uterine carcinomas histologies (*TP53*, *PTEN*, *PIK3CA*, and *KRAS*), a higher prevalence of the *EMT* (epithelial-to-mesenchymal transition gene) mutation has been demonstrated. Of the 57 samples evaluated, in only two there was silencing of mismatch repair gene *MLH1*.⁽¹⁰⁾ Segura et al., published in 2020,⁽¹¹⁾ a series of 276 uterine carcinosarcomas patients, of which 6.2% had dMMR. Furthermore, this subgroup of dMMR did not have *TP53* mutation and they developed the tumor at a mean age of 60 years, ten years earlier than the overall mean for carcinosarcomas. In the present case, the patient was diagnosed with carcinosarcoma at exactly 60 years, the same age as the dMMR patients in the previous study.

Although carcinosarcomas have not been included in immunotherapy studies for the treatment of metastatic uterine carcinomas, some case reports/case series have been published.⁽³⁻⁵⁾ Hunt et al. (2021)⁽¹²⁾ evaluated seven carcinosarcomas patients who had progressed to two previous treatment lines. Only one patient had dMMR. Results were disappointing with a median overall survival of 2.8 months and no objective response rate in this series. An American case report published in 2018 and another Chinese one published in 2020 of metastatic uterine carcinosarcoma patients with dMMR demonstrated long-lasting responses to immunotherapy treatment.

^(13,14) In our case report, the patient presented liver's complete radiological response and partial radiological response in the right iliac fossa lesion after 4 cycles. She maintains excellent clinical status with no analgesics or treatment-related symptoms until further response assessment performed in March 2023. Despite the excellent response in the use of isolated immunotherapy, this is a case report that presents its limitations in terms of levels of evidence in the scientific literature.

There is a phase 2 study enrolling patients with metastatic uterine carcinosarcoma in patients previously exposed to platinum-based chemotherapy, testing pembrolizumab and lenvatinib regardless of microsatellite instability status.⁽¹⁵⁾ This fact demonstrates the importance of evaluating better treatments for this rare histology of uterine carcinomas.

CONSENT

Written consent was obtained from the patient for publication of this case report. It was conducted following the Declaration of Helsinki ethical principles, and Oncoclínicas Group Ethical Review Board approved it in January 2023 (Reference number 5.862.574).

AUTHOR CONTRIBUTIONS STATEMENT

Diocésio Andrade, Angelica Nogueira, Andreia Cristina de Melo, and Eduardo Paulino were responsible for the conceptualization and supervision of the manuscript. The original manuscript was drafted by Diocésio Andrade and subsequently reviewed and edited by all authors. All authors have contributed to the synthesis of the discussion and have approved the final version.

DECLARATION OF COMPETING INTEREST

The authors declare that they have no known competing financial interests or personal relationships that could have appeared to influence the work reported in this paper.

AUTHORS' CONTRIBUTIONS

DAPA	Collection and assembly of data, Conception and design, Data analysis and interpretation, Final approval of manuscript, Manuscript writing, Provision of study materials or patient
EP	Conception and design, Final approval of manuscript, Manuscript writing
IPCB	Final approval of manuscript, Manuscript writing
DTW	Final approval of manuscript, Manuscript writing
WPA	Final approval of manuscript, Manuscript writing
ACM	Conception and design, Final approval of manuscript, Manuscript writing
ANR	Conception and design, Final approval of manuscript, Manuscript writing

REFERENCES

- Miller DS, Filiaci VL, Mannel RS, Cohn DE, Matsumoto T, Tewari KS, et al. Carboplatin and Paclitaxel for Advanced Endometrial Cancer: Final Overall Survival and Adverse Event Analysis of a Phase III Trial (NRG Oncology/GOG0209). *J Clin Oncol*. 2020 Nov;38(33):3841-50.
- Heffernan K, Nikitas FS, Shukla U, Camejo HS, Knott C. Previously treated recurrent or advanced endometrial cancer in England: a real-world observational analysis. *Gynecol Oncol*. 2022 Aug;166(2):317-25.
- Makker V, Colombo N, Casado-Herráez A, Santin AD, Colomba E, Miller DS, et al. Lenvatinib plus pembrolizumab for advanced endometrial cancer. *N Engl J Med*. 2022 Feb;386(5):437-48.
- O'Malley DM, Bariani GM, Cassier PA, Marabelle A, Hansen AR, Acosta AJ, et al. Pembrolizumab in patients with microsatellite instability-high advanced endometrial cancer: results from the KEYNOTE-158 Study. *J Clin Oncol*. 2022 Mar;40(7):752-61.
- Oaknin A, Gilbert L, Tinker AV, Brown J, Mathews C, Press J, et al. Safety and antitumor activity of dostarlimab in patients with advanced or recurrent DNA mismatch repair deficient/microsatellite instability-high (dMMR/MSI-H) or proficient/stable (MMRp/MSS) endometrial cancer: interim results from GARNET-a phase I, single-arm study. *J Immunother Cancer*. 2022;10(1):e003777.
- Kurman RJ, Carcangiu ML, Herrington CS, Young RH. Tumours of the uterine corpus. WHO Classification of Tumours of Female Reproductive Organs. 4th ed. Lyon: International Agency for Research on Cancer (IARC); 2014. p. 121-54.
- Noh JJ, Kim MK, Choi MC, Lee JW, Park H, Jung SG, et al. Frequency of mismatch repair deficiency/high microsatellite instability and its role as a predictive biomarker of response to immune checkpoint inhibitors in gynecologic cancers. *Cancer Res Treat*. 2022;54(4):1200-8.
- Matsuzaki S, Klar M, Matsuzaki S, Roman LD, Sood AK, Matsuo K. Uterine carcinosarcoma: Contemporary clinical summary, molecular updates, and future research opportunity. *Gynecol Oncol*. 2021 Feb;160(2):586-601.
- Matsuo K, Ross MS, Machida H, Blake EA, Roman LD. Trends of uterine carcinosarcoma in the United States. *J Gynecol Oncol*. 2018 Mar;29(2):e22.
- Cherniack AD, Shen H, Walter V, Stewart C, Murray BA, Bowlby R, et al. Integrated molecular characterization of uterine carcinosarcoma. *Cancer Cell*. 2017 Mar;31(3):411-23.
- Segura SE, Nobre S, Hussein YR, Abu-Rustum NR, Weigelt B, Soslow RA, et al. DNA mismatch repair-deficient endometrial carcinosarcomas portend distinct clinical, morphologic, and molecular features compared with traditional carcinosarcomas. *Am J Surg Pathol*. 2020 Nov;44(11):1573-9.
- Hunt JT, Chambers LM, Yao M, Joehlin-Price A, Debernardo R, Rose PG. Lenvatinib plus pembrolizumab in patients with advanced or recurrent uterine carcinosarcoma. *Gynecol Oncol Rep*. 2021 Jul;37:100840.
- Bhangoo MS, Boasberg P, Mehta P, Elvin JA, Ali SM, Wu W, et al. Tumor mutational burden guides therapy in a treatment refractory POLE-mutant uterine carcinosarcoma. *Oncologist*. 2018 May;23(5):518-23.
- Zhu B, Liu Y, Li J, Diao L, Shao L, Han-Zhang H, et al. Exceptional response of cryoablation followed by pembrolizumab in a patient with metastatic cervical carcinosarcoma with high tumor mutational burden: a case report. *Oncologist*. 2020 Jan;25(1):15-8.
- Memorial Sloan Kettering Cancer Center (MSKCC). NCT05147558. A study of pembrolizumab with lenvatinib in women with advanced uterine carcinosarcoma. *ClinicalTrials.gov*. 2022 Dec 07.