

Case report: a rare mediastinal neuroblastoma in an adult associated with syndrome of inappropriate secretion of antidiuretic hormone (SIADH)

Relato de caso: neuroblastoma mediastinal raro em adulto associado à síndrome de secreção inapropriada de hormônio antidiurético (SIADH)

Caio Silvério de Souza¹, Carine Matos Bispo Patury¹, José Slaibi Filho², Paulo Roberto Fontes Athanazio³, Lister Cedro Ramos^{4,5}, Juvenal Mascarenhas Nassri⁶, Laíse Oliveira Pales Santos⁷, Carina Manuela Souza Barreto⁷, Michelle Oliveira Espírito-Santo⁸, Laiane Campos Pereira⁹, Marianna Santos Rodrigues¹⁰

ABSTRACT

Neuroblastoma is an embryonic cancer arising from neural crest stem cell and almost exclusively a pediatric neoplasm. In adults, neuroblastoma is rare and presents worse prognosis compared to children. The most common presentation of this neoplasia is a painless abdominal mass. Other signs and symptoms can be related to mass effect from the primary tumor or as a result of metastatic disease, or paraneoplastic syndromes. There are no well-established treatment guidelines for adults with neuroblastoma. In general, the principle of treatment is determined by risk assessment system, using a multimodal treatment (surgery, chemotherapy, and radiotherapy) based on treatment protocols for this neoplasm in children. This case report refers to the diagnosis of neuroblastoma in mediastinum in a 52-year-old woman with locally advanced disease and not able to be removed to diagnosis, accompanied by hyponatremia as paraneoplastic syndrome, which presented a good response to the treatment established.

Keywords: Neuroblastoma; Mediastinal neoplasms; Adult.

1. Assistência multidisciplinar em oncologia - AMO, Clinical Oncology - Ilhéus - Bahia - Brazil.
2. Assistência multidisciplinar em oncologia - AMO, Mastology - Ilhéus - Bahia - Brazil.
3. Imagepat, Pathology - Salvador - Bahia - Brazil.
4. Assistência multidisciplinar em oncologia - AMO, Radiology - Ilhéus - Bahia - Brazil.
5. Multimagem, Radiology - Ilhéus - Bahia - Brazil.
6. Assistência multidisciplinar em oncologia - AMO, Thoracic surgery - Ilhéus - Bahia - Brazil.
7. Assistência multidisciplinar em oncologia - AMO, Oncology nurse - Ilhéus - Bahia - Brazil.
8. Assistência multidisciplinar em oncologia - AMO, Oncology nutritionist - Ilhéus - Bahia - Brazil.
9. Assistência multidisciplinar em oncologia - AMO, Oncology pharmaceuticals - Ilhéus - Bahia - Brazil.
10. Assistência multidisciplinar em oncologia - AMO, Oncology psychology - Ilhéus - Bahia - Brazil.

Financial support: none to declare.

Conflicts of interest: The authors declare no conflict of interest relevant to this manuscript.

Correspondence author: Caio Silvério de Souza.

E-mail: caio.silverio@hotmail.com

Received on: January 19, 2023 | **Accepted on:** June 21, 2023 | **Published on:** July 31, 2023

DOI: <https://doi.org/10.5935/2526-8732.20230405>

RESUMO

O neuroblastoma é um câncer embrionário proveniente de células-tronco da crista neural e quase exclusivamente uma neoplasia pediátrica. Em adultos, o neuroblastoma é raro e apresenta pior prognóstico em relação às crianças. A apresentação mais comum dessa neoplasia é uma massa abdominal indolor. Outros sinais e sintomas podem estar relacionados ao efeito de massa do tumor primário ou como resultado de doença metastática ou síndromes paraneoplásicas. Não há diretrizes de tratamento bem estabelecidas para adultos com neuroblastoma. Em geral, o princípio do tratamento é determinado pelo sistema de avaliação de risco, utilizando um tratamento multimodal (cirurgia, quimioterapia e radioterapia) baseado em protocolos de tratamento dessa neoplasia em crianças. Este relato de caso refere-se ao diagnóstico de neuroblastoma no mediastino em uma mulher de 52 anos com doença localmente avançada e não passível de retirada ao diagnóstico, acompanhada de hiponatremia como síndrome paraneoplásica, que apresentou boa resposta ao tratamento instituído.

Descritores: Neuroblastoma; Neoplasias do mediastino; Adulto.

INTRODUCTION

Neuroblastoma (NB) is an embryonic cancer arising from neural crest stem cell and are seen in the adrenal medulla and anywhere along the peripheral sympathetic nervous system. It is almost exclusively a pediatric neoplasm and more than 90% of patients are diagnosed under ten years of age.^(1,2) In Brazil, is the third most common malignancy in childhood and adolescence, after leukemia and central nervous system (CNS) tumors.⁽³⁾ However, NB is rare in adults and becomes increasingly scarce in elderly population.^(2,4) The most common locations in adults are the chest, pelvis and neck.^(4,5) Approximately 20% of the cases occur in the mediastinum.^(4,5)

It is characterized by a striking heterogeneity of histology and genetic aberrations resulting in a broad spectrum of clinical behavior, which can range from spontaneous regression to aggressive disease with metastatic dissemination leading to death despite intensive therapy. Usually, adult patients have a poorer outcome compared to children.^(1,6,7)

The diagnosis of adult-onset neuroblastoma is challenging because of its rarity. The most common presentation of neuroblastoma is a painless abdominal mass. Other signs and symptoms can be related to mass effect from the primary tumor, or as a result of metastatic disease, or paraneoplastic syndromes.^(5,8) Like other cancers, it is diagnosed using a combination of laboratory tests, radiographic imaging and pathology. The disease staging is the first-choice assessment and should include computed tomography or magnetic resonance imaging of the area involved, in addition to bone scintigraphy iodine 123 metaiodobenzylguanidine (MIBG), in the suspicion of bone metastases with sensitivity and specificity just above 90%.^(9,10) The role of oncological fluorodeoxyglucose positron emission

tomography (PET-CT-FDG) is still controversial in this diagnosis. A small retrospective study suggested that while MIBG is generally more sensitive for detecting lesions, PET-CT-FDG examination may be better for localizing soft tissue metastases.⁽¹¹⁾

NB in adults is divided into three categories: L1 – localized tumor, not involved vital structures, without imaging defined risk factors and confined a one body compartment. L2 – locoregional tumor with one or more imaging risk factors. M – metastatic disease.⁽¹²⁾ Regarding the pathology, the NB is classified as a favorable or unfavorable prognosis, based on the histological characteristics of the neuroblasts (degree of differentiation and nuclear morphology), associated with the patient's age.⁽¹³⁾

Multimodal treatments are used, including surgery, chemotherapy, and radiotherapy. There are no well-established treatment guidelines for adults with neuroblastoma. In general, the treatment principle is decided by the risk assessment system.^(14,15)

In patients with localized disease and low risk, surgery is the primary treatment modality, without the need for adjuvant chemotherapy and/or radiotherapy.^(16,17) For intermediate risk patients, surgery associated with polychemotherapy (doxorubicin, cyclophosphamide, platinum, and etoposide) is the standard treatment, with radiotherapy used only if progression and/or spinal cord compression.⁽¹⁸⁾ In high-risk patients, trimodality should be used (surgery, high-dose polychemotherapy associated with autologous transplantation and radiotherapy).^(19,20) Biological therapy with isotretinoin is the basis of maintenance therapy.⁽²⁰⁾ In metastatic disease, polychemotherapy is recommended with regimen based on doxorubicin, vincristine, cyclophosphamide, cisplatin and

etoposide.⁽²¹⁾ Immunotherapy against an antigen expressed in the tumor (GD2 dysialoganglioside), using anti-GD2 antibody (dinutuxumab) has shown promising results in high-risk and metastatic disease.⁽²²⁾

There are only a few case reports about neuroblastoma in adult in the literature. Here, we present a rare case of anterior mediastinal neuroblastoma in a female adult associated with SIADH, which was treated by means of neoadjuvant chemotherapy, surgery and radiotherapy.

CASE REPORT

A 52-year-old female patient, hypertensive, without other relevant comorbidities, a mother with rectal cancer as the only cancer family history, began investigating respiratory tract infection in April 2020 during the pandemic COVID-19. Chest X-ray showed mediastinal enlargement and computed tomography (CT) of the chest performed in sequence showed a large expansive formation of the anterior mediastinum (12.0 x 6.0cm), involving the large vessels of the mediastinum and reducing the amplitude of the superior vena cava (Figures 1 and 2). Laboratory tests found asymptomatic hyponatremia (Na: 118), suggesting SIADH.

The patient was evaluated by thoracic surgery, which considered the tumor unresectable and performed diagnostic incisional biopsy on

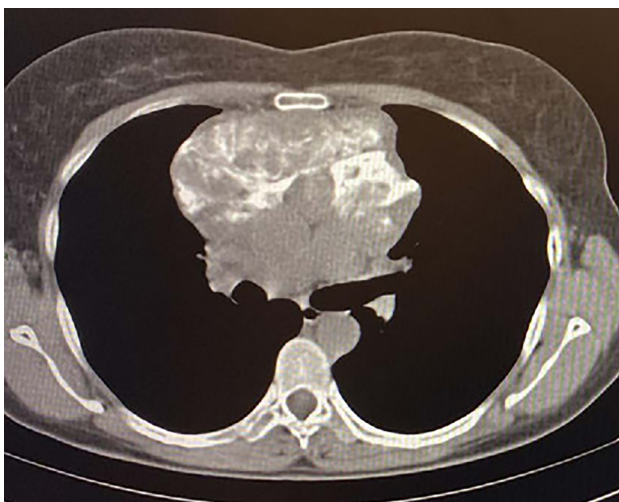


Figure 1. Anterior mediastinal mass on chest tomography (mediastinal window).

10/16/2020. Pathological anatomy revealed small cell neoplasia in fibrillar matrix with histopathological picture suggestive of neurogenic neoplasia (Figure 3). Immunohistochemistry (IM) was consistent with the diagnosis of neuroblastoma (Table 1).

The staging was performed with abdominal tomography and bone scintigraphy, which did not show lesions suggestive of metastasis.

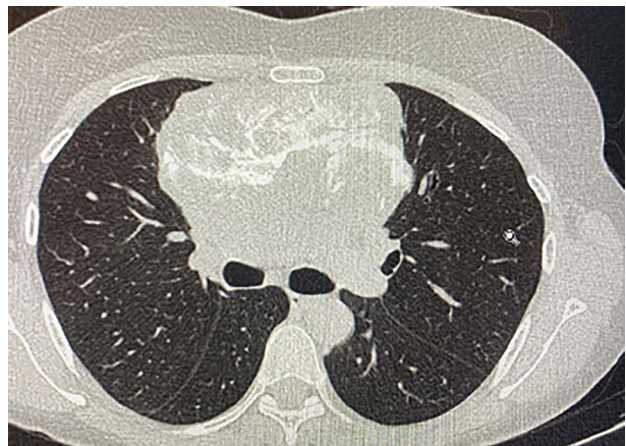


Figure 2. Anterior mediastinal mass on chest tomography (pulmonary window).

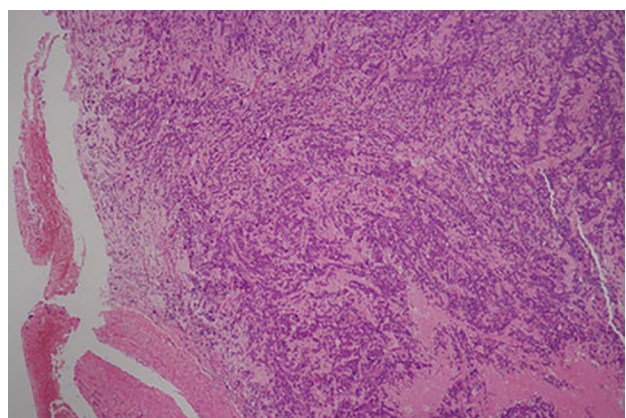


Figure 3. Neuroblastoma microscopy in smallest increase (HE): small cell neoplasm in fibrillar matrix with probable neurogenic origin.

Table 1. Immunohistochemical markers.

IMMUNOHISTOCHEMICAL MARKERS	RESULTS
AE1/AE3	Negative
CK5/6	Negative
CK4	Negative
Ki67	20%
CD56	Positive
Cromogranina	Positive
Sinaptofisina	Positive
Enolase	Positive
S100	Positive
CD99	Negative

It was chosen to perform neoadjuvant chemotherapy, with subsequent radiological reassessment, in order to possible future surgical resection. The patient underwent a polychemotherapy regimen (doxorubicin, cisplatin, cyclophosphamide, and vincristine) for 6 cycles

from December 2020 to April 2021, with excellent tolerance.

Radiological oncological restaging showed a partial response, with reduction of the dimensions of the mediastinal mass to 9.7 x 8.5 x 5.8cm. However, after the reassessment of thoracic surgery, it was still considered an unresectable neoplasm due to the invasion of large mediastinal vessels. Hyponatremia improved during neoadjuvant chemotherapy, corroborating the hypothesis of paraneoplastic SIADH (Na: 118 -> 125 -> 128 -> 129).

Opted for neoadjuvant radiotherapy, still in order to achieve resectability. He received radiotherapy from June to July 2021, with a total dose of 36Gy divided into 20 fractions. Chest tomography after 2 months of the end of radiotherapy, in September 2021, showed tumor reduction to 7.6 x 7.5 x 5.7 cm (Figure 4).

The patient was reevaluated again by thoracic surgery, which considered resection possible. She underwent thoracic surgery in March 2022. The anatomopathological of the surgery confirmed neuroblastoma, with the effect of previous neoadjuvant treatment in 80% of the sample evaluated (only 20% of residual disease), without neoplasia in pericardium liquid.

Unfortunately, the patient died due to postoperative complications (refractory hypotension/septic shock) in April 2022.

DISCUSSION

Initially, the pathology was compatible with neoplasm of small cells in the fibrillar matrix of neurogenic origin. Immunohistochemistry was essential to confirm thymic neuroblastoma and rule out other differential diagnoses such as small cell carcinoma and thymoma/thymic carcinoma.

Oncological staging in this patient, was performed with CT scans and conventional bone scintigraphy.

The intention of chemotherapy and subsequently radiotherapy with make the tumor resectable (neoadjuvant treatments). The chemotherapy protocol of choice was the ADOC regimen of the University of Turin for thymomas,⁽²³⁾ because it contains medications with cytoreductive action in neuroblastoma described in the literature⁽²¹⁾ and acceptable tolerance in the adult population.

The patient in question demonstrated a good response to neoadjuvant treatment both chemotherapy and radiotherapy, evidenced by the partial response in radiological restaging examinations, and by the treatment effect (80%) in pathological anatomy of surgery. High dose chemotherapy and surgery can achieve minimal disease state in >50% of newly diagnosed older NB patients.⁽²¹⁾

This case report brings together, several particularities, that are rare: NB of anterior mediastinum/thymus, NB in adult, SIHAD associated with NB. For these three particularities together, the literature review is scarce and is limited to case reports.⁽²⁴⁻²⁶⁾

The improvement in hyponatremia that occurred during neoadjuvant treatment corroborates the possibility of a paraneoplastic syndrome (SIADH) (Figure 5).^(24,26)

Therapeutic strategies remain uncertain due to the scarcity of scientific studies of this neoplasm in this specific population, related to its rarity. Extrapolation of NB therapeutic strategies in children, with adaptation for the adult age group, aiming to improve tolerance, remains the main option in this context.

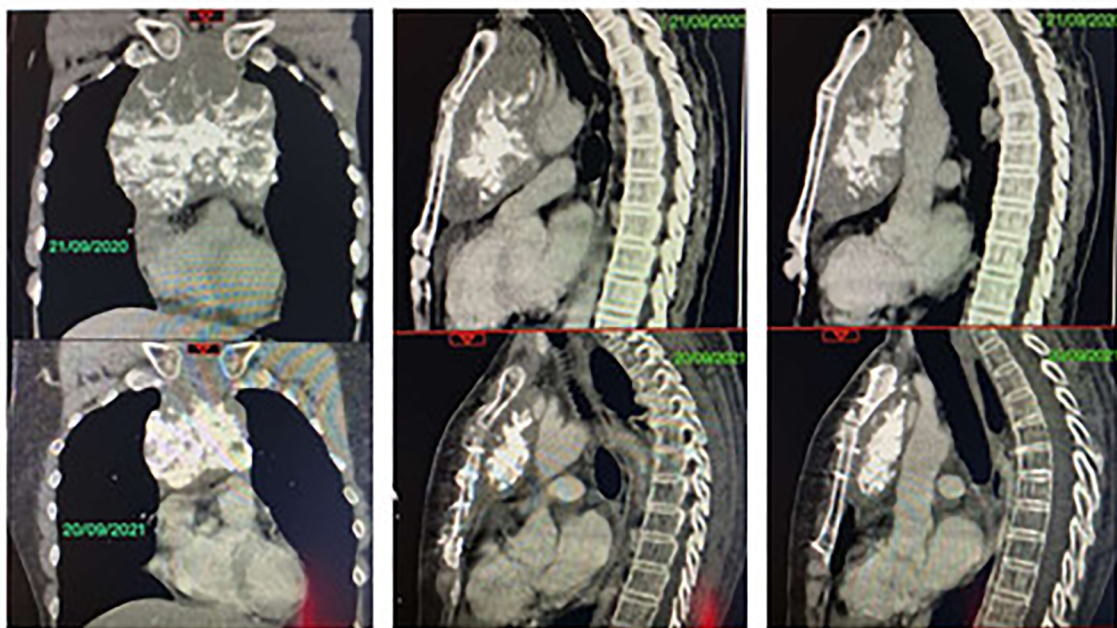


Figure 4. Comparison of tomographies before (above in 2020 year) and after (below in 2021 year) neoadjuvant treatment.

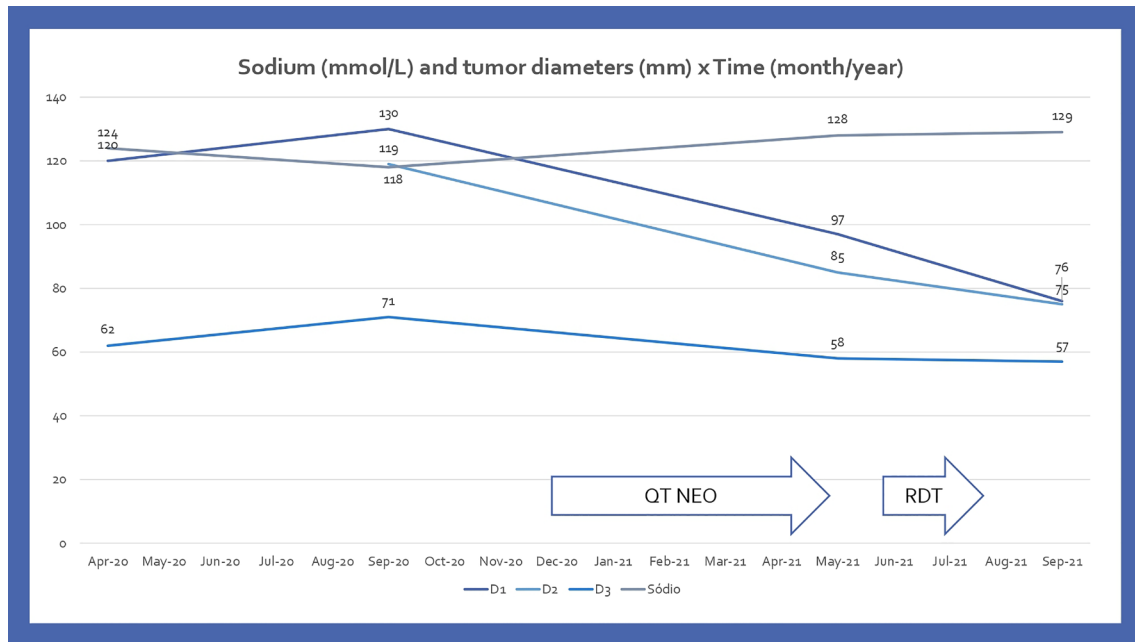


Figure 5. Sodium and tumor diameters throughout neoadjuvant treatment.

AUTHORS' CONTRIBUTIONS

CSS	Collection and assembly of data, Conception and design, Data analysis and interpretation, Final approval of manuscript, Manuscript writing, Provision of study materials or patient
CMBP	Collection and assembly of data, Conception and design, Data analysis and interpretation, Final approval of manuscript, Manuscript writing, Provision of study materials or patient
JSF	Collection and assembly of data, Conception and design, Data analysis and interpretation, Final approval of manuscript, Manuscript writing, Provision of study materials or patient
PRFA	Provision of study materials or patient
LCR	Provision of study materials or patient
JMN	Provision of study materials or patient
LOPS	Collection and assembly of data
CMSB	Collection and assembly of data
MOES	Collection and assembly of data
LCP	Collection and assembly of data
MSR	Collection and assembly of data

REFERENCES

- Rogowitz E, Babiker HM, Kanaan M, Millius RA, Ringenberg QS, Bishop M. Neuroblastoma of the elderly, an oncologist's nightmare: case presentation, literature review and SEER database analysis. *Exp Hematol Oncol*. 2014 Jul;3:20.
- Podda MG, Luksch R, Polastri D, Gandola L, Piva L, Collini P, et al. Neuroblastoma in patients over 12 years old: a 20-year experience at Instituto Nazionale Tumori of Milan. *Tumori*. 2010 Sep;96(5):684-9.
- Ministério da Saúde (BR). Tipos de câncer – câncer infantojuvenil [Internet]. Brasília (DF): Ministério da Saúde/INCA; 2023; [access in 2022 Nov 22]. Available from: www.inca.gov.br/tipos-de-cancer/cancer-infantojuvenil
- Esiashvili N, Goodman M, Ward K, Marcus Junior RB, Johnstone PAS. Neuroblastoma in adults: incidence and survival analysis based on SEER data. *Pediatr Blood Cancer*. 2007 Jul;48(1):41-6.
- Yanik F, Karamustafaoglu A, Yoruk Y. A rare mediastinal occurrence of neuroblastoma in an adult: case report. *São Paulo Med J*. 2019;137(1):104-6.
- Duan K, Dickson BC, Marrano P, Thorner PS, Chung CT. Adult-onset neuroblastoma: report of seven cases with molecular genetic characterization. *Genes Chromosomes Cancer*. 2020 Apr;59(4):240-8.
- Tolbert VP, Matthay KK. Neuroblastoma: clinical and biological approach to risk stratification and treatment. *Cell Tissue Res*. 2018 May;372(2):195-209.
- Newman E, Abdessalam S, Aldrink JH, Austin M, Heaton TE, Bruny J, et al. Update on neuroblastoma. *J Pediatr Surg*. 2019 Mar;54(3):383-9.
- Brisse H, McCarville MB, Granata C, Krug KB, Wootton-Gorges SL, Kanegawa K, et al. Guidelines for imaging and staging of neuroblastic tumors: consensus report from the International Neuroblastoma Risk Group Project. *Radiology*. 2011 Oct;261(1):243-57.

10. Vik TA, Pfluger T, Kadota R, Castel V, Tulchinsky M, Farto JCA, et al. (123)I-mIBG scintigraphy in patients with known or suspected neuroblastoma: Results from a prospective multicenter trial. *Pediatr Blood Cancer*. 2009 Jul;52(7):784-90.
11. Taggart D, Han MM, Quach A, Groshen S, Ye W, Villablanca JG, et al. Comparison of iodine-123 metaiodobenzylguanidine (MIBG) scan and 18Ffluorodeoxyglucose positron emission tomography to evaluate response after iodine-131 MIBG therapy for relapsed neuroblastoma. *J Clin Oncol*. 2009 Nov;27(32):5343-9.
12. Monclair T, Brodeur GM, Ambros PF, Brisse HJ, Cecchetto G, Holmes K, et al. The International Neuroblastoma Risk Group (INRG) staging system: an INRG Task Force report. *J Clin Oncol*. 2009 Jan;27(2):298-303.
13. Shimada H, Ambros IM, Dehner LP, Hata J, Joshi VV, Roald B, et al. The International Neuroblastoma Pathology Classification (the Shimada system). *Cancer*. 1999 Jul;86(2):364-72.
14. Nakagawara A, Li Y, Izumi H, Muramori K, Inada H, Nishi M. Neuroblastoma. *Jpn J Clin Oncol*. 2018 Mar;48(3):214-41.
15. Tan B, Li JF, Li WS, Yang RL. Primary thoracic neuroblastoma in an adult. A rare case report. *Medicine (Baltimore)*. 2019 Jul;98(30):e16564.
16. Perez CA, Matthay KK, Atkinson JB, Seeger RC, Shimada H, Haase GM, et al. Biologic variables in the outcome of stages I and II neuroblastoma treated with surgery as primary therapy: a children's cancer group study. *J Clin Oncol*. 2000 Jan;18(1):18-26.
17. Bernardi B, Mosseri V, Rubie H, Castel V, Foot A, Ladenstein R, et al. Treatment of localised resectable neuroblastoma. Results of the LNESG1 study by the SIOP Europe Neuroblastoma Group. *Br J Cancer*. 2008 Oct;99(7):1027-33.
18. Matthay K, Perez C, Seeger RC, Brodeur GM, Shimada H, Atkinson JB, et al. Successful treatment of stage III neuroblastoma based on prospective biologic staging: a Children's Cancer Group study. *J Clin Oncol*. 1998 Apr;16(4):1256-64.
19. Haas-Kogan D, Swift PS, Selch M, Haase GM, Seeger RC, Gerbing RB, et al. Impact of radiotherapy for high-risk neuroblastoma: a Children's Cancer Group study. *Int J Radiat Oncol Biol Phys*. 2003 May;56(1):28-39.
20. Matthay K, Reynolds CP, Seeger RC, Shimada H, Adkins ES, Haas-Kogan D, et al. Long-term results for children with high-risk neuroblastoma treated on a randomized trial of myeloablative therapy followed by 13-cis-retinoic acid: a children's oncology group study. *J Clin Oncol*. 2009 Mar 1;27(7):1007-21.
21. Kushner BH, Kramer K, LaQuaglia MP, Modak S, Cheung NKV. Neuroblastoma in adolescents and adults: the Memorial Sloan-Kettering experience. *Med Pediatr Oncol*. 2003 Dec;41(6):508-15.
22. Shusterman S, London WB, Gillies SD, Hank JA, Voss SD, Seeger RC, et al. Antitumor activity of hu14.18-IL2 in patients with relapsed/refractory neuroblastoma: a Children's Oncology Group (COG) phase II study. *J Clin Oncol*. 2010 Nov;28(33):4969-75.
23. Berruti A, Borasio P, Gerbino A, Gorzegno G, Moschini T, Tampellini M, et al. Primary chemotherapy with adriamycin, cisplatin, vincristine and cyclophosphamide in locally advanced thymomas: a single institution experience. *Br J Cancer*. 1999 Nov;81(5):841-5.
24. Argani P, Erlandson RA, Rosai J. Thymic neuroblastoma in adults: report of three cases with special emphasis on its association with the syndrome of inappropriate secretion of antidiuretic hormone. *Am J Clin Pathol*. 1997 Nov;108(5):537-43.
25. Ueda Y, Omasa M, Taki T, Okabe R, Cho H, Shoji T, et al. Thymic neuroblastoma within a thymic cyst in an adult. *Case Rep Oncol*. 2012 May;5(2):459-63.
26. Pellegrino M, Gianotti L, Cassibba S, Brizio R, Terzi A, Borretta G. Neuroblastoma in the Elderly and SIADH: case report and review of the literature. *Case Rep Med*. 2012;2012:952645.