

# Stewart-Treves syndrome: a case report

## Síndrome de Stewart-Treves: relato de caso

Eloisa Fritsche<sup>1</sup>, Eduarda Fritsche<sup>1</sup>, Lucio Flavo Dalri<sup>1</sup>, Lais Cristine Nienkotter<sup>1</sup>

### ABSTRACT

Stewart-Treves syndrome is a very rare lymphangiosarcoma with a poor prognosis. It usually develops in female patients after mastectomy with axillary lymph node dissection and is associated with chronic lymphedema. Stewart-Treves angiosarcoma is described in less than 1% of all soft tissue sarcomas, of which 0.5% occur in radically mastectomized patients. The case reported below describes the diagnosis and treatment of Stewart-Treves syndrome, with an initial clinical presentation of cutaneous lesions characteristic of the syndrome, manifesting ipsilaterally 22 years after quadrantectomy and radical right lymphadenectomy with adjuvant radiotherapy, the reported patient achieved, extraordinarily, a 12-year survival, far beyond the cases published to date.

**Keywords:** Lymphangiosarcoma; Survival; Breast neoplasms.

### RESUMO

A síndrome de Stewart-Treves é um linfangiossarcoma muito raro com prognóstico ruim. Geralmente se desenvolve em pacientes do sexo feminino após mastectomia com dissecação linfonodal axilar e está associada à linfedema crônico. O angiossarcoma de Stewart-Treves é descrito em menos de 1% de todos os sarcomas de tecidos moles, dos quais 0,5% ocorrem em pacientes radicalmente mastectomizadas. O caso relatado a seguir descreve o diagnóstico e tratamento da síndrome de Stewart-Treves, com apresentação clínica inicial de lesões cutâneas características da síndrome, manifestando-se ipsilateralmente 22 anos após quadrantectomia e linfadenectomia radical direita com radioterapia adjuvante, o paciente relatado alcançou, extraordinariamente, uma sobrevivência de 12 anos, muito além dos casos publicados até o momento.

**Descritores:** Linfangiossarcoma; Sobrevivência; Neoplasias mamárias.

1. Unidavi - Centro Universitário para o Desenvolvimento do Alto Vale do Itajaí, Medical School - Rio do Sul - Santa Catarina - Brazil.

**Financial support:** No.

**Conflicts of interest:** No.

**Correspondence author:** Eloisa Fritsche.

E-mail: eloisa.fritsche@unidavi.edu.br / Alternative email, preferably institutional: eloisa.fritsche@unidavi.edu.br

**Received on:** Jan 04, 2023 | **Accepted on:** Mar 13, 2023 | **Published on:** Apr 26, 2023

**DOI:** <https://doi.org/10.5935/2526-8732.20230399>

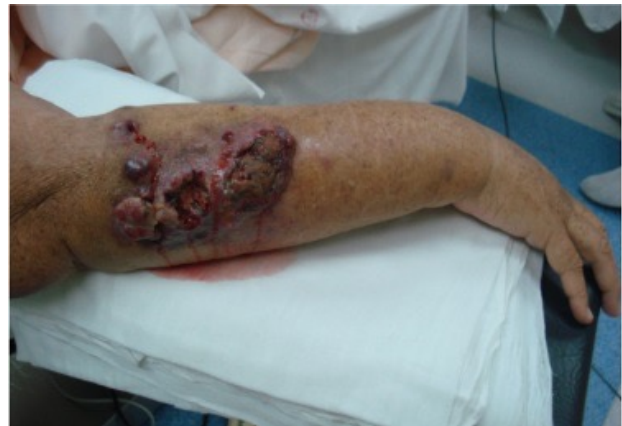## INTRODUCTION

Stewart-Treves syndrome, first described in 1948 by Fred Stewart and Norman Treves, is a rare and malignant pathology. It originates from vascular and lymphatic endothelial cells and is generally observed in post-mastectomy patients with axillary dissection, with submission to radiotherapy and consequent lymphatic stasis as a risk factor.<sup>(1)</sup> The age of greatest occurrence of Stewart-Treves syndrome is between 65 and 70 years, representing the predisposition to breast cancer and latency for the progression of chronic lymphedema.<sup>(2)</sup> Diagnosis is usually delayed, as previous lesions have features suggestive of traumatic ecchymosis, pyogenic granulomas or benign vascular proliferations. Early detection of lesions with subsequent biopsy and histopathological conclusion of Stewart-Treves lymphangiosarcoma is essential for a favorable outcome.<sup>(3)</sup> Although rare and difficult to diagnose, the poor prognosis and high lethality demonstrate the importance of studying this pathology, proving the need for an early diagnosis, rapid and aggressive therapy. The literature reports about 400 cases, of which 360 occurred after ipsilateral mastectomy, as far as we know, this is the only report that demonstrates a survival greater than 10 years developed in the context of five potentially fatal diseases of different neoplastic nature.

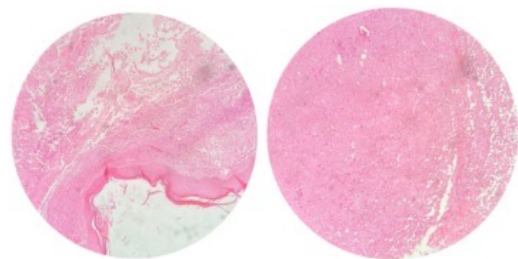
## CASE REPORT

Female, 68 years old, Caucasian, smoker, admitted to the hospital service in 2010, with extensive lymphedema in the right forearm, on physical examination it was noted a painful and extensive area of raised ulceration of a necrotic and hemorrhagic character (Figure 1). A biopsy was performed and the histopathological findings were compatible with Stewart-Treves angiosarcoma (Figure 2). The patient had a history of lung cancer, resection was performed and evolved satisfactorily in 2009. In addition, he underwent quadrantectomy and radical right lymphadenectomy performed 22 years earlier, in adjuvant chemotherapy and radiotherapy at the intervention sites.

Berger's surgery (Figure 3) was the viable therapeutic choice for the Stewart-Treves angiosarcoma described in this report. Preoperatively, in addition to laboratory tests, computed tomography (CT) was requested, which revealed alterations in the coronal section of the right part of the upper limb, showing subcutaneous lymphedema throughout the limb. The surgery was successfully performed and without complications, in the postoperative period, maintenance dressings were applied to the surgical wound, progressing satisfactorily (Figure 4), and the patient was discharged 25 days after the therapeutic approach. The surgical specimen was sent to the anatomopathologist showing margins of surgical resection of the specimen, skin and dorsal muscle fragments free of neoplasia, proximal stump showing vascular and neural structures free of involvement



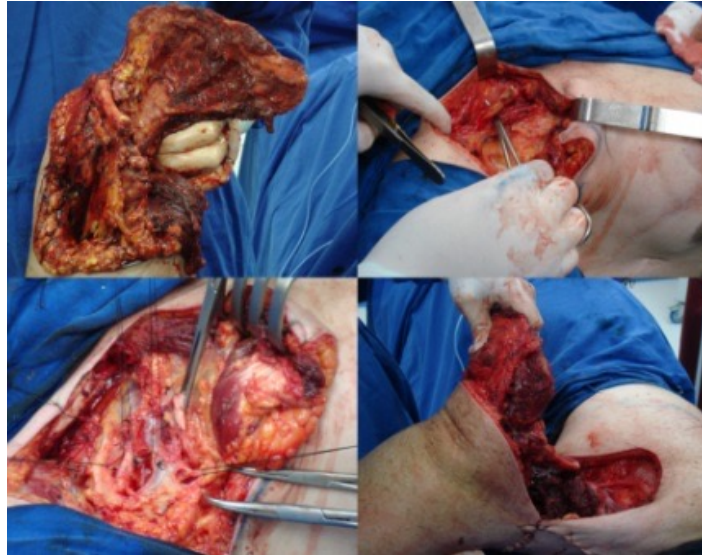
**Figure 1.** Cutaneous lesion showing erythematous plaque with coalescing, purple, bullous, and easily bleeding lesions on the right forearm, surrounded by satellite blood blisters, showing diffuse edema.



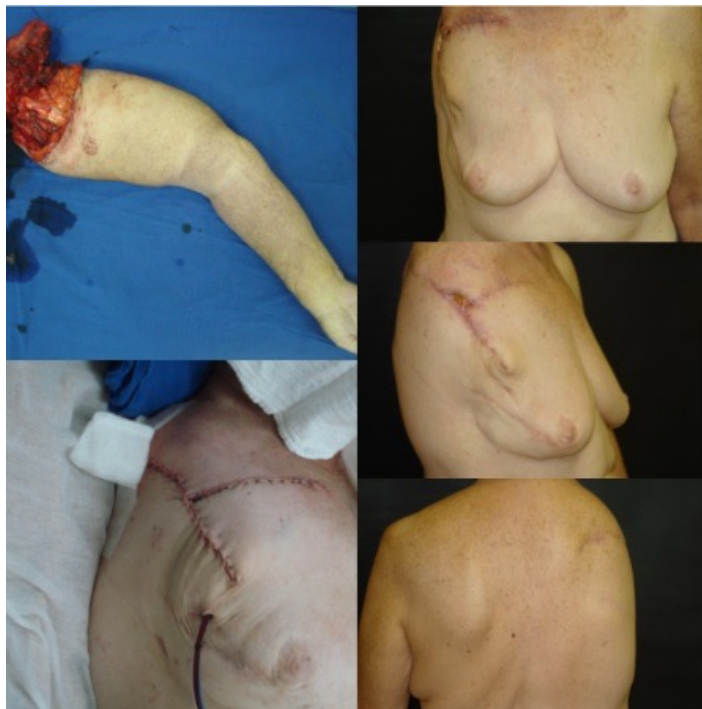**Figure 2.** Microscopy shows a malignant tumor of fusiform, hyperchromatic, high-grade pleomorphic endothelial cells with formation of vascular channels and extravasation of red blood cells at the dermal-subcutaneous junction.

and presence of metastasis in a lymph node classified as subclavicular. In addition, the patient underwent control CT every 4 months in the first year after surgery for evaluation and follow-up, after the first year every 6 months.

In 2017, the patient was hospitalized with heterogeneous complications, of a renal nature classified as chronic kidney disease stage IIIa, and cardiac, characterized by paroxysmal atrial fibrillation, being controlled with clinical measures within the hospital environment and discharged with drug treatment. In the year 2020, the patient returns with complaints of nausea and weight loss, performing multiple biopsies, being diagnosed with esophageal cancer, obtaining a complete response to radiotherapy and gastrostomy with adjustments and changes throughout her life. In 2022, the patient is diagnosed with a new malignant neoplasm in the left breast, requiring hospitalization, as she is a smoker and has chronic obstructive pulmonary disease, she had complications that prevented her from having the surgery to remove the neoplastic nodule, evolving with pneumonia and subsequent sepsis, which led the patient to death.



**Figure 3.** Resection of the entire upper limb and shoulder girdle, including the scapula and a portion of the clavicle.



**Figure 4.** A. Immediate postoperative period after Berger surgery, with drain; B. Surgical specimen removed in the Berger procedure; C-E. Late postoperative images of the Berger surgery, showing the healing and evolution of the procedure.

## DISCUSSION

Stewart-Treves syndrome (STS) is a highly rare, fatally aggressive condition with a poor prognosis, first described in 1948 by Fred Stewart and Norman Treves. The syndrome consists of a tumor originating from endothelial cells with a vascular component resembling a hemangiosarcoma and a lymphatic component resembling a lymphangiosarcoma,<sup>(1,2)</sup> develops due to failure in lymphatic drainage, which causes the storage of interstitial fluid and corroborates with lymphatic stasis, therefore, immunity collapses in a chronic course with malignant characteristics, affecting mainly the upper limbs, and the lesions

appear in descending order: arm, forearm, wrist and anterior thorax, and can generate metastasis in any organ, through the hematogenous route.<sup>(4)</sup>

The age of greatest occurrence of Stewart-Treves syndrome is between 65 and 70 years, representing the predisposition to breast cancer and latency for the progression of chronic lymphedema, and the incidence is 0.07%-0.45% after radical mastectomy. Although STS mostly develops after radical mastectomy, it can manifest as congenital or acquired lymphedema, related to trauma, filariasis, idiopathic lymphoma, venous stasis, morbid obesity, ulcerations in the lower limbs and invasion of the

inguinal region by a cervical or penile tumor. The risk of developing the syndrome increases by 15.9% when undergoing postoperative radiotherapy.<sup>(2)</sup>

In case of clinical suspicion of Stewart-Treves syndrome, surgical biopsy is essential to prove the disease and rule out other differential diagnoses, as was done in the present case. Currently, immunohistochemistry has been used to prove the epithelial nature of tumor cells.<sup>(3)</sup> Immunohistochemical study shows generally positive staining for endothelial cell markers such as antibodies against factor VIII, type IV collagen and CD31. Overexpression of c-MYC is essential for angiogenesis and is strongly related to secondary angiosarcoma,<sup>(5)</sup> in addition to alterations in the somatic deletion of the TP53 gene present in the immunodetection of the mutant p53 protein, related to DNA breakage induced by the irradiation of adjuvant therapy, corroborating with a worse prognosis and a more aggressive biological marker of soft tissue tumors.<sup>(3)</sup> Stewart-Treves syndrome has a poor prognosis, favoring local recurrence and distant metastasis, since after diagnosis survival is approximately 30 months, whereas in untreated patients survival decreases to 5-8 months.<sup>(2)</sup>

In the present case, it was possible to observe a 12-year evolution, much higher than what has been described so far, the patient's clinical condition and the interventions performed may have contributed to the favorable evolution and survival presented. Treatment possibilities have limited success, being individualized on a case-by-case basis, ranging from large resections, amputation or disarticulation, such as the Berger surgery,<sup>(7)</sup> being indicated in the condition of large tumors intimately connected to the main nerves or to the vascular supply of the upper limb, as is the case of Stewart-Treves syndrome.<sup>(6)</sup> Interscapulothoracic disarticulation is performed after anesthesia, intubation and bladder catheterization of the patient, the surgical technique consists of positioning the patient in total lateral decubitus, with a medial incision being made in the sternoclavicular joint, extending laterally along the clavicle and bending down towards the posterior axillary line. The upper part of the elliptical incision starts at the sternoclavicular joint, runs along the clavicle, then runs toward the supraclavicular region, posteriorly toward the acromion, and curves along the posterior axillary line to join the anterior incision. The dissection is exposed up to the level of the deep fascia, and an anterior flap is made showing the pectoralis major muscle that will be dissected to expose the pectoralis minor, after which the clavicular head of the sternocleidomastoid muscle is sectioned close to the clavicle, and then the clavicle is divided into its middle third. The large vessels and nerves that supply the dissected region are isolated, cut and ligated. With the surgeon located posterior to the patient, the incision is completed with a dorsal flap, exposing the muscle insertions of the trapezius and latissimus dorsi, then the levator scapulae and rhomboid muscles are sectioned and the suprascapular and transverse cervical vessels are isolated, sectioned and sutured. Finally, the

serratus anterior muscle is divided at its origin on the thoracic wall, completing the entire resection, obtaining bone, vascular, lymphatic limits and approximation by contiguity of the surgical specimen, thus justifying the need for scapulectomy.<sup>(7,8)</sup>

Chemotherapy therapy can be beneficial when there is a response to the first treatment, radiotherapy is reserved for patients with severe clinical instability or palliative and supportive conditions, the chemotherapy drugs used are: 5-fluorouracil, methotrexate, bleomycin and/or a combination of actinomycin D, vincristine, doxorubicin and cyclophosphamide.<sup>(3)</sup> Recent studies have demonstrated, through immunohistochemical staining of IL-23 and IL-17, the presence of IL-23 and IL-27 producing cells, important for tumor angiogenesis, in addition to promoting neoplastic advancement by blocking apoptosis, as well as attracting neutrophils and macrophages supporting the formation of cytokines and vascular endothelial growth factors in the injured tissue. This analysis provided innovation in the treatment of Stewart-Treves angiosarcoma, with the injection of Guselkumab, a monoclonal antibody directed at IL-23p19, which requires thorough investigation, but indicates a great therapeutic potential for the syndrome.<sup>(9)</sup>

## CONCLUSION

Clinical follow-up of patients who underwent mastectomy with axillary dissection, radioactive therapy or who had chronic lymphedema is essential, both for a preventive approach and for biopsy of suspicious lesions, corroborating a favorable outcome. In addition, research must be carried out to optimize treatment, aiming at less aggressive interventions and better quality of life for victims of Stewart-Treves syndrome.

## CONFLICT OF INTEREST

There is no conflict of interest.

## AUTHORS' CONTRIBUTIONS

EF	Collection and assembly of data, Conception and design, Data analysis and interpretation, Final approval of manuscript, Manuscript writing
EF	Data analysis and interpretation
LFD	Conception and design, Final approval of manuscript, Provision of study materials or patient
LCN	Final approval of manuscript

## REFERENCES

1. Wierzbicka-Hainaut E, Guillet G. Syndrome de Stewart-Treves (angiosarcome sur lymphœdème): complication rare du lymphœdème. *Presse Med.* 2010;39(12):1305-8.
2. Wang LL, Cui LF, Gao Y, Jiang ZC. Clinicopathologic features of Stewart-Treves syndrome. *Int J Clin Exp Pathol.* 2019 Mar;12(3):680-8.

3. Pereira ESP, Moraes ET, Siqueira DM, Santos MAS. Stewart-Treves syndrome. *An Bras Dermatol*. 2015;90(3 Suppl 1):229-31.
4. Mesli SN, Ghouali AK, Benamara F, Taleb FA, Tahraoui H, Abi-Ayad C. Stewart-Treves syndrome involving chronic lymphedema after mastectomy of breast cancer. *Case Rep Surg*. 2017;2017:1-4.
5. Sevil A, Aktas H, Ömer FE, Aktümen A, Erol H. Stewart Treves syndrome in a woman with mastectomy. *J Clin Diagn Res*. 2016;10(2):WD1-WD2.
6. Vieira LJ, Vieira JP, Oliveira AF, Freitas RR, Rabêlo FT, Mira RRL, et al. Tratamento cirúrgico de tumores malignos envolvendo ombro e membro superior: estudo de 10 casos. *Rev Bras Cancerol*. 2004;50(2):127-32.
7. Moraes JA, Reis TJCC, Napolini Filho H, Batista TP, Lucena MA. Amputação interescapulotorácica sob anestesia locorregional. *Rev Col Bras Cir*. 2013;40(5).
8. Khatri VP. Atlas de técnicas avançadas em cirurgia [Internet]. Rio de Janeiro: Grupo GEN; 2014; [access in 2022 Jul 20]. Available from: <https://integrada.minhabiblioteca.com.br/#/books/9788595153950/>
9. Esbeen LV, Rocket-Gravy PP. Improvement of Stewart-Treves angiosarcoma through interleukin 23p19 inhibition. *JAAD Case Rep*. 2021;17:84-6.