

Abscess-like postpartum metaplastic breast carcinoma in breastfeeding woman: a case report

Carcinoma metaplásico de mama pós-parto tipo abscesso em lactante: relato de caso

Bianca Gardini Ferrari¹, Gabriela Fiorentino da Silva¹, Marcela Martins Rodrigues¹, Rafaela Martins Rodrigues¹, Rafael da Silva Sá^{1,2}, Leandra Ernst Kerche¹

ABSTRACT

Introduction: Breast cancer diagnosed within 10 years of parturition is named postpartum breast cancer which is a highly metastatic tumor with poor prognosis. **Case Report:** A 31-year-old female presented with fever and painful mass in the left breast. She had undergone C-section 6 months ago of her second child. A left breast biopsy was performed and showed estrogen receptor-negative, progesterone receptor-negative, and human epidermal growth factor receptor 2 (HER2) negative invasive highly differentiated carcinoma. A radical mastectomy and left axillary lymphadenectomy were then performed and the anatomopathological report showed a 16cm metaplastic breast carcinoma. Eight months after the start of the chemotherapy treatment, the patient was diagnosed with brain metastases. **Discussion:** Postpartum breast cancer is associated with worse survival rates presenting increased risk of death. Metaplastic breast carcinoma is a subtype of triple-negative breast cancer also associated with poor prognosis and chemotherapy treatment resistant, being surgery the standard treatment.

Keywords: Lymphatic metastasis; Triple negative breast neoplasms; Inflammatory breast neoplasms.

RESUMO

Introdução: O câncer de mama diagnosticado até 10 anos depois do parto é chamado câncer de mama pós-parto, um tipo altamente metastático e com mau prognóstico. **Relato de Caso:** Mulher, 31 anos, se apresentou com febre e uma massa hiperêmica e dolorosa na mama esquerda. Ela havia passado por uma cesárea seis meses antes de seu segundo filho. Foi realizada uma biópsia na mama esquerda e a análise histológica e imunoistoquímica mostrou um carcinoma altamente diferenciado negativo para receptor de estrógeno, de progesterona e do fator de crescimento epidermal humano 2 (HER2). Mastectomia radical e linfadenectomia axilar esquerda foram realizadas e a análise anatomopatológica indicou um carcinoma metaplásico de mama de 16 cm. Oito meses depois do início da quimioterapia, a paciente foi diagnosticada com metástase cerebral.

Discussão: O câncer de mama pós-parto é associado a taxas ruins de sobrevida apresentando de duas a três vezes mais risco de morte. O câncer de mama metaplásico é também associado a um prognóstico ruim e a resistência ao tratamento quimioterápico, sendo a cirurgia o tratamento padrão.

Descritores: Metástase linfática; Neoplasias mamárias triplo negativas; Neoplasias inflamatórias da mama

1. UNOESTE, Medical School - Presidente Prudente - São Paulo - Brazil.

2. Regional Hospital of Presidente Prudente, Mastology - Presidente Prudente - São Paulo - Brazil.

Financial support: none to declare.

Conflicts of interest: The authors declare no conflict of interest relevant to this manuscript.

Correspondence author: Leandra Ernst Kerche.

E-mail: leakerche@gmail.com

Received on: November 27, 2022 | **Accepted on:** January 13, 2023 | **Published on:** February 2, 2023

DOI: <https://doi.org/10.5935/2526-8732.20230390>

 This is an open-access article distributed under the terms of the Creative Commons Attribution License.

INTRODUCTION

Breast cancer diagnosed within 10 years of parturition is named postpartum breast cancer (PPBC).¹ Normally, it has a highly metastatic nature and so the prognosis is poor.^{1,2} Some hypotheses have been raised about the remodeling of the breast tissue back to prepregnant state as an important cause of premalignant breast epithelial cells to adopt malignant properties.² This remodeling process is similar to wound healing, orchestrated by immune cell infiltration into the mammary gland.³

Extensive death of the mammary secretory tissue characterizes the postpartum involution, and this process is followed by repopulation of the gland with a stroma that is enriched with adipocytes and fibrous tissue.³ Since this process strikes similarities to pathologically tumor-promotional microenvironments, premalignant cells when exposed to the postpartum involution microenvironment have increased growth, invasion, and metastasis.⁴ Thus, young women diagnosed with breast cancer in the postpartum window have a near three-fold increased risk of death.²

The aim of this work is to report a case of a woman diagnosed with advanced postpartum metaplastic breast carcinoma that mimicked a breast abscess. This case report was submitted and approved by our local ethics committee under the CAAE 26050719.0.0000.5515.

CASE REPORT

A 31-year-old black previously health female was admitted at Porto Primavera State Hospital due to fever and hyperemic and slightly painful mass in the left breast. She had undergone a caesarean section 6 months ago of her second child. She had neither personal nor family history of cancer and was not treated for chronic diseases. Since the suspicion was of abscess, the mass was drained, and a clear and citrine secretion was obtained. She was then treated with oxacillin, cefazolin, and metronidazole for 6 days without any improvement of her condition.

An ultrasound was performed, and it showed a breast tumor of an irregular shape, suspicious for malignancy and it was scored 4B according to the breast imaging, reporting and data system (BI-RADS). She was then referred to Presidente Prudente Regional Hospital with the diagnostic hypothesis of breast cancer. Based on the results of palpation and breast ultrasound, a left breast biopsy and histological and immunohistochemistry analysis were performed to identify the type of the mass. The analysis showed estrogen receptor-negative (ER-), progesterone receptor-negative (PR-), and human epidermal growth factor receptor 2 (HER2) negative (HER2-) invasive highly differentiated carcinoma.

A left breast echography was performed and a voluminous heterogeneous mass with indistinct margins occupying the upper quadrant was visualized and classified as BI-RADS 6. A computed tomography (CT) was also performed, and it revealed the involvement of axillary lymph nodes on the left side.

No signs of distant metastatic disease were found being her clinical stage defined as T4dN1M0. Her blood count showed thrombocytosis and increased bilirubin, alkaline phosphatase, and gamma glutamyl transferase. She also underwent bone scintigraphy which was normal.

The patient had fever for 30 days since the admission and she was then accompanied by an infectologist. Therefore, she was unable to receive chemotherapy. Due to the accelerated growth of the tumor (Figure 1), a radical mastectomy and left axillary lymphadenectomy were then performed (Figures 2 and 3). She was discharged six days after the procedure in good general condition, discolored +/4+, jaundiced 2+/4+, breast with surgical wound in good aspect, without secretions or phlogistic signs.

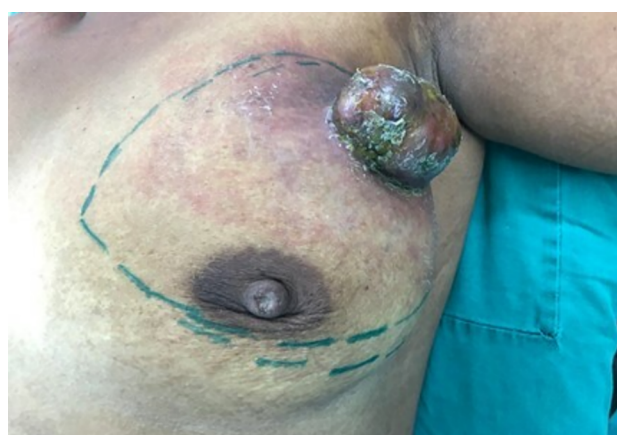

Figure 1. Abscess-like breast cancer before surgery.

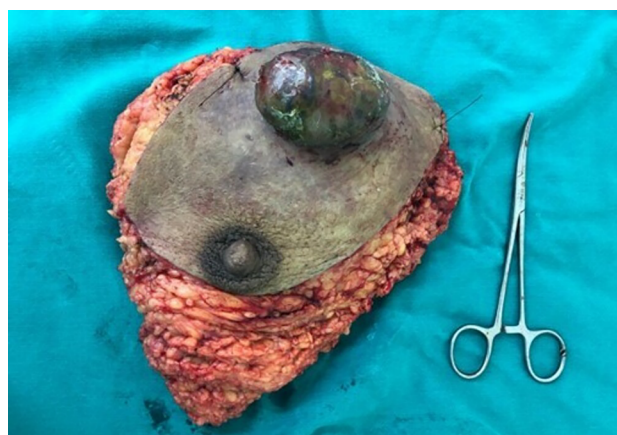

Figure 2. Surgically removed left breast showing a tumor simulating an abscess.

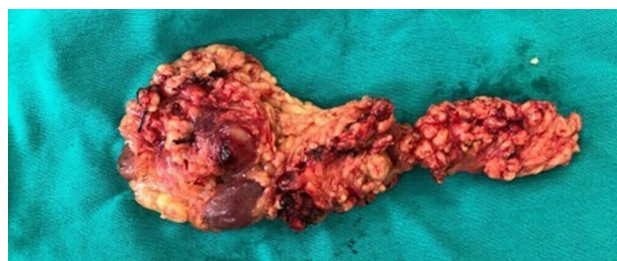


Figure 3. Surgically removed left axillary lymph nodes.

The anatomopathological report of the surgically extracted material showed a 16 cm metaplastic breast carcinoma with dystrophic microcalcification, angiolymphatic and perineural infiltration, extensive necrosis, and the presence of desmoplasia and inflammatory infiltrate. Six of the 46 dissected axillary lymph nodes presented metastatic cells. The patient then received chemotherapy consisting of adriamycin + cyclophosphamide followed by paclitaxel + carboplatin for 12 weeks.

At a follow-up physical examination, a lymph node was palpated at the right axillar region. A CT scan confirmed the presence of an axillary lymph node adjacent to the right pectoral measuring 1.6cm, in addition to a well-defined left perihilar mass measuring 2.6cm. Therefore, she underwent a transcutaneous biopsy of the right axillary lymph node, which confirmed infiltration by poorly differentiated carcinoma with extensive area of necrosis. With the progression of the disease, there was a change in treatment to first-line chemotherapy consisting of cisplatin + gemcitabine.

Eight months after the start of the chemotherapy treatment, the patient was admitted to the emergency room with a tonic-clonic seizure followed by left hemiparesis. CT and magnetic resonance imaging (MRI) of the skull were performed and it was possible to identify two solid-cystic expansive lesions (Figure 4A and 4B), predominantly peripheral, and the largest lesion measured 2.6cm x 2.4cm in the right parietal lobe. Neurology department contraindicated surgical treatment and radiotherapy was indicated followed by second-line chemotherapy with capecitabine.

In April 2020, during COVID-19 pandemic, she was admitted with flu symptoms and deep vein thrombosis that was confirmed by doppler ultrasound. During hospitalization, she was eupneic, presenting isochoric pupils, hypothermia and she was hemodynamically unstable in use of noradrenaline. The patient had a significant decrease in her saturation status, and she was submitted to orotracheal intubation.

She evolved with cardiorespiratory arrest and death was declared due to acute respiratory failure, without the results for coronavirus test.

DISCUSSION

Breast cancer is the most frequently diagnosed cancer in women worldwide and it still the leading cause of cancer-related deaths specially as a result of metastatic disease.⁵ Postpartum breast cancer (PPBC) represents about 50% of breast cancers in young women within 5 to 10 years of their last childbirth.⁶ Therefore, age at diagnosis, parity status and breastfeeding history are important risk factors for breast cancer.^{7,8}

PPBC is associated with worse survival rates presenting two-to threefold increased risk of death in both ER+ and ER-disease.^{6,9,10} Interestingly, studies have shown that diagnosis during pregnancy is not associated with poorer outcomes.^{11,12} These data combined implicate the existence of a postpartum event that could negatively impact the prognosis of breast cancer which could be associated with the weaning- induced breast involution, a developmental process that occur after the childbirth.¹¹

Rodent models have shown that this involution process is like tissue-remodeling programs that are activated during wound healing processes. In both murine and human mammary glands, postpartum involution begins with controlled apoptosis of mammary epithelial cells.⁷ In this process, a minority of mammary epithelial cells survives the death and resistance to cell deaths can probably play an important role in tumor initiation, as it results in the propagation of potentially harmful mutations that allow unregulated growth and division.¹³

In this case, the patient PPBC was diagnosed as metaplastic breast carcinoma (MBC) of high histological grade which is a subtype of triple-negative breast cancer and accounts for approximately 1% of all breast cancers.

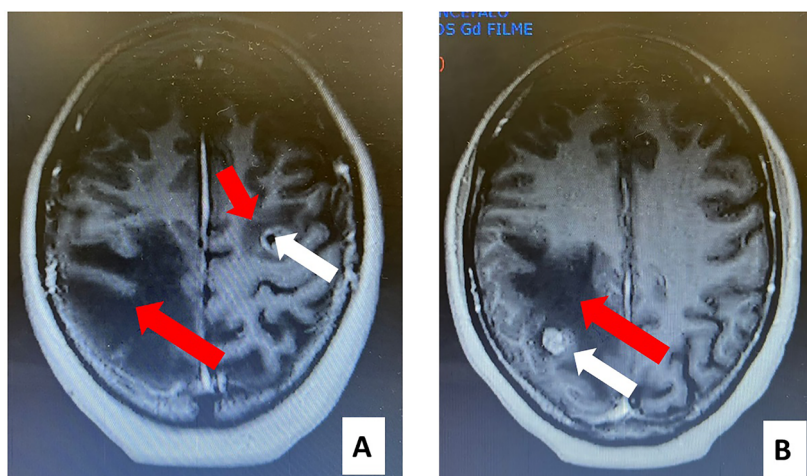


Figure 4. A. CT scan showing a mass at left temporal lobe (white narrow) and edema surrounding the mass and in the contralateral hemisphere (red narrows). B. CT scan showing a mass at right parieto-occipital lobe (white narrow) and edema surrounding the mass (red narrow). It is possible to visualize that the expansive effect of the mass determines regional erasure of sulcus and fissures without deviation of the centromedian structures.

They have unique pathologic characteristics since their glandular component is usually replaced by a nonglandular component such as chondroid, squamous or other lineages.^{14,15} Distant metastases are frequently found most in the brain and lungs.¹⁶

Molecular studies have showed that MBC undergo epithelial-mesenchymal transition (EMT) which involves the molecular and phenotype changes that characterize the conversion of immobile cancer epithelial cells into mobile mesenchymal cells.^{17,18} It has been shown that EMT is connected to poor prognosis and poor response to neoadjuvant therapy and radiotherapy in MBC. Therefore, surgery continues to be the standard therapy since MBC can be resistant to anthracyclines and taxanes, the two types of drugs used in triple negative breast cancers.¹⁸

In conclusion, we report a case of a postpartum breast cancer of a rare type, metaplastic breast carcinoma, that presented regional lymphatic and distant metastatic disease. This type of tumor is normally treatment resistant and usually diagnosed in a very advanced stage and size. The PPBC indicates alone poor prognosis and associated with the histological type of the tumor led our patient to a minimum risk of survival.

CONFLICT OF INTEREST

There is no conflict of interest.

AUTHORS' CONTRIBUTIONS

BGF	Collection and assembly of data, Data analysis and interpretation, Manuscript writing
GFS	Collection and assembly of data, Data analysis and interpretation, Manuscript writing
MMR	Collection and assembly of data, Data analysis and interpretation, Manuscript writing
RMR	Collection and assembly of data, Data analysis and interpretation, Manuscript writing
RSS	Conception and design, Provision of study materials or patient
LEK	Conception and design, Data analysis and interpretation, Final approval of manuscript, Manuscript writing

REFERENCES

- Goddard ET, Bassale S, Schedin T, Jindal S, Johnston J, Cabral E, et al. Association between postpartum breast cancer diagnosis and metastasis and the clinical feature underlying risk. *JAMA Netw Open*. 2019 Jan;2(1):e186997.
- Schedin P. Pregnancy-associated breast cancer and metastasis. *Nat Rev Cancer*. 2006 Apr;6(4):281-291.
- Martinson HA, Jindal S, Durand-Rougely C, Borges VF, Schedin P. Wound-healing like immune program facilitates postpartum mammary gland involution and tumor progression. *Int J Cancer*. 2015 Apr;136(8):1803-13.
- Lyons TR, O'Brien J, Borges VF, Conklin MW, Keely PJ, Eliceiri KW, et al. Postpartum mammary gland involution drives progression of ductal carcinoma *in situ* through collagen and COX-2. *Nat Med*. 2011 Aug;17(9):1109-15.
- World Health Organization (WHO). Breast cancer. Geneva: WHO; 2018.
- Callihan EB, Gao D, Jindal S, Lyons TR, Manthey E, Edgerton S, et al. Postpartum diagnosis demonstrates a high risk for metastasis and merits an expanded definition of pregnancy-associated breast cancer. *Breast Cancer Res Treat*. 2013 Apr;138(2):549-59.
- Lefrère H, Lenaerts L, Borges VF, Schedin P, Neven P, Amant F. Postpartum breast cancer: mechanisms underlying its worse prognosis, treatment implications, and fertility preservation. *Int J Gynecol Cancer*. 2021 Mar;31(3):412-22.
- Qiu R, Zhong Y, Hu M, Wu B. Breastfeeding and reduced risk of breast cancer: a systematic review and meta-analysis. *Comput Math Methods Med*. 2022 Jan;2022:1-9.
- Goddard ET, Bassale S, Schedin T, Jindal S, Johnston J, Cabral E, et al. Association between postpartum breast cancer diagnosis and metastasis and the clinical features underlying risks. *JAMA Netw Open*. 2019 Jan;2(10):e186997.
- Jindal S, Pennock ND, Sun D, Horton W, Ozaki MK, Narasimhan J, et al. Postpartum breast cancer has a distinct molecular profile that predicts poor outcomes. *Nat Commun*. 2021 Nov;12(1):6341-55.
- Amant F, Mickwitz G, Han SN, Bontenval M, Ring AE, Giermek J, et al. Prognosis of women with primary breast cancer diagnosed during pregnancy: results from an international collaborative study. *J Clin Oncol*. 2013 Jul;31(20):2532-9.
- Stensheim H, Møller B, Van Dijk T, Fosså SD. Cause-specific survival for women diagnosed with cancer during pregnancy or lactation: a registry-based cohort study. *J Clin Oncol*. 2009 Jan;27(1):45-51.
- Hanahan D, Weinberg RA. Hallmarks of cancer: the next generation. *Cell*. 2011 Mar;144(5):646-74.
- Oberman HA. Metaplastic carcinoma of the breast. A clinicopathologic study of 29 patients. *Am J Surg Pathol*. 1987 Dec;11(12):918-29.
- Rakha EA, Tan PH, Varga Z, Tse GM, Shaaban AM, Climent F, et al. Prognostic factors in metaplastic carcinoma of the breast: a multi-institutional study. *Br J Cancer*. 2015 Jan;112(2):283-9.
- Leyrer CM, Berriochoa CA, Agrawal S, Donaldson A, Calhoun BC, Shah C, et al. Predictive factors on outcomes in metaplastic breast cancer. *Breast Cancer Res Treat*. 2017 Oct;165(3):499-504.
- González-Martínez S, Pérez-Mies B, Pizarro D, Caniego-Casas T, Cortés J, Palacios
- Gooding AJ, Schiemann WP. Epithelial-mesenchymal transition programs and cancer stem cell phenotypes: mediators of breast cancer therapy resistance. *Mol Cancer Res*. 2020 Sep;18(9):1257-1270.