

Diagnosis of cancer of the cervix by targeting VPAC receptors on exfoliated cervical cells

Diagnóstico de câncer do colo do útero, visando receptores VPAC em células cervicais esfoliadas

Rajendra B. Nerli¹, Kumar Vinchurkar², Mahesh Kalloli², Shadab Rangrez¹, Shridhar C. Ghagane³, Madhukar L. Thakur⁴

ABSTRACT

Introduction: Cervical cancer is a major cause of cancer morbidity and mortality in women. Screening for cervical cancer reduces mortality through early detection and treatment. The success of the screening for cervical cancer has been largely attributed to the use of Pap smear (Papanicolaou). The objective of this study was to assess the feasibility of detecting cervical cancer by targeting genomic VPAC receptors and compare the results with those of Pap-test. **Material and Methods:** Women ≥ 40 years of age underwent routine screening for cervical cancer. The cellular material obtained from the cervix was gently smeared on a clean glass slide. The slides were then stained according to Papanicolaou's technique. Similarly, another set of prepared smears were used for VPAC receptor detection. Histopathological examination of the cervical biopsy was done and the results of all three tests were compared. **Results:** A total of 114 women attending the Gynaecology outpatient department of our hospital were included in the study. Histopathological examination (HPR) of the cervical biopsy revealed that 25 patients had cervical cancer and the remaining 89 were negative for cervical cancer. The Pap smear gave positivity for malignant cells in 20 (80%) of cases reconfirmed on HPR. The false positive rate and false negative rates were 4.5% and 20%, respectively. The VPAC receptors were positive in 23 (92%) of the 25 cases with cancer of the cervix. The false positive and false negative rates were 2.2% and 8%, respectively. **Conclusions:** Diagnosis of cancer of the cervix can be reliably made by targeting the genomic VPAC receptors. The test is simple to perform, reliable, reproducible and with minimal false positivity having a higher diagnostic accuracy.

Keywords: Diagnosis; Cervix uteri; Cancer symptoms.

1. JN Medical College, KLE Academy of Higher Education & Research (Deemed-to-be-University), Urology & Urologic-Oncology - Belagavi - Karnataka - India.
2. JN Medical College, KLE Academy of Higher Education & Research (Deemed-to-be-University), Department of Surgical-Oncology - Belagavi - Karnataka - India.
3. KAHERs Dr. Prabhakar Kore Basic Science Research Center, Department of Biotechnology - Belagavi - Karnataka - India.
4. Departments of Urology, Radiology, Thomas Jefferson University - Philadelphia, - PA, USA - United States.

Financial support: none to declare.

Conflicts of interest: The authors Madhukar L. Thakur has a conflict of interest towards the patented and patents pending product/TP4303 molecule that is mentioned in the manuscript and is important to the outcome of the study presented.

Correspondence author: Rajendra B. Nerli.

E-mail: rbnerli@gmail.com

Received on: October 21, 2022 | **Accepted on:** January 13, 2023 | **Published on:** March 2, 2023

DOI: <https://doi.org/10.5935/2526-8732.20230378>

RESUMO

Introdução: O câncer cervical é uma das principais causas de morbidade e mortalidade por câncer em mulheres. O rastreamento do câncer do colo do útero reduz a mortalidade por meio da detecção e tratamento precoces. O sucesso do rastreamento do câncer cervical tem sido amplamente atribuído ao uso do exame de Papanicolaou (teste de Papanicolaou). O objetivo deste estudo foi avaliar a viabilidade de detectar o câncer do colo do útero por meio de receptores VPAC genômicos e comparar os resultados com os do teste de Papanicolaou. **Material e Métodos:** Mulheres com idade igual ou superior a 40 anos foram submetidas à triagem de rotina para câncer cervical. O material celular obtido do colo do útero foi suavemente espalhado em uma lâmina de vidro limpa. As lâminas foram então coradas de acordo com a técnica de Papanicolaou. Da mesma forma, outro conjunto de esfregaços preparados foi usado para a detecção do receptor VPAC. O exame histopatológico da biópsia cervical foi feito e os resultados dos três testes foram comparados. **Resultados:** Foram incluídas no estudo 114 mulheres atendidas no ambulatório de Ginecologia do nosso hospital. O exame histopatológico (HPR) da biópsia cervical revelou que 25 pacientes tinham câncer cervical e os 89 restantes eram negativos para câncer cervical. O Papanicolaou deu positividade para células malignas em 20 (80%) dos casos reconfirmados em HPR. A taxa de falsos positivos e falsos negativos foi de 4,5% e 20%, respectivamente. Os receptores VPAC foram positivos em 23 (92%) dos 25 casos de câncer do colo do útero. As taxas de falso positivo e falso negativo foram de 2,2% e 8%, respectivamente. **Conclusões:** O diagnóstico de câncer do colo do útero pode ser feito de forma confiável visando os receptores VPAC genômicos. O teste é simples de realizar, confiável, reprodutível e com o mínimo de falsa positividade, apresentando maior precisão diagnóstica.

Descritores: Diagnóstico; Colo do útero; Sintomas de câncer.

INTRODUCTION

Cervical cancer is a major cause of cancer morbidity and mortality in women. When compared to developed countries, cervical cancer is a public health problem in developing countries like India, so much so that India alone accounts for one-quarter of the worldwide burden of cervical cancers.^[1,2] Cervical cancer accounts for 17% of all cancer deaths among women aged between 30 and 69 years, affecting approximately 1 in 53 Indian women during their lifetime compared with 1 in 100 women in more developed regions of the world.^[2]

It is well known that screening for cancer reduces mortality through early detection and treatment. However, there are two prerequisites for screening to reduce the rate of death from cancer. First, screening must advance the time of diagnosis of cancers that are destined to cause death. Second, early treatment of these cancers must confer some advantage over treatment at clinical presentation.^[3,4] Fortunately cervix can be subjected to screening for early diagnosis and treatment. However, despite availability of various cervical cancer screening methods, as well as a large burden of disease in India, there is no countrywide government-sponsored public health policy on

prevention of cervical cancer by either screening or vaccination or both.^[5] Bobdey et al. (2016)^[5] conducted a study to assess the burden of cervical cancer in India and review the performance characteristics of available cervical cancer screening tools. They searched MEDLINE and Web of Science electronic database from January 1990 to December 2015, using the keywords such as "cervical cancer", "screening", etc. They reported that cervical cancer contributed to approximately 6-29% of all cancers in women. The pooled estimates of sensitivity and specificity of visual inspection with acetic acid (VIA), magnified VIA, visual inspection with Lugol's iodine (VILI), cytology (Pap smear), and human papillomavirus DNA were found to be 67.65% and 84.32%, 65.36% and 85.76%, 78.27% and 87.10%, 62.11% and 93.51%, and 77.81% and 91.54%, respectively.

The success of the screening for cervical cancer has been largely attributed to the using the Papanicolaou smearing test (Pap-test). Cervical cancer is curable if detected early, and the 5-year survival rate is as high as 92%.^[6] The idea behind performing the Pap-test is that cellular changes that may develop into cancer are detected at such an early stage that they can be removed through a simple operation, thus preventing the cancer.

Many countries where the Pap-test is used in systematic, comprehensive screening programs have shown the importance of the Pap-test. In Sweden, the overall incidence of cervical cancer declined by 67% over a 40-year period, from 20 cases per 100,000 in 1965 to 6.6 cases per 100,000 women in 2005.^[7,8] In this paper we have studied the feasibility of detecting cervical cancer by targeting genomic VPAC (combined vasoactive intestinal peptide {VIP} and pituitary adenylate cyclase activating peptide {PACAP} family of cell surface receptors) receptors expressed on malignant cervical cancer cells that are shed in and around the cervix, and compared the results with those of conventional Pap-test.

MATERIAL AND METHODS

This prospective study was undertaken following permission granted by the Institutional/University ethical committee (KLESKF/IEC/2020/23). Women attending the Gynaecology outpatient department formed the potential study group. Women ≥ 40 years of age underwent routine screening for cervical cancer as a part of the departmental policy. Following clinical examination all women underwent speculum examination. It was ensured that no local douche, antiseptic cream was used on the day of test. The patient was placed in dorsal lithotomy position and a Cusco's bivalve speculum was introduced through vagina and cervix was visualized. The longer projection of the Ayre's spatula was placed in the cervix near squamo-columnar junction and rotated through 360°. The cellular material thus obtained was quickly, but gently smeared on a clean glass slide.

PAP staining:

The glass slide was then immediately put into the coplin jar containing 95% ethyl alcohol which acted as a fixative. The prepared smears were then stained according to Papanicolaou's technique. The cytological interpretation of the smears was made according to the New 2014 Bethesda system.

VPAC receptor staining:

Similarly, another set of prepared smears were used for VPAC receptor detection. The slides were fixed in 97% ethyl alcohol. TP4303 solution (0.5 μ g) was added to the cells to cover the entire cell area, approximately one cm in diameter. The slide was then

kept in dark, at 22°C for approximately 20 minutes and then thoroughly rinsed with deionized water and air dried. On the cells was then added, 20 μ L of 4,6 dimidino-2-phenylindole, dihydrochloride (DAPI, Fisher Scientific, PA) which strongly binds to A-T rich region of DNA in the cell nucleus. A coverslip was then placed and the slide was observed using a fluorescent microscope. Cells with TP4303 interaction presented themselves with dark orange fluorescence around the nucleus and thereby indicated the presence of VPAC receptor molecules around the cell surface. In the absence of VPAC receptors, only the DAPI bound cell nucleus was seen in dark blue. Normal epithelial cells that may only have minimal or no expression of VPAC therefore do not interact with TP4303 and show only cell nucleus.

Cervical Biopsy and HPR:

Samples for biopsy of the cervix was sent for histopathological examination.

Statistical analysis:

The data was collected and entered into Microsoft Excel-2019 and compared for descriptive statistics, frequency and percentage distribution. The variables were recorded and analysed for statistical significance using IBM SPSS statistics via software Inc., version 22.0.

RESULTS

During the study period September 2020 to November 2021, a total of 114 women attending the Gynaecology outpatient department of our hospital were included in the study. The symptoms of these patients were as shown in (Table 1). Clinical examination of the genital area revealed the findings as shown in (Table 2). Histopathological examination (HPR) of the cervical biopsy revealed that 25 patients had cervical cancer and the remaining 89 were negative for cervical cancer. Table 3 shows the details of the HPR, Pap smear and VPAC receptor positivity (Figure 1). Table 4 shows comparison of diagnostic accuracies of the two methods. The Pap smear was positive for malignant cells in 20 (80%) of the HPR proved cancer of cervix cases. The false positive rate and false negative rates were 4.5% and 20%. The VPAC receptors were positive in 23 (92%) of the 25 cases with cancer of the cervix. The false positive and false negative rates were 2.2% and 8%, respectively.

Table 1. Clinical symptoms.

No	Symptoms	Total (114)	Ca cervix (25)	Non-malignant (89)	p-value
1	Bleeding per vaginum	42(36.8%)	14 (56%)	28(31.5%)	0.015
2	Pelvic Pain	30(26.3%)	06 (24%)	24(27%)	
3	Weight loss	1 (0.9%)	01 (4%)	0 (0%)	
4	Abdominal pain	41 (36.0%)	04 (16%)	37(41.6%)	
	Total	114 (100%)	25 (100%)	89 (100%)	

Table 2. Genital examination findings.

No	SPECULUM FINDINGS	Total (114)	Ca cervix (25)	Non-malignant (89)	p-value
1	White discharge	23 (20.17%)	8 (32%)	15(16.85%)	0.041
2	Bloody discharge	37 (32.45%)	11 (44%)	26(29.21%)	
3	Foul smelling discharge	5 (4.38%)	2 (8%)	3(3.37%)	
4	Cervix inflamed	22 (19.29%)	2 (8%)	20(28.09%)	
5	Ulcers over cervix	27 (23.68%)	2 (8%)	25(28.09%)	
	Total	114 (100%)	25 (100%)	89 (100%)	

Table 3. Details of the PAP smear, HPR and VPAC receptor positivity.

No	Histopathology	Positive for carcinoma on Pap smear	VPAC receptor positivity
1	Positive for cervical cancer (25)	20 (80%)	23 (92%)
2	Negative for cancer (89)	85 (95.5%)	87 (97.8%)

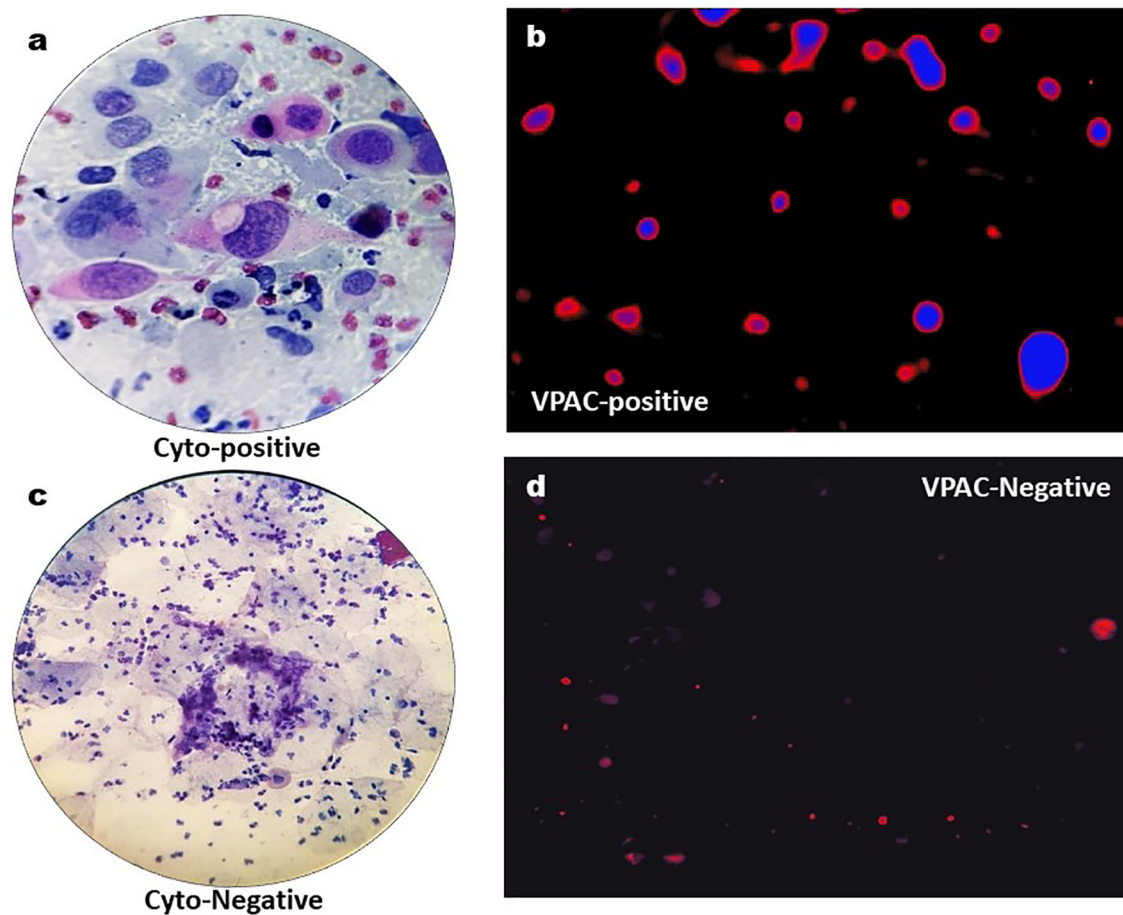


Figure 1. A. Cervical cytology shows pleomorphic keratinized squamous carcinoma and tadpole cells (Pap stain); B. VPAC receptor positive for malignancy; C. Cervical cytology shows normal epithelial cells with inflammation (Pap stain); D. VPAC receptor negative for malignancy.

Table 4. Association between VPAC receptor and PAP smear.

No	Histopathology	PAP positive for cancer	VPAC receptor positivity
1	Positive predictive value	83.33%	92%
2	Negative predictive value	94.44%	97.75%
3	Accuracy	92.11%	96.49%

DISCUSSION

Cancer of the uterine cervix is the second most common cancer among women world-wide. In India this is the commonest cancer among women and this country has the largest burden of cervical cancer patients in the world. One out of every five women in the world suffering from this disease belongs to India. More than three-fourths of these patients are diagnosed at advanced stages leading to poor prospects of long-term survival and cure.^[9] Regular population-based screening using Pap smear cytology is the internationally accepted screening method for cervical cancer. The health infrastructure and organizational aspects for a such a screening programme based purely on the Pap smear is currently not available in India.^[9]

Better understanding of human diseases at the cellular and molecular levels has paved the way for development of several novel life-sciences technologies. Identification of circulating tumour cells (CTC) in human blood and/or body fluids is one. Currently the CTC-associated liquid biopsy approach has drawn considerable attention and is rapidly getting incorporated into clinical applications.^[10] The human VPAC1 receptor, named for the combined vasoactive intestinal peptide (VIP) and pituitary adenylate cyclase-activating peptide (PACAP) family of cell surface receptors, are known to encode a G protein-coupled receptor that recognizes with high affinity both VIP- and PACAP-related peptides. Over the past few years, Thakur et al.^[11-14] have targeted VPAC1 genomic receptors that are overexpressed on the surface of malignant cells at the onset of cancers such as those of the breast, prostate, and lung.^[11-14]

It has been hypothesized that malignant cells shed in body fluids could be imaged optically, by targeting the VPAC1 receptors with the same peptide labelled with a fluorophore. Trabulsi et al. (2017)^[15] were able to detect VPAC positive cells in 98.6% of the men with a prostate cancer diagnosis (141), and none of the 10 men with benign prostatic hyperplasia. They further concluded that their preliminary data was highly encouraging and warranted further evaluation of the assay so as to serve as a simple and reliable tool to detect prostate cancer non-invasively. Similarly, Nerli et al. (2021)^[16] assessed the feasibility of detecting cancer of the prostate using voided urine sample and targeting the genomic VPAC receptors expressed on malignant PCa cells. All the 33 patients with prostatic adenocarcinoma were positive for malignant markers, and negative in the 32 patients with benign histology. VPAC-expressing genomic receptors have been shown to be expressed on the cell surface.^[15] The VPAC genomic biomarker belongs to the superfamily of G-protein-coupled surface receptors, which are expressed in high density (10^4 - 10^5 /cell) at the onset of oncogenesis, and prior to the alterations in cell morphology.^[17,18] VPAC1 receptors are minimally present on stroma, normal cells and benign masses.^[20]

CONCLUSION

This study shows that VPAC receptor positivity for cancer of cervix is good alternative to PAP staining. The study is highly sensitive with very low false negativity and false positivity rate. The diagnosis is highly reliable similar to Pap staining and can be utilized in an OPD setting. Our study is a preliminary study with a small study population. Our study needs to be validated by multicentric and randomized trials.

AUTHORS' CONTRIBUTIONS

RBN	Conception and design, Data analysis and interpretation, Final approval of manuscript, Manuscript writing.
KV	Collection and assembly of data, Final approval of manuscript, Provision of study materials or patient.
MK	Collection and assembly of data, Final approval of manuscript, Provision of study materials or patient.
SR	Final approval of manuscript, Provision of study materials or patient.
SCG	Data analysis and interpretation, Final approval of manuscript, Manuscript writing, Provision of study materials or patient.
MLT	Conception and design, Data analysis and interpretation, Final approval of manuscript, Provision of study materials or patient.

REFERENCES

1. Ferlay J, Soerjomataram I, Ervik M, Dikshit R, Eser S. GLOBOCAN 2012: estimated cancer incidence, mortality and prevalence worldwide in 2012 v1. Lyon: International Agency for Research on Cancer; 2013.
2. Institute for Health Metrics and Evaluation (IHME). The challenge ahead: progress in breast and cervical cancer [Internet]. Seattle: IHME; 2011; [access in YEAR Mo Day]. Available from: https://www.healthdata.org/sites/default/files/files/policy_report/2011/TheChallengeAhead/IHME_ChallengeAhead_Overview.pdf
3. Morrison AS. Screening in chronic disease. 2nd ed. New York: Oxford University Press; 1992.
4. Welch HG, Black WC. Evaluating randomized trials of screening. *J Gen Intern Med.* 1997;12(2):118-24.
5. Bobdey S, Sathwara J, Jain A, Balasubramaniam G. Burden of cervical cancer and role of screening in India. *Indian J Med Paediatr Oncol.* 2016 Oct/Dec;37(4):278-85.
6. Saslow D, Solomon D, Lawson HW, Killackey M, Kulasingam SL, Cain J, et al. American Cancer Society, American Society for Colposcopy and Cervical Pathology, and American Society for Clinical Pathology screening guidelines for the prevention and early detection of cervical cancer. *Am J Clin Pathol.* 2012;137:516-42.

7. Andrae B, Kemetli L, Sparen P, Silfverdal L, Strander B, Ryd W, et al. Screening-preventable cervical cancer risks: evidence from a nationwide audit in Sweden. *J Natl Cancer Inst.* 2008 May;100(9):622-9.
8. Andrae B, Andersson ML, Lambert PC, Kemetli L, Silfverdal L, Strander B, et al. Screening and cervical cancer cure: Population based cohort study. *Br Med J.* 2012;344(7849):e900.
9. Government of India (IN). World Health Organization (WHO). Guidelines for Cervical Cancer Screening Programme (GCCS). New Delhi: Government of India-World Health Organization Collaborative Programme (2004-2005); 2006.
10. Cristofanilli M, Hayes DF, Budd GT, Ellis MJ, Stopeck A, Reuben JM, et al. Circulating tumor cells: a novel prognostic factor for newly diagnosed metastatic breast cancer. *J Clin Oncol.* 2005 Mar;23(7):1420-30.
11. Thakur ML, Zhang K, Berger A, Cavanaugh B, Kim S, Channappa C, et al. VPAC1 receptors for imaging breast cancer: a feasibility study. *J Nucl Med.* 2013 Jul;54(7):1019-25.
12. Tripathi SK, Trabulsi EJ, Gomella L, Kim S, McCue P, Intenzo C, Birbe R, et al. VPAC1 targeted ⁶⁴Cu-TP3805 PET imaging of prostate cancer: preliminary evaluation in man. *Urology.* 2016;31:29-36.
13. Thakur ML, Aruva M, Garipey J, Acton P, Rattan S, Prasad S, et al. PET imaging oncogene overexpression using ⁶⁴Cu- VIP analog: comparison with ^{99m}Tc- VIP analog. *J Nucl Med.* 2004 Aug;45(8):1381-9.
14. Thakur ML, Devadhas D, Zhang K, Pestell RG, Wang C, McCue P, et al. Imaging spontaneous MMTVneu transgenic murine mammary tumors: targeting metabolic activity versus genetic products. *J Nucl Med.* 2010 Jan;51(1):106-11.
15. Trabulsi EJ, Tripathi SK, Gomella L, Solomides C, Wickstrom E, Thakur ML. Development of a voided urine assay for detecting prostate cancer non-invasively: a pilot study. *BJU Int.* 2017 Jun;119(6):885-95.
16. Nerli RB, Ghagane SC, Bidi SR, Thakur ML, Gomella L. Voided urine test to diagnose prostate cancer: preliminary report. *CytoJournal.* 2021;18:26.
17. Reubi JC, Laderach U, Waser B, Gebbers JO, Robberecht P, Laissue JA. Vasoactive intestinal peptide/pituitary adenylate cyclase-activating peptide receptor subtypes in human tumors and their tissues of origin. *Cancer Res.* 2000 Jun;60(11):3105-12.
18. Lelievre V, Pineau N, Waschek J. The biological significance of PACAP and PACAP receptors in human tumors from cell lines to cancer. Pituitary adenylate cyclase- activating polypeptide. In: Vaudry H, Arimura A, eds. *Endocrine updates.* New York: Springer-Verlag; 2003. v. 20. p. 361-99.
19. Zia H, Hida T, Jakowlew S, Birrer M, Gozes Y, Reubi JC, et al. Breast cancer growth is inhibited by vasoactive intestinal peptide, (VIP) hybrid, a synthetic VIP receptor antagonist. *Cancer Res.* 1996 Aug;56(15):3486-9.
20. Leyton J, Gozes Y, Pisegna J, Coy D, Purdom S, Caibang M, Zia F, et al. PACAP (6-38) is a PACAP receptor antagonist for breast cancer cells. *Breast Cancer Res Treat.* 1999 Jul;56(2):177-86.