


Delayed and sequential hemolytic uremic syndrome as a complication of Gemcitabine therapy

Síndrome hemolítico-urêmica tardia e sequencial como complicação da terapia com gemcitabina

Thaís Sampaio Corrêa de Almeida¹, Renata Colombo Bonadio¹, Rafaela Lopes da Silva Naves¹, Paulo Henrique Amor-Divino¹, Paulo Marcelo Gehm Hoff¹

ABSTRACT

Gemcitabine is a widely used drug in the treatment of diverse malignancies and its use has been approved by the US Food and Drug Administration. This drug has been associated with a rare adverse event, the Hemolytic Uremic Syndrome (HUS), characterized by acute kidney injury, microangiopathic hemolytic anemia, and thrombocytopenia. The purpose of this report is to draw attention to an atypical manifestation of this severe and unusual complication, and discuss its management and outcome. We report a 70-year-old woman with Li-Fraumeni syndrome diagnosed with pancreatic adenocarcinoma and leiomyosarcoma, whom after fourteen cycles of therapy with gemcitabine and nab-paclitaxel, with good disease control, developed clinical manifestation of atypical HUS with exuberant pulmonary symptoms, followed by hemolytic anemia, and acute renal failure presenting on an unusual sequential fashion. The case highlights the importance of maintaining a high suspicion for SHU in patients receiving gemcitabine, being aware that delayed and atypical manifestations may occur.

Keywords: Pancreatic Neoplasms. Hemolytic-Uremic Syndrome. Drug Therapy.

RESUMO

A gencitabina é um fármaco amplamente utilizado no tratamento de diversas neoplasias e seu uso foi aprovado pelo FDA dos Estados Unidos desde 1994. Esse fármaco tem sido associado a um evento adverso raro, a síndrome hemolítico-urêmica (SHU), caracterizada por lesão renal aguda, anemia hemolítica microangiopática e trombocitopenia. O objetivo deste relato é chamar a atenção para uma manifestação atípica dessa complicação grave e incomum e discutir seu manejo e desfecho. Relatamos o caso de uma mulher de 70 anos com síndrome de Li-Fraumeni diagnosticada com adenocarcinoma pancreático e leiomiossarcoma, que após quatorze ciclos de terapia com gencitabina e nab-paclitaxel, com bom controle da doença, desenvolveu manifestação clínica de SHU atípica com sintomas pulmonares exuberantes, seguido por anemia hemolítica e insuficiência renal aguda apresentando-se de forma sequencial incomum. O caso destaca a importância de manter uma alta suspeita de SHU em pacientes que recebem gencitabina, estando ciente de que podem ocorrer manifestações tardias e atípicas.

Descritores: Neoplasias pancreáticas; Síndrome hemolítico-urêmica; Terapia medicamentosa.

1. Instituto D'Or de Pesquisa e Ensino (IDOR), São Paulo, Brazil, Clinical Oncology - São Paulo - São Paulo - Brazil

Financial support: none to declare.


Conflicts of interest: The authors declare no conflict of interest relevant to this manuscript.

Correspondence author: Thaís Sampaio Corrêa de Almeida.

E-mail: thaisscdalmeida@gmail.com

Received on: May 23, 2022 | **Accepted on:** June 10, 2022 | **Published on:** September 22, 2022

DOI: <https://doi.org/10.5935/2526-8732.20220353>

 This is an open-access article distributed under the terms of the Creative Commons Attribution License.

INTRODUCTION

Hemolytic uremic syndrome (HUS) is a rare syndrome characterized by renal failure, thrombocytopenia, and hemolytic anemia.^[1] It was first described in 1955 by Gasser et al.,^[2] in a pediatric patient who developed hemorrhagic diarrhea and enterocolitis related to *Escherichia coli* infection. This syndrome has high mortality rates of 10-40% and in some cases up to 60-70%.^[3] The first time HUS was described in an oncology patient as a result of antineoplastic agent was in 1979.^[4] Since then, several other chemotherapy agents and drugs have been associated with the development of HUS. Nowadays, HUS still a rare and severe disorder and its atypical variant correspond to a type of thrombotic microangiopathy (TMA) that carries a poor prognosis and is related to diverse causes including infectious disease, malignancy, connective tissue disease, pregnancy, hemolytic anemia, elevated liver enzymes, low platelet syndrome (HELLP syndrome), malignant hypertension and some kinds of drugs (bleomycin, cisplatin, gemcitabine, mitomycin C, tacrolimus, cyclosporine, anti-VEGF agents, interferon, etc.).^[5]

Gemcitabine is a pyrimidine analog, frequently used as chemotherapy agent for the treatment of a variety of malignancies, specially non-small cell lung cancer, pancreatic cancer, breast cancer, ovarian cancer, among others. Adverse effects can be multiple but the main ones include myelotoxicity and hepatorenal toxicity. Most recently, many cases of aHUS related to the use of gemcitabine have been described in literature, despite being an unusual complication with the incidence reported to be between 0.02% and 2.2%.^[6,7]

The exact presentation and treatment of this condition still unclear and also the difficulty in the diagnosis delays its treatment resulting in unsuccessful management of this condition. Given this, early recognition of atypical HUS related to gemcitabine is important, as prompt discontinuation of the drug and other therapies are essential to avoid complications such as end-stage renal disease or even death.

CASE REPORT

A 70-year-old woman with Li-Fraumeni syndrome (variant TP53 c.375G>A p.T125T.) had a diagnosis of metastatic pancreatic adenocarcinoma and leiomyosarcoma. The patient had previously received several systemic treatments with disease progression. She received intravenous infusion of nab-paclitaxel and gemcitabine at day 1 and day 8 every 21 days at the following doses: nab-paclitaxel at 110mg/m² and gemcitabine at 800mg/m², with a partial tumor response. Immediately after the 14th infusion of gemcitabine and nab-paclitaxel chemotherapy, she had an acute episode of dyspnea and hypoxemia. Vital signs revealed a blood pressure of 150x90mmHg, heart rate 82 beats/min, respiratory rate of 20 ipm and oxygen saturation of 78% on room air. Respiratory examination showed wheezing without other signs. Cardiac, neurological, abdominal, and limb examination showed no abnormalities.

She was hospitalized for two weeks, requiring oxygen support. A chest computed tomography angiogram showed a new discrete interstitial infiltration and stable lung nodules. Echocardiogram, BNP, and troponins showed no alterations. In a pandemic context, the patient was tested for COVID-19, which excluded the viral infection. After initiation of corticosteroids, she had a gradual improvement of the pulmonary symptoms. Despite that, some days after she progressed with a worsening of laboratory tests, with hemoglobin (Hgb) of 8.3g/dL (12.0-15.5g/dL), platelets of 53.000/mm³ (150.000-400.000/mm³). C3 and C4 levels were 130mg/dL (67-149mg/dL) and 41mg/dL (10-38mg/dL), respectively, lactate dehydrogenase (LDH) level was 490U/L (135-214U/L) and haptoglobin 15mg/dL (36-195mg/dL). Peripheral smear showed 1.2% schistocytes (2.1-14.9%). ADAMTS 13 level was 110% (68-163%).

Weeks after the initial symptoms, a rising serum creatinine (Cr) appeared - Cr of 2.14mg/dL (0.60-1.10mg/dL) reaching the level of 4.55mg/dL. Urine analysis showed pH 5.0 (5.0-8.0), proteins 0.75g/L (<0.10g/L), glucose 1.0mg/dL (<0.3g/L), nitrite negative, leucocytes 10.000/mL (<30.000/mL), erythrocytes 44.000/mL (<12.000/mL) and rare cylinders.

Diagnosis of a hemolytic uremic syndrome secondary to gemcitabine therapy (GiHUS) was suspected. Despite continuation of corticosteroids for 7 weeks, her renal function continued to deteriorate with a high content of proteins in urine analysis (proteins 3.46g/L) setting the criteria of nephrotic proteinuria. The renal biopsy showed glomerular lesions consistent with thrombotic microangiopathy, endarteritis obliterans, acute interstitial nephritis with eosinophils, focal acute tubular necrosis and arteriosclerosis, reinforcing the diagnosis of HUS (Figures 1 and 2).

Plasmapheresis was performed during 5 sessions with no improvement. She then received eculizumab (900mg 1x/week) for 5 weeks which resulted in significant improvement of hematological parameters. Also, her renal function did recover with no more need of hemodialysis (ESRD).

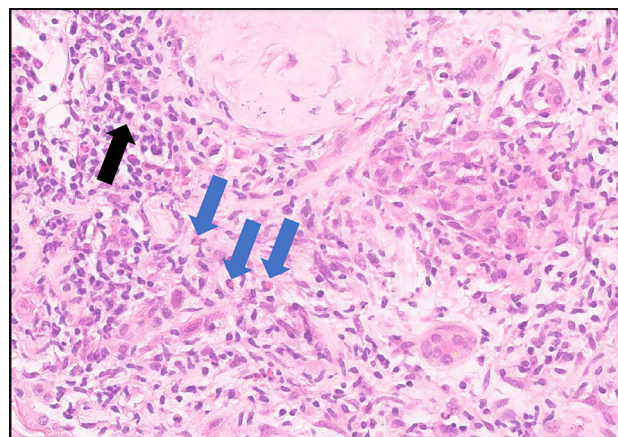


Figure 1. Interstitium dissociated by edema, fibrosis in a lymphocytic inflammatory infiltrate (black arrow) interspersed with eosinophils (blue arrows), present in more than 50% of the compartment.

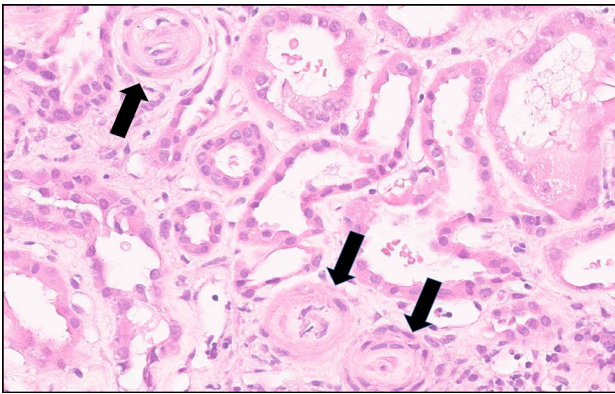


Figure 2. Black arrows point to endarteritis obliterans.

DISCUSSION

This case illustrates an uncommon presentation of hemolytic uremic syndrome secondary to gemcitabine therapy (GiHUS).

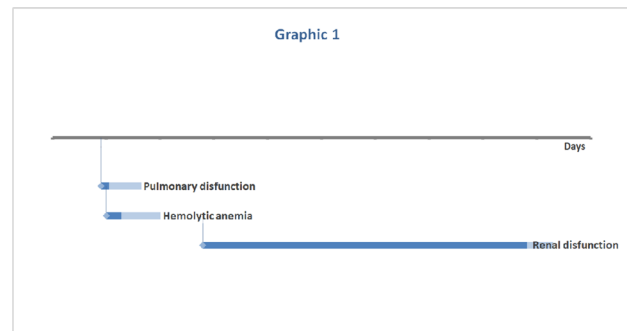
The first case of gemcitabine-related HUS (GiHUS) was reported by Casper et al. (1994)^[8] in a 55-year-old man with pancreatic adenocarcinoma after receiving gemcitabine treatment for a year. Currently, its incidence varies from 0.008% to 1.4% with an overall incidence of 0.015%, though many cases may be unrecognized because the first presentation as anemia can be confused with gemcitabine myelotoxicity.^[2,9,10] Also, it is noted to be more common in senior males what can reflect the natural incidence of the malignancies for which gemcitabine is used.^[11]

The exact pathophysiology of GiHUS still unclear, but it is suspected that complement activation leads to endothelial damage and subsequent platelet aggregation contributing to formation of thrombi.^[12,13] This theory is supported by the pathological findings of complement and immunoglobulin deposition in the endothelium.

The entity thrombotic microangiopathy (TMA) must present with microangiopathic hemolysis, thrombocytopenia and one or more of the following: neurological symptoms, renal impairment, or gastrointestinal symptoms. In case the patient develops neurologic features and abnormal ADAMTS13 activity associated with anemia and thrombocytopenia we can define the TMA as thrombotic thrombocytopenic purpura (TTP).^[14,15] Otherwise, if the syndrome presents with renal impairment and without neurologic symptoms we can say it is atypical hemolytic uremic syndrome. Therefore, hemolytic uremic syndrome (HUS) is defined by the triad of hemolytic anemia (hemoglobin <10g/dL) with fragmented erythrocytes (schizocytes), thrombocytopenia (platelets <150.000/mm³) and renal impairment (serum creatinine > upper limit of normal for age).

We describe here an atypical presentation of HUS and our purpose is to highlight an unusual and sequential presentation in this case that started with exuberant pulmonary symptoms and only weeks after the first symptoms evolved with other signs that could make us raise the hypothesis of aHUS caused by the gemcitabine, such as hemolytic anemia and renal dysfunction (Graphic 1).

Another point of this case, we would like to highlight is that besides the sequential clinical presentation, the clinical signs only appeared after the 14th infusion of the drug and usually, the patient develops symptoms at the first infusions of gemcitabine.



Graphic 1. Represents the duration of each clinical presentation in days.

There is currently no consensus on the gold-standard treatment for GiHUS. Usually, therapy of aHUS involves supportive care with attention to management of acute kidney injury and systemic complications. The most important step after diagnosing GiHUS is immediately discontinue gemcitabine.^[12,16-18] To reverse the condition, other modalities of treatment can be considered, such as plasmapheresis, corticosteroids, haemodialysis, and monoclonal antibodies.^[12,18] The role of plasmapheresis in the management of chemotherapy induced TMA had been questioned because about 50% of patients still progress to end stage renal disease (ESRD),^[4] requiring haemodialysis. Rituximab has also been used for the treatment of GiTMA.^[19,20]

Eculizumab is a novel C5 inhibitor recently approved by FDA for atypical HUS.^[13,21] However, its use in GiHUS has not been precisely defined yet.

Our patient demonstrated significant improvement in haematological parameters after initiation of eculizumab therapy and also showed improvement of renal dysfunction after the 5th dose of the medication. Therefore, the patient no longer needed renal replacement therapy confirming the success of treatment of this case, despite poor prognosis.

CONCLUSION

Physicians should maintain high suspicion for GiHUS, since early discontinuation of the drug and initiation of supportive therapies may importantly impact outcomes. In addition to renal dysfunction and blood alterations, other signs and symptoms related to microangiopathy may occur. In this case report, the first disease manifestations were pulmonary symptoms. Although no standard therapy is established for GiHUS, options include steroids, plasmapheresis, and rituximab. Another more recent option is eculizumab, an inhibitor of the complement C5 protein, with activity for aHUS but with its role in malignancy or chemotherapy induced HUS not well defined yet.

TRIAL REGISTRATION

This case report was submitted and approved for committee of ethic in research of *Hospital e Maternidade São Luiz*. Registration number: 5.414.155

CONFLICTS OF INTEREST

RCB: Speaker fees and/or honoraria for consultancy or advisory functions: AstraZeneca; Financial support for educational programs and symposia: AstraZeneca, Daichii-Sankyo; Institutional Research Funding: Novartis, AstraZeneca, GSK.

PHAD: Speaker fees and/or honoraria for consultancy or advisory functions: AstraZeneca.

FINANCIAL CONFLICT OF INTEREST

This research received no specific grant from any funding agency in the public, commercial, or not-for-profit sectors.

ACKNOWLEDGEMENTS

Not applicable.

REFERENCES

- Moake JL. Thrombotic microangiopathies. *N Engl J Med*. 2002 Aug;347(8):589-600.
- Gasser C, Gautier E, Steck A, Siebenmann RE, Oechslin R. Hemolytic-uremic syndrome: bilateral necrosis of the renal cortex in acute acquired hemolytic anemia. *Schweiz Med Wochenschr [Internet]*. 1955 Sep; [cited 2022 Apr 25]; 85(38-39):905-9. Available from: <https://pubmed.ncbi.nlm.nih.gov/13274004/>
- Saif MW, McGee PJ. Hemolytic-uremic syndrome associated with gemcitabine: a case report and review of literature. *J Pancreas [Internet]*. 2005 Jul; [cited 2022 Mar 28]; 6(4):369-74. Available from: <https://pubmed.ncbi.nlm.nih.gov/16006690/>
- Fung MC, Storniolo AM, Nguyen B, Arning M, Brookfield W, Vigil J. A review of hemolytic uremic syndrome in patients treated with gemcitabine therapy. *Cancer [Internet]*. 1999 May; [cited 2022 Mar 28]; 85(9):2023-32. Available from: <https://pubmed.ncbi.nlm.nih.gov/10223245/>
- Lee HW, Chung MJ, Kang H, Choi H, Choi YJ, Lee KJ, et al. Gemcitabine-induced hemolytic uremic syndrome in pancreatic cancer: a case report and review of the literature. *Gut Liver [Internet]*. 2014 Jan; [cited 2022 Apr 25]; 8(1):109-12. Available from: <https://pubmed.ncbi.nlm.nih.gov/24516709/>
- Fung MC, Storniolo AM, Nguyen B, Arning M, Brookfield W, Vigil J. A review of hemolytic uremic syndrome in patients treated with gemcitabine therapy. *Cancer [Internet]*. 1999 May; [cited 2022 Mar 28]; 85(9):2023-32. Available from: <https://pubmed.ncbi.nlm.nih.gov/10223245/>
- Desramé J, Duvic C, Bredin C, Béchade D, Artru P, Brézault C, et al. Hemolytic uremic syndrome as a complication of gemcitabine treatment: report of six cases and review of the literature. *Rev Med Interne [Internet]*. 2005 Mar; [cited 2022 Mar 28]; 26(3):179-88. Available from: <https://pubmed.ncbi.nlm.nih.gov/15777580/>
- Casper ES, Green MR, Kelsen DP, Heelan RT, Brown TD, Flombaum CD, et al. Phase II trial of gemcitabine (2,2'-difluorodeoxycytidine) in patients with adenocarcinoma of the pancreas. *Invest New Drugs [Internet]*. 1994; [cited 2022 Mar 28]; 12(1):29-34. Available from: <https://pubmed.ncbi.nlm.nih.gov/7960602/>
- Müller S, Schütt P, Bojko P, Nowrousian MR, Hense J, Seeber S, et al. Hemolytic uremic syndrome following prolonged gemcitabine therapy: report of four cases from a single institution. *Ann Hematol [Internet]*. 2005 Feb; [cited 2022 Mar 28]; 84(2):110-4. Available from: <https://pubmed.ncbi.nlm.nih.gov/15340761/>
- Izzedine H, Isnard-Bagnis C, Launay-Vacher V, Mercadal L, Tostivint I, Rixe O, et al. Gemcitabine-induced thrombotic microangiopathy: a systematic review. *Nephrol Dial Transplant [Internet]*. 2006 Sep; [cited 2019 Aug 23]; 21(11):3038-45. Available from: <https://academic.oup.com/ndt/article/21/11/3038/1877827>
- Ruiz I, Del Valle J, Gómez A. Gemcitabine and haemolytic-uraemic syndrome. *Ann Oncol*. 2004 Oct;15(10):1575-6.
- Zupancic M, Shah PC, Shah-Khan F. Gemcitabine-associated thrombotic thrombocytopenic purpura. *Lancet Oncol [Internet]*. 2007 Jul; [cited 2022 Mar 28]; 8(7):634-41. Available from: <https://pubmed.ncbi.nlm.nih.gov/17613425/>
- Al Ustwani O, Lohr J, Dy G, Levea C, Connolly G, Arora P, et al. Eculizumab therapy for gemcitabine induced hemolytic uremic syndrome: case series and concise review. *J Gastrointest Oncol [Internet]*. 2014 Feb; [cited 2022 Mar 28]; 5(1):E30-3. Available from: <https://www.ncbi.nlm.nih.gov/pmc/articles/PMC3904030/>
- Rieger M, Mannucci PM, Hovinga JAK, Herzog A, Gerstenbauer G, Konetschny C, et al. ADAMTS13 autoantibodies in patients with thrombotic microangiopathies and other immunomediated diseases. *Blood*. 2005 Aug;106(4):1262-7.
- Noris M, Bucchioni S, Galbusera M, Donadelli R, Bresin E, Castelletti F, et al. Complement factor H mutation in familial thrombotic thrombocytopenic purpura with ADAMTS13 deficiency and renal involvement. *J Am Soc Nephrol*. 2005 May;16(5):1177-83.
- Leal F, Macedo LT, Carvalho JBC. Gemcitabine-related thrombotic microangiopathy: a single-centre retrospective series. *J Chemother [Internet]*. 2014 Jun; [cited 2022 Mar 28]; 26(3):169-72. Available from: <https://pubmed.ncbi.nlm.nih.gov/24091354/>
- Picard C, Burtay S, Bornet C, Curti C, Montana M, Vanelle P. Pathophysiology and treatment of typical

- and atypical hemolytic uremic syndrome. *Pathol Biol (Paris)*. 2015 Jun;63(3):136-43.
18. Cidon EU, Martinez PA, Hickish T. Gemcitabine-induced haemolytic uremic syndrome, although infrequent, can it be prevented: a case report and review of literature. *World J Clin Cases* [Internet]. 2018 Oct; [cited 2022 Mar 28]; 6(12):531-7. Available from: <https://www.ncbi.nlm.nih.gov/pmc/articles/PMC6212612/>
 19. Bharthuar A, Egloff L, Becker J, George M, Lohr JW, Deeb G, et al. Rituximab-based therapy for gemcitabine-induced hemolytic uremic syndrome in a patient with metastatic pancreatic adenocarcinoma: a case report. *Cancer Chemother Pharmacol* [Internet]. 2009 Jun; [cited 2022 Mar 28]; 64(1):177-81. Available from: <https://pubmed.ncbi.nlm.nih.gov/19116715/>
 20. Gourley BL, Mesa H, Gupta P. Rapid and complete resolution of chemotherapy-induced thrombotic thrombocytopenic purpura/hemolytic uremic syndrome (TTP/HUS) with rituximab. *Cancer Chemother Pharmacol*. 2010 Jan;65(5):1001-4.
 21. Weitz M, Amon O, Bassler D, Koenigsrainer A, Nadalin S. Prophylactic eculizumab prior to kidney transplantation for atypical hemolytic uremic syndrome. *Pediatr Nephrol*. 2011 Aug;26(8):1325-9.