

Incidental finding of sex cord tumor with annular tubules in ovary associated with Peutz-Jeghers syndrome

Achado incidental de tumor do cordão sexual com túbulos anulares em ovário associado à síndrome de Peutz-Jeghers

Nathalia Beck Corrêa¹, Laura Paggiarin Skonieski¹, Francisco Costa Beber Lemanski¹, Rafael Baldissera²

ABSTRACT

Sex cord tumor with annular tubules (SCTAT) is a rare ovarian pathology. It is usually an incidental finding in asymptomatic patients. In about 30% of cases, this tumor is associated with the Peutz-Jeghers syndrome (PJS). This case report describes an incidental finding of SCTAT during an excisional surgery of a giant mucinous cystadenoma in the contralateral ovary. In addition to the finding of a rare tumor in association with a rare syndrome, a literature review on the diseases, their association, and management was performed.

Keywords: Peutz-Jeghers syndrome; Sex cord-gonadal stromal tumors; Ovarian sex cord-stromal tumours; Mucinous cystadenoma; Mucinous ovarian tumors.

RESUMO

O tumor do cordão sexual com túbulos anulares (TCSTA) é uma patologia ovariana rara. Geralmente é um achado incidental em pacientes assintomáticos. Em cerca de 30% dos casos, esse tumor está associado à síndrome de Peutz-Jeghers (SPJ). Este relato de caso descreve um achado incidental de TCSTA durante uma cirurgia excisional de um cistoadenoma mucinoso gigante no ovário contralateral. Além do achado de um tumor raro associado a uma síndrome rara, foi realizada uma revisão da literatura sobre as doenças, sua associação e manejo.

Palavras-chave: Síndrome de Peutz-Jeghers; Tumores do estroma cordão-gonadal sexual; Tumores do cordão sexual ovariano; Cistadenoma mucinoso; Tumores mucinosos do ovário.

1. Universidade de Passo Fundo, Faculdade de Medicina - Passo Fundo - Rio Grande do Sul - Brazil.

2. Hospital São Vicente de Paulo, - Passo Fundo - Rio Grande do Sul - Brazil.

Financial support: none to declare.


Conflicts of interest: The authors declare no conflict of interest relevant to this manuscript.

Correspondence author: Laura Paggiarin Skonieski.

E-mail: 174412@upf.br

Received on: Apr 4, 2022 | **Accepted on:** May 18, 2022 | **Published on:** Jun 22, 2022

DOI: <https://doi.org/10.5935/2526-8732.20220343>

 This is an open-access article distributed under the terms of the Creative Commons Attribution License.

INTRODUCTION

Sex cord tumor with annular tubules (SCTAT) is a rare type of sex cord stromal tumor, which differs from other tumors in its histomorphology.^[1] Approximately one third of SCTAT are associated with Peutz-Jeghers syndrome (PJS).^[1,2] PJS is a rare autosomal dominant disease with no gender preference,^[3] characterized by multiple hamartomatous polyps in the gastrointestinal tract associated with mucocutaneous melanic pigmentation. Patients with PJS have an increased risk of other neoplasms involving the gastrointestinal tract, breast, female genital tract, testis, and pancreas.^[4]

The aim of this paper is to report a rare case of sex cord tumor with annular tubules in ovary as an occasional finding, associated with PJS, in a 53-year-old patient with previous history of multiple neoplasms, who underwent resection of giant cystadenoma in contralateral ovary. No similar cases were found in the literature.

CASE REPORT

Female, 53-years-old, with PJS and personal history of several tumors. She could not tell much about her family history, only that her father died of cardiovascular disease and her mother died of thrombosis during the puerperium, being raised by her paternal grandmother. During a routine examination for her disease history and PJS, a mucinous cystic lesion was discovered in the left ovary.

The patient was asymptomatic and underwent a transvaginal ultrasound that revealed an anechoic, regular, septated cyst with no vascularization in left ovary, with volume of 61cm³, occupying the entire ovarian tissue with benign characteristics. The right ovary volume was 2.9cm³ with normal appearance. Subsequent computed tomography (CT) scan revealed similar aspects of the lesion. She had TUS from two years earlier with no particularities. Laboratory exams and serum CEA (carcinoembryonic antigen) and CA-19.9 levels were normal. The patient then underwent ovarian debulking surgery, with salpingectomy and bilateral oophorectomy. The complex solid-cystic lesion of the left ovary was resected and measured about 30cm in diameter, showing a smooth capsule and there were no peritoneal implants. Transoperative freezing of the specimen revealed a mucinous cystadenoma (benign). However, during the transoperative freezing, a white area was suspected in the contralateral (right) ovary, which was later diagnosed as a sex cord tumor with annular tubules on pathology (Figures 1 and 2). The patient was admitted to an ICU bed, and two days after the procedure she developed acute abdomen, with intestinal obstruction and suffering from a transverse colon loop, presenting an area of ischemia with perforation and local collection. Laparotomy and debridement of the devitalized intestinal wall in two-layer raffia were performed. After surgery, the patient progressed well.

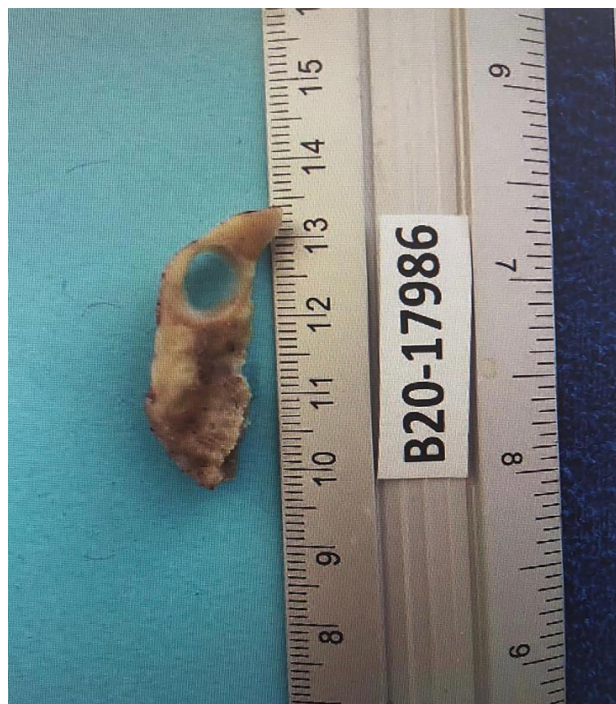

Figure 1. Macroscopy of sex cord tumor

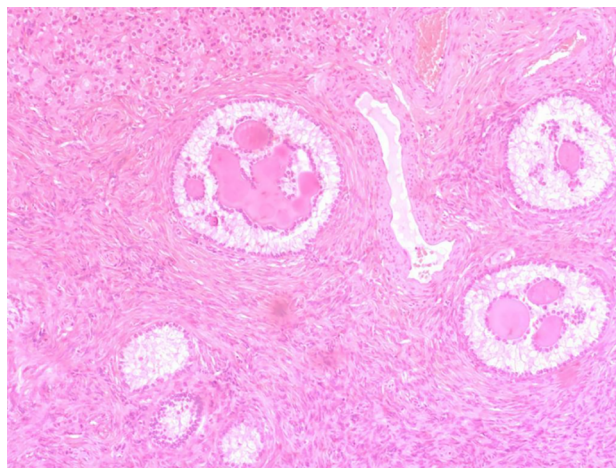


Figure 2. Microscopy of sex cord tumor with annular tubules

The patient was followed up exclusively through Brazil's unified health system (SUS), which made further genetic evaluations difficult. In addition to her follow-up, several biopsies were performed in the past, showing invasive mucinous carcinoma in the left breast, intestinal tubulovillous adenoma with low-grade dysplasia, papillary thyroid carcinoma, well differentiated clear cell renal cell carcinoma, and epithelial bladder cancer.

DISCUSSION

SCTAT is a rare type of ovarian stromal tumor that differs from other sex cord stromal tumors in its distinct histomorphology. The histological types of sex cord tumors are: adult granulosa cell tumor, juvenile granulosa cell tumor, Sertoli-Leydig cell tumor, sex cord tumor with annular tubules, and mixed forms including gynandroblastoma.^[6]

Among them, the most common are juvenile granulosa cell tumors and Sertoli-Leydig cell tumors, accounting for approximately 85% of cases. Sex cord tumors with annular tubules, on the other hand, represent <1% of all sex cord tumors and typically occur in patients in their third or fourth decade of life.^[1] This tumor was first reported by Scully in 1970, who described its characteristic histology and association with Peutz-Jeghers syndrome (PJS).^[1,5] Sex cord tumors with annular tubules show tubules with Sertoli cells arranged around one or more hyaline bodies. In patients with Peutz-Jeghers syndrome, these tubules may be scattered and mixed with normal ovarian tissue rather than forming a distinct mass.^[6]

PJS is an hereditary syndrome caused mostly by germinative mutations in the STK11 tumor suppressor gene.^[7,8] Patients with PJS have two characteristic clinical manifestations of the syndrome: mucocutaneous melanotic macules and multiple hamartomatous polyps in the gastrointestinal tract. Mucocutaneous lesions are present in 95% of the patients and are typically located on the lips, perioral region, gums, palms of the hands, and soles of the feet.^[9] Polyps are most prevalent in the small intestine (60-90%), mainly jejunum, stomach (15-30%), and colon (50-64%).^[8] In addition, PJS is associated with an increased risk of malignancies. Patients with PJS have an increased risk of developing cancers of the gastrointestinal tract, as well as non-gastrointestinal epithelial malignancies, mainly in the breast, uterus, lung, ovary, and testis.

Considering the patients diagnosed with SCTAT, about one third have PJS.^[10] Clinical presentations include irregular menstruation, hyperestrinism, the presence of a mass and abdominal/pelvic pain, and in young people there may be sexual precocity.^[1,10] The vast majority of patients with SCTAT and PJS also have gastrointestinal polyposis and mucocutaneous melanin pigmentation.^[10]

Most ovarian SCTAT are benign.^[5] This tumor varies depending on how it presents with PJS. There are two clinical presentations: the tumors associated with PJS are usually small, solid and bilateral and have a low malignant potential (hereditary form), and the other occurs as a solitary neoplasm in patients without evidence of the syndrome (sporadic form).^[1,5] Patients with PJS are slightly younger (mean age 27 years) than those without the syndrome (mean age 36 years). The sex cord stromal tumors, other than SCTAT, associated with PJS are Sertoli cell tumors, granulosa cell tumors, steroid cell tumors, Sertoli-Leydig cell tumor, and unclassified sex cord stromal tumors. Sertoli cell tumor is the most common.^[4]

Hence, although there is some divergence in the literature, the SCTAT seems to have morphological characteristics intermediate between granulosa cell tumors and Sertoli cell tumors.^[1,10] Histologically, this tumor type is characterized by well-circumscribed rounded epithelial nests, simulating an appearance of ring-shaped tubes surrounding hyaline bodies. These nests have two patterns: simple and complex tubular structures, with and without hyaline nuclei.^[1]

There is still no gold standard for the treatment of SCTAT, due to its rarity. Surgical treatment is generally proposed, with unilateral or bilateral adnexectomy or hysterectomy, according to the stage and desire to gestate.^[11] Unilateral salpingo-oophorectomy is the treatment of choice in unilateral encapsulated tumors and where fertility preservation is necessary. Adjuvant treatment with chemotherapy should be considered in cases of large tumors.^[5] The prognosis is positive, but the risk of recurrence is considered high.^[11] Follow-up can be performed with serum estrogen and progesterone dosage along with inhibin levels.

REFERENCES

- Chen X, Crapanzano JP, Gonzalez AA, Hamele-Bena D. Cytologic features of needle aspiration of ovarian sex cord tumor with annular tubules: Report of two cases and literature review. *Diagn Cytopathol*. 2018 Jul;46(7):627-31. DOI: <http://doi.wiley.com/10.1002/dc.23908>
- Mayerson BD, Cuello FM, Brañes YJ, Leiva CV, Castiblanco GA. Tumor de los cordones sexuales con túbulos anulares del ovario no asociado a síndrome de Peutz-Jeghers: reporte de un caso. *Rev Chil Obstet Ginecol* [Internet]. 2006; 71(1):57-62. Available from: http://www.scielo.cl/scielo.php?script=sci_arttext&pid=S0717-75262006000100010&lng=en&nrm=iso&tlng=en
- Nevozinskaya Z, Korsunskaya I, Sakaniya L, Perlamutrov Y, Sobolev V. Peutz-Jeghers syndrome in dermatology. *Acta Dermatovenerol Alp Pannonica Adriat* [Internet]. 2019 Sep; 28(3):135-7. Available from: <http://www.ncbi.nlm.nih.gov/pubmed/31545393>
- Maity P, Das N, Chatterjee U, Basak D. Sex-cord tumor with annular tubules with unusual morphology in an infant with Peutz-Jeghers syndrome. *Fetal Pediatr Pathol* [Internet]. 2020 Apr;41(2):306-11. Available from: <http://www.ncbi.nlm.nih.gov/pubmed/32609034>
- Senn D, Videira H, Haagsma B, El-Bahrawy M, Madhuri TK. Sex cord tumour with annular tubules—an unusual case of abdominal pain. *J Obstet Gynaecol Canada* [Internet]. 2021 Mar; 43(3):361-4. Available from: <https://linkinghub.elsevier.com/retrieve/pii/S170121632030582X>
- Schultz KA, Harris AK, Schneider DT, Young RH, Brown J, Gershenson DM, et al. Ovarian sex cord-stromal tumors. *J Oncol Pract*. 2016;12(10):940-6. DOI: <https://doi.org/10.1200/JOP.2016.016261>
- Hemminki A, Markie D, Tomlinson I, Avizienyte E, Roth S, Loukola A, et al. A serine/threonine kinase gene defective in Peutz-Jeghers syndrome. *Nature* [Internet]. 1998 Jan; 391(6663):184-7. Available from: <http://www.nature.com/articles/34432>
- Jenne DE, Reomann H, Nezu J, Friedel W, Loff S, Jeschke R, et al. Peutz-Jeghers syndrome is caused by mutations in a novel serine threonine kinase. *Nat Genet* [Internet]. 1998 Jan; 18(1):38-43. Available from: <http://www.nature.com/articles/ng0198-38>

9. Utsunomiya J, Gocho H, Miyanaga T, Hamaguchi E, Kashimure A. Peutz-Jeghers syndrome: its natural course and management. *Johns Hopkins Med J* [Internet]. 1975 Feb; 136(2):71-82. Available from: <http://www.ncbi.nlm.nih.gov/pubmed/1117595>
10. Swanger RS, Brudnicki A. Ultrasound of ovarian sex-cord tumor with annular tubules. *Pediatr Radiol* [Internet]. 2007 Dec; 37(12):1270-1. Available from: <http://www.ncbi.nlm.nih.gov/pubmed/17764009>
11. Qian Q, You Y, Yang J, Cao D, Zhu Z, Wu M, et al. Management and prognosis of patients with ovarian sex cord tumor with annular tubules: a retrospective study. *BMC Cancer* [Internet]. 2015 Dec; 15(1):270. Available from: <http://bmccancer.biomedcentral.com/articles/10.1186/s12885-015-1277-y>