

# The role of pelvic rehabilitation in quality of life in a patient harboring metastatic chordoma: a case report

O papel da reabilitação pélvica na qualidade de vida em paciente portadora de cordoma metastático: relato de caso

Dalila Gonçalves Duarte<sup>1</sup>, Matheus Fernandes de Oliveira<sup>2</sup>, Eduardo de Arnaldo Silva Vellutini<sup>2</sup>, Ricardo Caponero<sup>3</sup>, Katia Cristina Camondá Braz<sup>3</sup>

## ABSTRACT

**Introduction:** Chordoma is a malignant tumor that usually involves the axial skeleton. Intradural chordomas are even rarer and 37 cases have been reported to the best of our knowledge. We present a case of a patient with an atypical metastatic diffuse intradural spinal involvement. **Objective:** To investigate therapeutic approaches such as pelvic physiotherapy for hospitalized and palliative patients in a private institution diagnosed with advanced cancer. **Case Report:** We present a 33-year-old woman previously submitted to five brain surgeries to treat a posterior fossa intradural chordoma since December 2012. There were new vertebral intradural lesions. The patient underwent complementary treatment with pelvic physiotherapy to improve the quality of life of the urinary and fecal system. **Material and Methods:** After six sessions of pelvic physiotherapy in bed and a month of behavioral monitoring and exercise practice, she returned to the condition of adequate urinary continence, thus obtaining an expressiveness in the overall quality of life.

**Keywords:** Brain neoplasm; Chordoma; Spine; Spinal cord; Recurrence; Rehabilitations; Quality of life.

## RESUMO

**Introdução:** Cordoma é um tumor maligno que geralmente envolve o esqueleto axial. Cordomas intradurais são ainda mais raros e 37 casos foram relatados até onde sabemos. Apresentamos o caso de um paciente com acometimento espinhal intradural difuso metastático atípico. **Objetivo:** Investigar abordagens terapêuticas como a fisioterapia pélvica para pacientes hospitalizados e paliativos em uma instituição privada com diagnóstico de câncer avançado. **Relato de Caso:** Apresentamos uma mulher de 33 anos previamente submetida à cinco cirurgias cerebrais para tratamento de cordoma intradural de fossa posterior desde dezembro de 2012. Ocorreram novas lesões intradurais vertebrais. A paciente foi submetida a tratamento complementar com fisioterapia pélvica para melhorar a qualidade de vida do aparelho urinário e fecal. **Material e Métodos:** Após seis sessões de fisioterapia pélvica no leito e um mês de acompanhamento comportamental e prática de exercícios, voltou ao estado de continência urinária adequada, obtendo assim expressividade na qualidade de vida geral.

**Palavras-chave:** Neoplasia cerebral; Cordoma; Coluna; Medula espinhal; Recorrência; Reabilitações; Qualidade de vida.

1. Hospital Alemão Oswaldo Cruz, Urology and Palliative Care - Sao Paulo - Sao Paulo - Brazil.

2. Hospital Alemão Oswaldo Cruz, Neurosurgery Department - DFV Neuro - Sao Paulo - Sao Paulo - Brazil.

3. Hospital Alemão Oswaldo Cruz, Oncology and Palliative Care - Sao Paulo - Sao Paulo - Brazil.

**Financial support:** none to declare.

**Conflicts of interest:** The authors declare no conflict of interest relevant to this manuscript.

**Correspondence author:** Dalila Gonçalves Duarte.

E-mail: dalilagduarte@gmail.com

**Received on:** Jan 13, 2022 | **Accepted on:** Apr 29, 2022 | **Published on:** Jun 22, 2022

**DOI:** <https://doi.org/10.5935/2526-8732.20220330>

## INTRODUCTION

Chordoma is a malignant tumor that usually involves the axial skeleton. They originate from remnants of the primitive notochord, with incidence of approximately 35% in clivus and 50% in sacrococcygeal region. Chordomas account for 1% of all primary brain tumors.<sup>[4]</sup> The most affected group are middle-aged adults.<sup>[5]</sup>

Treatment is often difficult because the tumor is refractory to traditional cytotoxic agents and conventional radiotherapy, making block resection the main choice.<sup>[6]</sup> However, the outcome of the treatment is significantly influenced by the size and location of the chordoma. Disease evolution may lead to severe quality of life impairment before death.<sup>[7]</sup>

We described previously an uncommon case of intratumoral bleeding in an intradural posterior fossa chordoma mimicking a spontaneous intraparenchymatous hemorrhage.<sup>[1]</sup> Posteriorly, we described the diffuse spinal spread of tumor and subsequent symptoms. Now we discuss specifically the aims and results of pelvic rehabilitation of this patient.

## CASE REPORT

### History

We present a 33-year-old woman previously submitted to five brain surgeries to treat intradural chordoma of the posterior fossa since December 2012.<sup>[1]</sup>

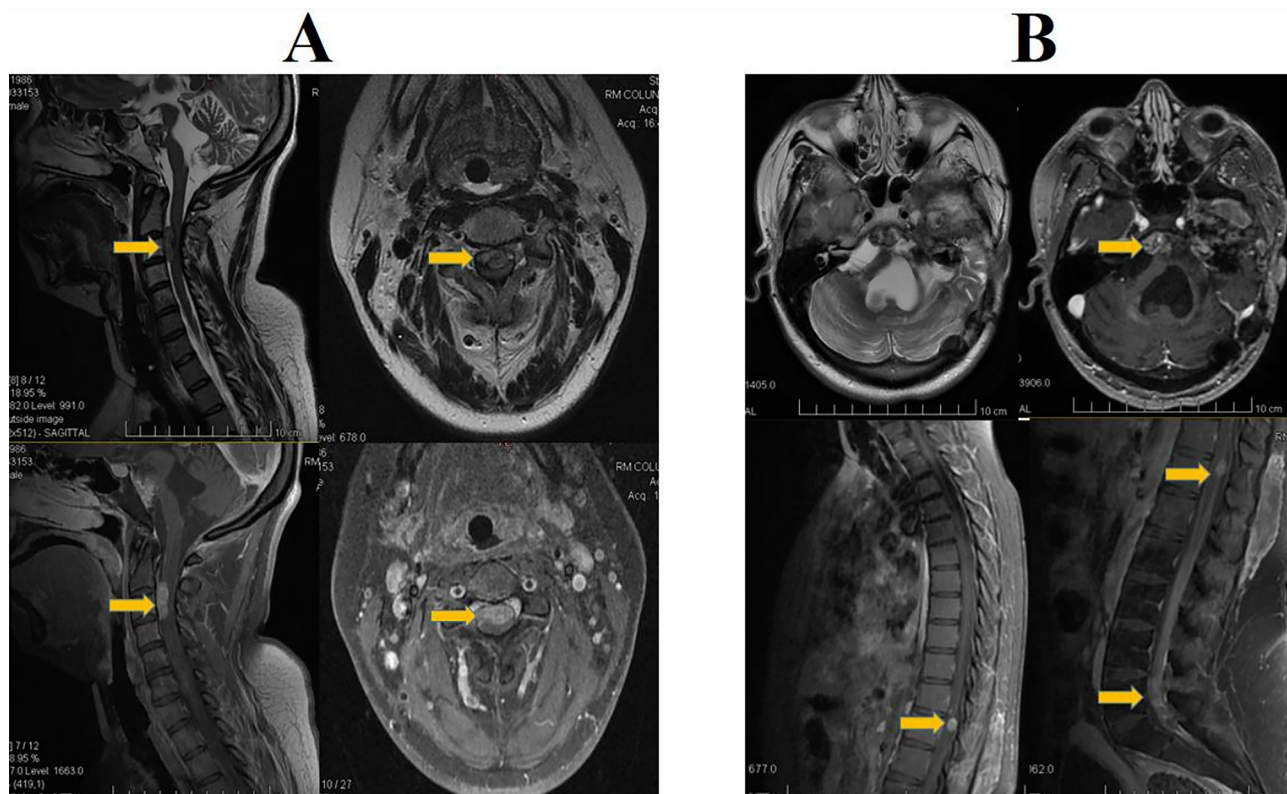
Initially, the intradural chordoma presented as an intratumoral bleeding.<sup>[1]</sup> The patient recovered well and was lastly discharged with disproportionate right hemiparesis (grade II in right upper extremity and IV in right lower extremity). Additionally, she presented left oculomotor, abducent, and facial nerve paresis.

Currently, she presented almost with right and left hemiplegia (grade 2 bilaterally) and left oculomotor, abducent and facial nerve paresis. Additionally, there was dysphagia, dysarthria, and appendicular ataxia. She also complained of low back pain, coccydynia and stool and urinary retention, needing daily use of stool softeners and bladder catheterization thrice to four times/day.

We performed neuroaxis magnetic resonance MR, which disclosed stability of posterior fossa tumor that was previously irradiated (Figure 1). However, there were new intradural lesions at the level of C3, T11/T12, and L4/L5/S1 vertebrae.

### Care plan

Chordomas are lesions with difficult management due to recurrence and progressive clinical deterioration of patient with small chances of cure. When there is impossibility of resection or multiple recurrences management changes towards improvement of neurological symptoms and improvement in quality of life.<sup>[8]</sup>



**Figure 1.** MR imaging. In A, sagittal and axial T2 and T1 gadolinium enhanced images revealing intradural chordoma metastasis at the level of C3. In B, the additional evaluation of brain and spine at that moment. There was residual lesion in posterior fossa, a lesion in thoracic spinal cord and also in lumbosacral roots at the level of L4-L5-S1.

In addition to the neurological symptoms caused by the disease or the sequelae of treatments, psychological symptoms (anxiety, depression, etc.), and spiritual needs are usually present from diagnosis.<sup>[9]</sup>

Since we have a disease with no prospects for a cure and the presence of symptoms that are difficult to control, the introduction of palliative care in conjunction with antineoplastic treatment is recommended and highlighted by publications of the American Society of Clinical Oncology (ASCO),<sup>[10,11]</sup> European Society of Medical Oncology (ESMO),<sup>[12]</sup> from the National Comprehensive Cancer Network (NCCN),<sup>[13]</sup> among others.

The objective of palliative care is to provide better control of physical, psychosocial, and spiritual symptoms, extending this view of care to family members, for whom mourning assistance is also appropriate, especially in young patients as in the case reported.

The inability to control the sphincters is among the uncomfortable symptoms that are said to be worse than death.<sup>[14]</sup> For this reason, pelvic physiotherapy was of fundamental importance in the case reported, allowing sphincter control and independence in the use of diapers, improving the patient's dignity, even in a scenario of poor prognosis and with other symptoms that are difficult to palliate, in addition to the sequelae neurological.

## MATERIAL AND METHODS

This retrospective study which was submitted to Institutional Ethics and Human Research Committee approved under the CAEE (certificate do presentation of ethical appreciation) number 52340621.8.0000.0070 and under opinion No. 5.047.138.

Pelvic physical therapy procedure:

The physical evaluation was performed by the pelvic floor muscle assessment (PERFECT),<sup>[15]</sup> graded from 0 to 5 was performed with movements such as: a) power, endurance, repetition and fast and every, contractions and timed reflexes of the region; b) muscle tone in the pelvic region with palpation; c) sacral sensitivity test and perineum region, d) lower limb motility test was also applied.<sup>[16]</sup>

In the evaluation, the patient presented: a) PERFECT with grade P0, E0, R0, F0, CS, TS the co-contraction was minimal; b) Perineal muscle tone was weak; c) Sensitivity test showed hyposensitivity in the region of the entire perineum (large and small vulvar lips), tingling paresthesia in the body of the perineum and pubic region and pain in the region close to the sacral region due to tumor damage; d) positive motor test without voluntary movement of the lower limbs.<sup>[16]</sup>

After the initial evaluation, urinary retention and severe constipation were detected (according to the Rome IV criteria).<sup>[17]</sup>

The patient was submitted to a rehabilitation program of the perineal region, every day, once a day and lasting approximately 45 minutes each session in her bed, totaling 6 face-to-face sessions plus guidance with the family member to be carried out at home. The sessions consisted of using electrotherapy (CARCI, São Paulo, Brazil) in FES mode (functional electrical stimulation) in the transverse region of the abdomen plus the perineal body region for learning perineal relaxation and were divided into two phases each of eight minutes with a second ON, one second OFF, and one second ON and two seconds OFF together guiding the importance of relaxation for urine output.<sup>[18]</sup>

Incomplete neural injuries may be common in oncologic pictures like the present case. In such cases, remaining neural stimuli become responsible for the innervation of a greater number of muscle fibers and produce less effective contractions, causing loss of urethral support.<sup>[18]</sup>

Electrical stimulation is believed to be able to increase intraurethral pressure through direct stimulation of the efferent nerves to the periurethral musculature, and by improving local blood flow.<sup>[19]</sup> It is worth mentioning that the main objective of functional electrostimulation (FES) is to strengthen pelvic floor muscles, so it helps to improve urethral closing pressure by contracting more, if necessary. However, it does not prevent from urinary leakage. Thus, it is also necessary for the woman to acquire awareness of the perineal region. From the moment, she becomes aware of how to correctly contract the pelvic floor muscles; she will be able to produce an efficient contraction prior to any physical effort, which reduces the episodes of incontinence.<sup>[19]</sup>

The proposal made for this patient was divided into two stages: the first with rapid contractions in search of strengthening the pelvic floor and the other with longer relaxation time, prioritizing adequate relaxation for spontaneous urination and thus removing the use of the urinary catheter for relief.

In addition to the FES electrotherapy, electrotherapy was performed in TENS mode (transcutaneous electrical nerve stimulation) in the parasacral region to improve constipation. Before performing bladder catheterization, patient was encouraged to relax the region and try to urinate spontaneously. To do so, patient was kept seated and abdominal massages for fecal motility and bladder stimuli were also done.

The choice to use the parasacral ES was due to lower limbs motor deficits. Although many mechanisms are still uncertain regarding the use of electrostimulation (EE) or electroacupuncture, several studies suggest that it results in an increase in gastrointestinal motility, probably via reflex with activation of the supraspinal pathways that contribute to the effectiveness of intestinal function.<sup>[20,21]</sup> It is known that the regulation of intestinal motility is influenced by the autonomic nervous system. While sympathetic predominantly inhibits the gastrointestinal tract and muscle activity, the parasympathetic system regulates propulsive colonic motility.<sup>[18]</sup>

In addition to the FES electrotherapy, electrotherapy was performed in TENS mode (transcutaneous electrical nerve stimulation) in the parasacral region to improve constipation.<sup>[21,22]</sup> Always before relief bladder catheterization, the patient should relax the region and try to urinate in the diaper on her bed with the back of the trunk positioned at 90 degrees and abdominal massages for fecal motility and bladder stimuli at the time of spontaneous urination attempt.

## RESULTS

The data with the functional improvement are shown in Table 1.

After the patient performed six pelvic physiotherapy sessions in order to bring quality of life to the urinary and fecal systems, she began to obtain positive results with an improvement in the urinary condition. After the patient left the hospital, she remained in remote contact with the physiotherapist for behavioral adjustments and daily exercises in the pelvic region, thus obtaining 100% improvement in her urinary condition. The fecal condition remained diagnosed with constipation.

The patient reported a great and expressive improvement in her quality of life as she returned to independence to perform her spontaneous bladder voiding.

## DISCUSSION AND CONCLUSION

Chordomas are rare, locally aggressive neoplasms of notochordal origin, accounting for 1% to 4% of all bone malignancies and 0.5% of all primary intracranial central nervous system.<sup>[4]</sup> They characteristically tend to recur. In our case, a 33-year-old woman presented with acute new neurologic symptoms in a scenario of spinal cord metastatic intradural chordoma. With the advent of contemporaneous surgery, radiotherapy options and even available target therapy to treat chordomas (imatinib),<sup>[22]</sup> patients may experience enlarged survival and thus face complications such as drop metastases along neuroaxis.<sup>[1,2]</sup>

The impact of rehabilitation and quality of life measures in such patients is almost unknown. Some papers have already pointed the challenges and impact of chordoma symptoms and treatment in quality of life, however up to date there is no report of specific rehabilitation program used in the course of disease.<sup>[23,24]</sup>

Our case illustrates a late (7 years) follow-up presentation of an initial posterior fossa intradural chordoma. Probably due to surgical and adjuvant therapies, patient could experience a larger time of life and thus presented with bone and intradural tumoral spread, leading to motor and visceral symptoms. Even with limited survival time due to malignant nature of disease, it is possible to address specific symptoms such as pelvic ones and improve functions to reduce burden and improve quality of life.

**Table 1.** Electrotherapy procedure.

Session I	Session II	Session III	Session IV	Session V	Session VI
FES (8', 01 ON, 1 OFF) FES (8', 01 ON, 02 OFF)	FES (8', 01 ON, 1 OFF) FES (8', 01 ON, 02 OFF)	FES (8', 01 ON, 1 OFF) FES (8', 01 ON, 02 OFF)	FES (8', 01 ON, 1 OFF) FES (8', 01 ON, 02 OFF)	FES (8', 01 ON, 1 OFF) FES (8', 01 ON, 02 OFF)	FES (8', 01 ON, 1 OFF) FES (8', 01 ON, 02 OFF)
PARASACRAL TENS L 200US, 10 HZ, 20'	PARASACRAL TENS L 200US, 10 HZ, 20'	PARASACRAL TENS L 200US, 10 HZ, 20'	PARASACRAL TENS L 200US, 10 HZ, 20'	PARASACRAL TENS L 200US, 10 HZ, 20'	PARASACRAL TENS L 200US, 10 HZ, 20'
Got in a little amount of spontaneous urination	Functional improvement but with 500 ml bladder residue	No spontaneous urination	380 ml present urination + evacuation	380 ml urination + urination present during the session	Spontaneous urination of at least 300 ml at a time

## REFERENCES

- Vellutini EAS, Oliveira MF. Intradural chordoma presenting with intratumoral bleeding. *J Clin Neurosci.* 2016 Mar;25:139-42. DOI: <https://doi.org/10.1016/j.jocn.2015.07.023>
- Zhang J, Gao CP, Liu XJ, Xu WJ. Intradural cervical chordoma with diffuse spinal leptomeningeal spread: case report and review of the literature. *Eur Spine J.* 2018;27(3):440-5. DOI: <https://doi.org/10.1007/s00586-017-5443-6>
- Vellutini EAS, Brock RS, Martins HO, Taricco MA, Oliveira MF. Diffuse spinal spreading following previous intracranial intradural chordoma resection: a rare case report. *J Clin Neurosci.* 2019 Jun;64:44-6. DOI: <https://doi.org/10.1016/j.jocn.2019.03.020>
- Das P, Soni P, Jones J, Habboub G, Barnholtz-Sloan JS, Recinos PF, et al. Descriptive epidemiology of chordomas in the United States. *J Neurooncol.* 2020 Apr;148(1):173-8. DOI: <https://doi.org/10.1007/s11060-020-03511-x>
- Frezza AM, Botta L, Trama A, Dei Tos, A, Stacchiotti S. Chordoma: update on disease, epidemiology, biology and medical therapies. *Curr Opin Oncol.* 2019 Mar;31(2):114-20. DOI: <https://doi.org/10.1097/CCO.0000000000000502>

6. Whelan JS, Davis LE. Osteosarcoma, chondrosarcoma, and chordoma. *J Clin Oncol*. 2018;36(2):188-93. DOI: <https://doi.org/10.1200/JCO.2017.75.1743>
7. Song PH, Beyhaghi H, Sommer J, Bennett AV. Symptom burden and life challenges reported by adult chordoma patients and their caregivers. *Qual Life Res*. 2017;26(8):2237-44. DOI: <https://doi.org/10.1007/s11136-017-1544-2>
8. Diaz RJ, Maggacis N, Zhang S, Cusimano MD. Determinants of quality of life in patients with skull base chordoma. *J Neurosurg*. 2014;120(2):528-37. DOI: <https://doi.org/10.3171/2013.9.JNS13671>
9. Schwab JH, Janssen SJ, Pereira NRP, Chen YLE, Wain JC, DeLaney TF, et al. Quality of life after resection of a chordoma of the mobile spine. *Bone Joint J*. 2017 Jul;99(7):979-86. DOI: <https://doi.org/10.1302/0301-620X.99B7.Bjj-2016-1126.R1>
10. Ferrell BR, Temel JS, Temin S, Alesi ER, Balboni TA, Basch EM, et al. Integration of palliative care into standard oncology care: American Society of Clinical Oncology clinical practice guideline update. *J Clin Oncol*. 2017;35(1):96-112. DOI: <https://doi.org/10.1200/JCO.2016.70.1474>
11. Ferrell BR, Temel JS, Temin S, Smith TJ. Integration of palliative care into standard oncology care: ASCO clinical practice guideline update summary. *J Oncol Pract*. 2017;13(2):119-21. DOI: <https://doi.org/10.1200/JOP.2016.017897>
12. Jordan K, Aapro M, Kaasa S, Ripamonti CI, Scotté F, Strasser F, et al. European Society for Medical Oncology (ESMO) position paper on supportive and palliative care. *Ann Oncol*. 2018 Jan;29(1):36-43. DOI: <https://doi.org/10.1093/annonc/mdx757>
13. Dans M, Smith T, Back A, Baker JN, Bauman JR, Beck AC, et al. NCCN guidelines insights: palliative care, version 2.2017. *J Natl Compr Canc Netw*. 2017 Aug;15(8):989-97. DOI: <https://doi.org/10.6004/jnccn.2017.0132>
14. Rubin EB, Buehler AE, Cooney E, Gabler NB, Mante AA, Halpern SD. Intuitive vs deliberative approaches to making decisions about life support: a randomized clinical trial. *JAMA Netw Open*. 2019;2(1):e187851. DOI: <https://doi.org/10.1001/jamanetworkopen.2018.7851>
15. Laycock JO, Jerwood D. Pelvic floor muscle assessment: the PERFECT scheme. *Physiotherapy*. 2001 Dec;87(12):631-42. DOI: [https://doi.org/10.1016/S0031-9406\(05\)61108-X](https://doi.org/10.1016/S0031-9406(05)61108-X)
16. Van Wulfften Palthe ODR, Janssen SJ, Wunder JS, Ferguson PC, Wei G, Rose PS, et al. What questionnaires to use when measuring quality of life in sacral tumor patients: the updated sacral tumor survey. *Spine J*. 2017 May;17(5):636-44. DOI: <https://doi.org/10.1016/j.spinee.2016.11.004>
17. Simren M, Palsson OS, Whitehead WE. Update on Rome IV criteria for colorectal disorders: implications for clinical practice. *Curr Gastroenterol Rep*. 2017;19(4):15. DOI: <https://doi.org/10.1007/s11894-017-0554-0>
18. Rodrigues JA, Moreira AC, Elias LLK, Castro M. *Neuroendocrinologia básica e aplicada*. Rio de Janeiro: Guanabara Koogan; 2006.
19. Cestari EC, Souza THC, Silva SA. Eletroestimulação no tratamento da incontinência urinária esforço feminina. *Rev Ciênc Estud Acad Med*. 2016;1(6):93-101.
20. Grosse D, Sengler J. *Reeducação perineal: concepção, realização e transcrição em prática liberal e hospitalar*. São Paulo: Manole; 2002.
21. Browning KN, Travagli RA. Central nervous system control of gastrointestinal motility and secretion and modulation of gastrointestinal functions. *Compr Physiol*. 2014 Oct;4(4):1339-68.
22. Luo S, Xu H, Zuo Y, Liu X, All AH. A review of functional electrical stimulation treatment in spinal cord injury. *Neuromol Med*. 2020 Jan;22:447-63. DOI: <https://doi.org/10.1007/s12017-019-08589-9>