


Dermatofibrosarcoma: report of a case with complete response to imatinib and conservative surgery during the COVID-19 pandemic

Dermatofibrossarcoma: relato de um caso com resposta completa ao imatinibe e cirurgia conservadora durante a pandemia de COVID-19

Rafael Martins Steffen¹, Arthur Fernandes Pacheco¹, Gabriela Camilo Teixeira¹, Bruna Alejandra Orellana Santos¹, Marina Quaglio Oinegue Fulfaro¹, Ketleen Koga¹, Amanda Fonseca Nunes Ferreira¹, James Cotaet Junior², Deborah Krutman Zveibil², Rafael Ricardo da Silva Miranda Zapata³

ABSTRACT

Dermatofibrosarcoma protuberans (DFSP) is an extremely rare and potentially aggressive soft tissue tumor. Around 85 to 90% of DFSP cases are low-grade tumors, while the fibrosarcomatous variant (DFSP-FS) is associated with medium and high-grade neoplasms. DFSP affects more young adults, in their 30s; however, it can be present in all ages. It has a high potential for locoregional dissemination and recurrence, directly related to tumor size. In the present study, a case of dermatofibrosarcoma protuberans with local recurrence after surgical treatment will be reported, subsequently treated with imatinib and a new surgical approach, with no new recurrences so far. The effectiveness of imatinib is noted in a deep, infiltrative and relapsed DFSP, in which upfront surgery would cause significant functional and cosmetic damage. Imatinib allowed an important clinical improvement for the patient, with tumor reduction in the initial weeks of treatment.

Keywords: Dermatofibrosarcoma; Imatinib mesylate; Complementary therapies.

1. Faculdade de Medicina do ABC, Cirurgia Oncológica - Santo André - SP - Brazil.
2. Faculdade de Medicina do ABC, Patologia - Santo André - SP - Brazil.
3. Faculdade de Medicina do ABC, Oncologia Clínica - Santo André - SP - Brazil.

Financial support: none to declare.


Conflicts of interest: The authors declare no conflict of interest relevant to this manuscript.

Correspondence author: Rafael Martins Steffen.

E-mail: steffen.rm1@hotmail.com

Received on: Jul 18, 2021 | **Accepted on:** Aug 31, 2021 | **Published on:** Mar 09, 2022

DOI: <https://doi.org/10.5935/2526-8732.20220289>

 This work is licensed under a Creative Commons Attribution-NonCommercial-ShareAlike 4.0 International License. (<http://creativecommons.org/licenses/by-nc-sa/4.0/>).

INTRODUCTION

The treatment of cancer during the COVID-19 pandemic has been a challenge. Lethality rates in immunocompromised patients with COVID-19 are extremely high, as in the case of cancer patients, making the therapeutic decision on oncological patients to be taken very difficult.

Dermatofibrosarcoma protuberans (DFSP) is an extremely rare and potentially aggressive soft tissue tumor. Around 85 to 90% of DFSP cases are low-grade tumors, while the fibrosarcomatous variant (DFSP-FS) is associated with medium and high-grade neoplasms.

DFSP affects more young adults, in their 30s;^[1-5] however, it can be present in all ages, including children and the elderly, with rare cases of congenital presentation.^[1,2,4,6-9] The prevalence of DFSP in pediatric cancer cases is around 6%.^[10]

DFSP has a high potential for locoregional dissemination and recurrence, directly dependent on tumor size. However, metastatic disease is rare, found in approximately 5% of cases. Complete resection of the lesion with negative surgical margins is the gold standard of treatment. In some cases, where resection is not possible due to involvement of essential structures or significant functional or aesthetic risk, it is possible to opt for alternative therapies.

The rearrangement of chromosomes 17 and 22 is typical of DFSP, which can be detected by standard cytogenetics as translocation t(17;22)(q22;q13) or a supernumerary ring chromosome. This translocation is thought to cause the fusion of collagen type I A1 chain (COL1A1) gene to the platelet-derived growth factor B chain (PDGFB) gene. This COL1A1-PDGFB fusion may be identified in virtually all patients with DFSP by molecular diagnostic testing using fluorescent in situ hybridization (FISH) or multiplex reverse transcription polymerase chain reaction, which is extremely helpful in the differential diagnosis of patients with DFSP-FS without areas of conventional DFSP. The result of this rearrangement is upregulation of a COL1A1-PDGFB fusion protein that is translated into a mature PDGF-BB homodimer, which activates the PDGFB receptor (PDGFRB), a protein tyrosine kinase acting as a potent growth factor.

These mechanisms contribute directly to development and growth of DFSP and also of giant-cell fibroblastoma, which is considered the juvenile form of DFSP.^[11]

Some molecular drugs act directly on tyrosine kinases, such as the tyrosine kinase inhibitor (TKI) imatinib (Gleevec). Gleevec works by inhibiting the kinase of PDGFRB, in addition to acting on other tyrosine kinase receptors, such as BCR-ABL, PDGF receptor α and c-kit, which revolutionized the treatment of chronic myeloid leukemia and gastric GIST. Thus, through this tyrosine kinase inhibition mechanism, tumor angiogenesis is also inhibited.^[11]

There are some consistent reports of complete clinical remission in patients with metastatic DFSP with the use of imatinib, making the drug a viable alternative in the neoadjuvant treatment of DFSP in cases of unresectable or recurrent tumors.^[11-15]

In the present study, a case of dermatofibrosarcoma protuberans with local recurrence after surgical treatment will be reported, subsequently treated with imatinib in combination with a new surgical approach, with no new recurrences so far.

CASE REPORT

In October 2018, a 51-year-old male patient sought a specialized oncology service for a lesion on the dorsum of the left foot, affecting the fourth and fifth toes. The patient had a history of multiple resections in the left foot in another service due to a DFSP already diagnosed.

On clinical examination, a lesion measuring 9x8cm was observed, with an infiltrating and multinodular tumor, brownish in color, with atrophic areas and telangiectasia (Figure 1A). Biopsy revealed fusiform cell proliferation with a storiform pattern, characteristic of DFSP (Figure 2). Immunohistochemistry was positive for CD34 and negative for CD117, ASMA, and S100. During staging, there was no evidence of metastases, configuring only local recurrence.

The initial proposal for treatment with transmetatarsal amputation, which may require extension for disarticulation (Chopart or Lisfranc), was not accepted by the patient.

Thus, neoadjuvant treatment with imatinib 800mg/day was started, with reassessment every 4 weeks regarding treatment acceptance, as well as blood count control, electrolyte dosage, liver function and renal function. From the fourth week of imatinib onwards, a progressive reduction in tumor size was observed (Figure 1B). The patient had a good response, complete acceptance and minimal toxicity, without adverse effects or drug resistance, as may occur in some cases with the use of tyrosine kinase inhibitors.

After 64 weeks of imatinib, the patient had a partial response to treatment, with a residual lesion measuring 2.7x4.7cm in MRI of the left foot (Figure 1C). Therefore, the surgical schedule was chosen in March 2020. However, on March 11, 2020, the World Health Organization declared the beginning of the coronavirus pandemic.

After a multidisciplinary discussion, it was decided to maintain the neoadjuvant treatment for another 18 weeks of treatment with imatinib, since the risks for COVID-19 were extremely high for the patient.

After this period, a complete clinical response to treatment was evidenced (Figure 1D). We then opted for resection of the remaining tumoral lesion.

On July 10, 2020, the patient underwent resection surgery for dermatofibrosarcoma protuberans on the dorsum of the left foot using the Mohs micrograph technique, with minimum margins of 1cm (Figure 3A) and reconstruction with grafting by the plastic surgery team (Figure 3B).

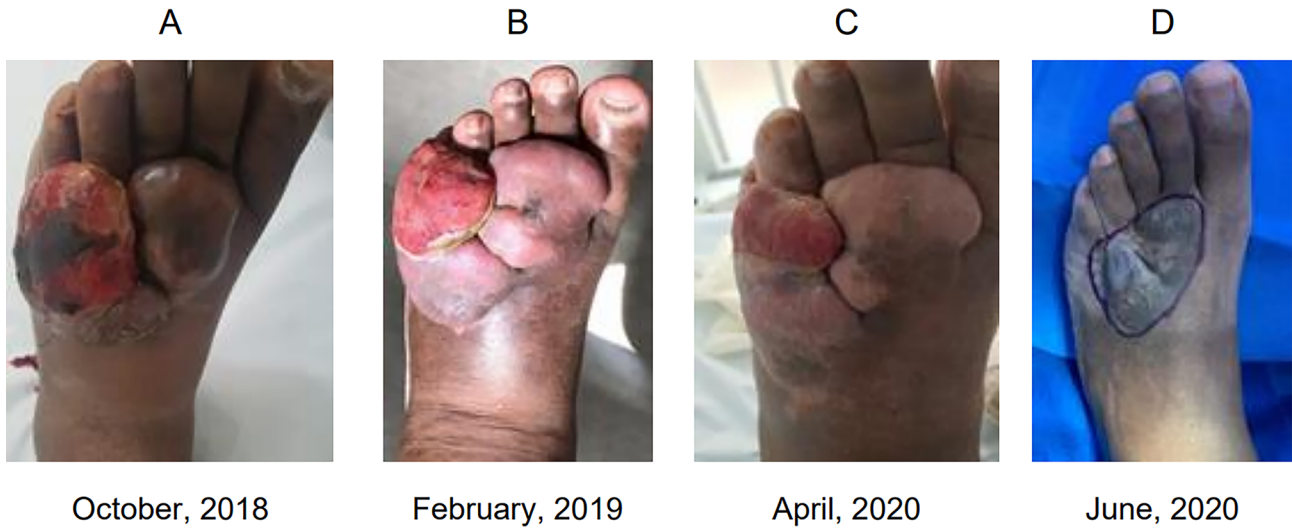


Figure 1. lesion on the dorsum of the left foot. A: recurrent lesion, prior to starting Imatinib B: 4 weeks after starting Imatinib C: 64 weeks after starting Imatinib D: 82 weeks after starting Imatinib. Opted for surgical treatment.

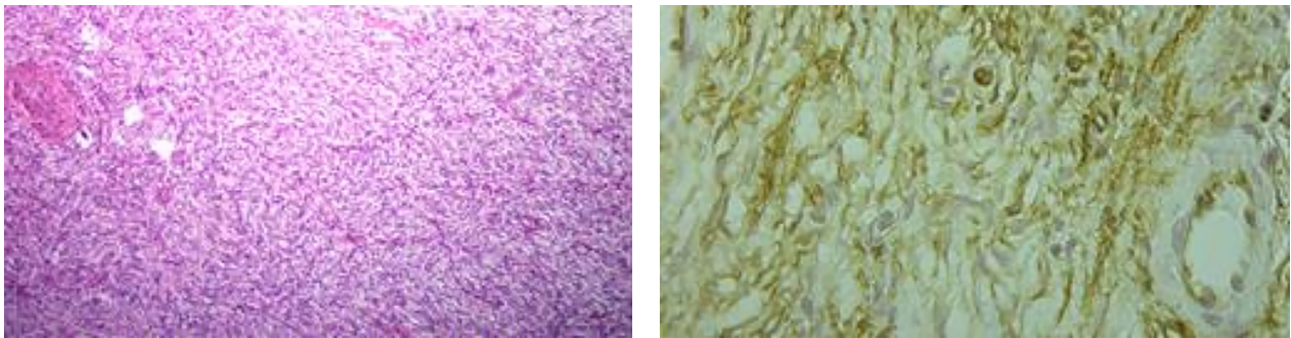
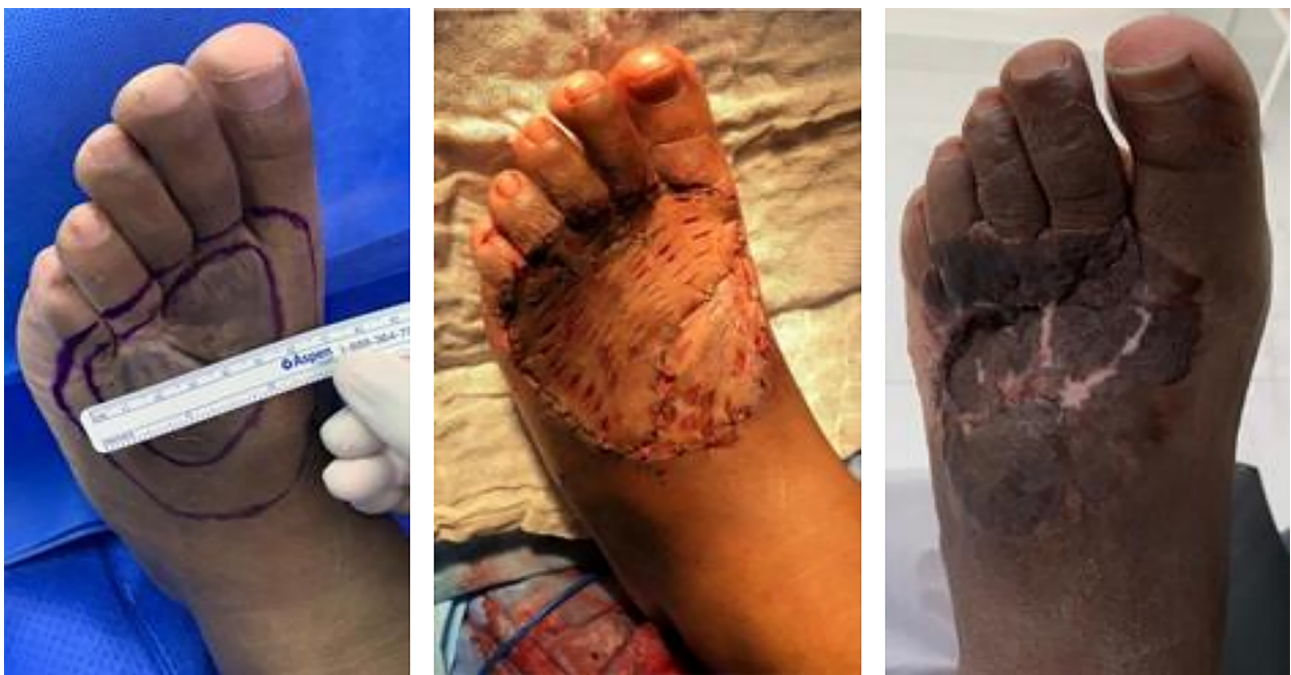

Figure 2. spindle cell neoplasm, with storiform arrangement, forming a coil and exhibiting slight to moderate variation in nuclear diameters and volumes. Mitosis figures are present, with areas of necrosis and hyalinization of the neoplastic stroma. CD34 positive.



Surgical margins 1 cm

Immediate postoperative

12 months of follow-up

Figure 3. images from intraoperative and postoperative A: surgical margins 1 cm B: immediate postoperative C: 1 year of follow-up, no recurrence of disease

The macroscopic pathological examination revealed a light brown tissue color, measuring 10x7x-2cm (Figure 4). On microscopic examination (Figure 5), the sections showed skin with thickened epidermis due to acanthosis and hyperkeratosis, with proliferation of spindle cells. Immunohistochemistry was positive for AML (smooth muscle actin), 1A4, CD34, CD68, desmin, factor XIIa, and EP3372. Cytological atypia and mitotic activity were considered non-significant, with no necrosis. Thus, the immunohistochemical panel defined it as a sclerosing skin lesion, with foci of proliferation of inflammatory cells, fibroblasts and blood vessels of different sizes, concluding absence of malignancy in the surgical specimen and complete clinical response to imatinib.

After 1 year of follow-up, the patient had no disease recurrence (Figure 3C).




Figure 4. surgical specimen

DISCUSSION

DFSP's main characteristic is its ability to invade adjacent tissues and spread over considerable distances. Tumor cells invade the subcutaneous tissue in trabecular projections through subcutaneous septa. Thus, due to this peculiar characteristic of dissemination and its rarity, associated with a delay in diagnosis, inadequate surgical resections often occur. The risk of local recurrence in a simple resection with conservative surgical margins is around 50%, being even greater in cases with a positive surgical margin.^[1,2,16-18]

In cases of local recurrence, a new surgical resection can be performed. However, recurrent tumors are more prone to deep invasion of fascia, muscle and bone, which increases the risk of mutilating surgery. Furthermore, recurrence is more associated with distant metastases.^[1,6,19,20]

According to the protocol of the National Comprehensive Cancer Network (NCCN),^[21] as well as established by a European Interdisciplinary Group,^[22] a surgical margin of 2 to 4cm is recommended in order to investigate fascia, muscle involvement or periosteum, with a complete pathological margin, when feasible. However, in practice, such margins are rarely executed, since, in most cases, they can lead to functional or cosmetic damage, especially in challenging areas such as the head and neck.

Mohs micrographic surgery (MMS) is widely used for large DFSP resections in areas of difficult anatomical approach or relapses. A sequential horizontal section of the tumor is performed during surgery, with immediate microscopic examination of the tissue, through frozen section analysis. In addition, immunohistochemistry is also performed at this time. Surgical resection is continued until free margins are obtained in the surgical specimen.

Through micrographic surgery of Mohs, there is a high probability of total removal of DFSP, since this procedure ensures resection with free margins from neoplasia.^[18,23-31] However, there are no randomized clinical trials proving the superiority of Mohs surgery over conventional surgical resection.

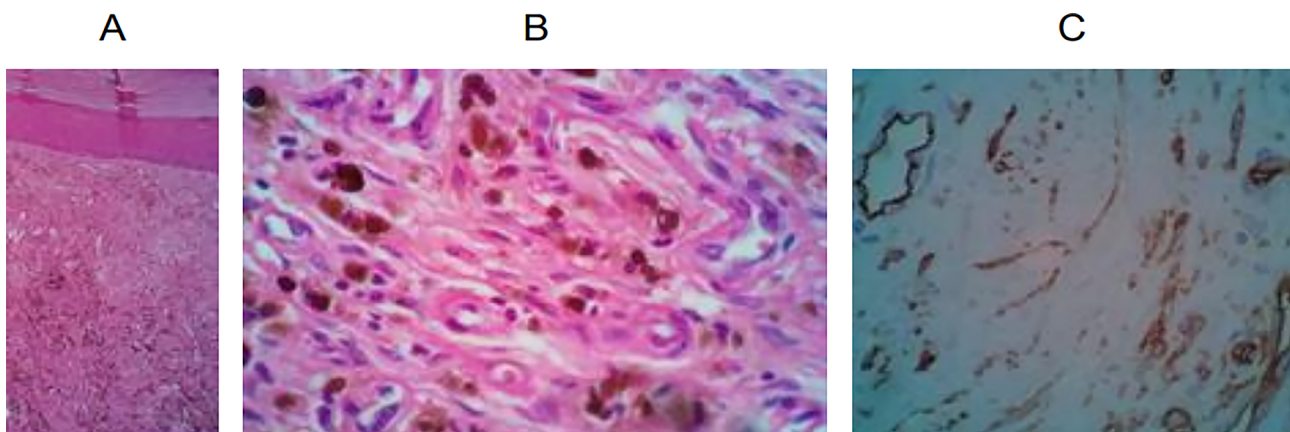


Figure 5. Tumor resection slides with immunohistochemistry and HE staining. Evidence of reparative fibroblast proliferation, without residual neoplasia.

Furthermore, the lack of long-term follow-up studies of patients is also a limiting factor, as most relapses occur approximately three years after surgery.^[32]

Despite the high probability of total tumor removal in DFSP, handling of unresectable or metastatic cases remains a challenge.

Imatinib is a drug approved in the United States and Europe for the treatment of unresectable, relapsed, or metastatic DFSP in adults. It is indicated as an alternative to radiotherapy, often used in these difficult-to-approach cases, providing a much less aggressive posterior surgical approach, with curative potential.

Some reports in the literature of complete clinical response in patients with metastatic DFSP aroused interest in the use of imatinib as neoadjuvant therapy, especially in unresectable or relapsed cases.^[11-15]

In a phase 2, German multicenter study, 16 patients with locally advanced (79%) or relapsed DFSP (21%) received imatinib (600mg/day) as neoadjuvant therapy for at least 6 weeks. In the twelfth week, surgical management or maintenance of imatinib was chosen in each case. Treatment was suspended in cases of disease progression or intolerable side effects.^[13]

At week 12, there were 7 patients with partial response, 5 with stable disease and only 2 with disease progression. Of the 14 patients included in the study, complete surgical resection with free margins was performed in 13 patients, with a mean of 3.1 months of previous use of imatinib. One patient achieved complete clinical response after 16.7 months of imatinib and did not undergo surgical treatment. In the anatomopathological study, 5 out of 11 analyzed had the mutation COL1A1-PDGFB+. However, there was no association between such genetic alteration and tumor response to imatinib. In a mean follow-up period of 6.4 years, only one patient developed resistance to imatinib, with tumor recurrence after surgical resection.^[13]

In a French phase 2 trial to assess neoadjuvant imatinib, 25 adults with DFSP (20 with primary tumor and 5 with recurrent lesions) were evaluated. Patients received two months of imatinib (600mg/day) prior to surgery.^[93] COL1A1-PDGFB fusion was detected in 21 of the 25 patients analyzed. There was a clinical response in 9 patients (36%) and the study concluded that a longer duration of neoadjuvant therapy would have been more beneficial in these cases, with little reported treatment toxicity.

The optimal dose and duration of imatinib therapy is still uncertain. Several phase 2 studies regarding neoadjuvant imatinib are currently being conducted, and eligible patients should be encouraged to participate in these studies.^[33,34]

In 2020, an extremely rare case of vulvar dermatofibrosarcoma measuring 5x11cm was reported. The neoplasm extended to the wall of the vagina, however, without metastatic involvement on imaging exams.^[35]

Therefore, due to its difficult location to approach and the extent of the lesion, treatment with imatinib 400mg daily for 7 months was chosen. After pharmacological therapy, the patient had considerable regression of the residual lesion tumor (2x4cm), after undergoing left hemivulvectomy with left inguinal lymphadenectomy. In the pathological examination, the lesion was compatible with dermatofibrosarcoma with free margins and without lymph node involvement, thus signifying a positive response to imatinib.^[35]

Although cases of neoadjuvant DFSP with other tyrosine kinase inhibitors that target the PDGF receptor, such as sunitinib, sorafenib and pazopanib, are reported in the literature, data from larger trials is still limited.^[36-38]

A French multicenter phase 2 study, based at nine centers at French universities evaluated the use of pazopanib as an alternative therapy to DFSP. Inclusion criteria were patients with histology confirming unresectable DFSP, which could be primary, relapsed or metastatic.^[38]

The study concluded that pazopanib could be a therapeutic option, with good clinical response, however, with poor tolerability to the drug and poor response when compared to studies with imatinib. The involvement of the EGFR pathway in DFSP suggests additional strategies and deserves further investigation in future studies.^[38]

Therefore, it can be found in literature that imatinib has been an option in some cases of DFSP, especially in those with difficult surgical approach, such as related in this study.

CONCLUSION

In the case presented here, the effectiveness of imatinib is noted in a deep, infiltrative and relapsed DFSP, in which upfront surgery would cause significant functional and cosmetic damage. Imatinib at the standard dose allowed an important clinical improvement for the patient, with tumor reduction in the initial weeks of treatment.

The drug was well tolerated, with minimal toxicity and absence of resistance, as reported in some cases, allowing the continued maintenance of treatment. The tumor boundary reduction permitted by imatinib allowed the subsequent performance of surgery with R-0 resection, with a surgical specimen free of neoplasm tissue.

Due to the COVID-19 pandemic and lack of availability for surgery, imatinib use was inadvertently prolonged, which led to an excellent local disease control response.

In summary, imatinib has been a well-tolerated therapy, playing an essential role in the neoadjuvant therapy of initially unresectable tumors and may be a therapy of choice in DFSP.

Future larger scale clinical trials are needed to determine the ideal neoadjuvant treatment time and the ideal tyrosine kinase inhibitors to be used; however, imatinib has been a promising option in these cases.

REFERENCES

- Bowne WB, Antonescu CR, Leung DH, Katz SC, Hawkins WG, Woodruff JM, et al. Dermatofibrosarcoma protuberans: a clinicopathologic analysis of patients treated and followed at a single institution. *Cancer*. 2000 Jun;88(12):2711-20.
- Rutgers EJ, Kroon BB, Albus-Lutter CE, Gortzak E. Dermatofibrosarcoma protuberans: treatment and prognosis. *Eur J Surg Oncol*. 1992 Jun;18(3):241-8.
- Bergin P, Rezaei S, Lau Q, Coucher J. Dermatofibrosarcoma protuberans, magnetic resonance imaging and pathological correlation. *Australas Radiol*. 2007;51(spe):B64-6.
- Thornton SL, Reid J, Papay FA, Vidimos AT. Childhood dermatofibrosarcoma protuberans: role of preoperative imaging. *J Am Acad Dermatol*. 2005 Jul;53(1):76-83.
- Torreggiani WC, Al-Ismail K, Munk PL, Nicolaou S, O'Connell JX, Knowling MA. Dermatofibrosarcoma protuberans: MR imaging features. *AJR Am J Roentgenol*. 2002 Apr;178(4):989-93.
- Khatri VP, Galante JM, Bold RJ, Schneider PD, Ramsamooj R, Goodnight Junior JE. Dermatofibrosarcoma protuberans: reappraisal of wide local excision and impact of inadequate initial treatment. *Ann Surg Oncol*. 2003 Nov;10(9):1118-22.
- Chang CK, Jacobs IA, Salti GI. Outcomes of surgery for dermatofibrosarcoma protuberans. *Eur J Surg Oncol*. 2004 Apr;30(3):341-5.
- Fiore M, Miceli R, Mussi C, Lo Vullo S, Mariani L, Lozza L, et al. Dermatofibrosarcoma protuberans treated at a single institution: a surgical disease with a high cure rate. *J Clin Oncol*. 2005 Oct;23(30):7669-75.
- Stojadinovic A, Hoos A, Karpoff HM, Leung DHY, Antonescu C, Brennan MF, et al. Soft tissue tumors of the abdominal wall: analysis of disease patterns and treatment. *Arch Surg*. 2001 Jan;136(1):70-9.
- Behbahani R, Patenotre P, Capon N, Martinot-Duquennoy V, Kulik JF, Piette F, et al. To a margin reduction in the dermatofibrosarcoma protuberans? Retrospective study of 34 cases. *Ann Chir Plast Esthet*. 2005 Jun;50(3):179-85.
- Rutkowski P, Van Glabbeke M, Rankin CJ, Ruka W, Rubin BP, Debiec-Rychter M, et al. Imatinib mesylate in advanced dermatofibrosarcoma protuberans: pooled analysis of two phase II clinical trials. *J Clin Oncol*. 2010 Apr;28(10):1772-9.
- McArthur GA, Demetri GD, Van Oosterom A, Heinrich MC, Debiec-Rychter M, Corless CL, et al. Molecular and clinical analysis of locally advanced dermatofibrosarcoma protuberans treated with Imatinib: Imatinib Target Exploration Consortium Study B2225. *J Clin Oncol*. 2005 Feb;23(4):866-73.
- Ugurel S, Mentzel T, Utikal J, Mohr P, Pfoehler C, Schiller M, et al. Neoadjuvant imatinib in advanced primary or locally recurrent dermatofibrosarcoma protuberans: a multicenter phase II DeCOG trial with long-term follow-up. *Clin Cancer Res*. 2014 Jan;20(2):499-510.
- Rutkowski P, Dębiec-Rychter M, Nowecki Z, Michej W, Symonides M, Ptaszynski K, et al. Treatment of advanced dermatofibrosarcoma protuberans with Imatinib mesylate with or without surgical resection. *J Eur Acad Dermatol Venereol*. 2011 Mar;25(3):264-70.
- Kérob D, Porcher R, Vérola O, Dalle S, Maubec E, Aubin F, et al. Imatinib mesylate as a preoperative therapy in dermatofibrosarcoma: results of a multicenter phase II study on 25 patients. *Clin Cancer Res*. 2010 Jun;16(12):3288-95.
- Suit H, Spiro I, Mankin HJ, Efid J, Rosenberg AE. Radiation in management of patients with dermatofibrosarcoma protuberans. *J Clin Oncol*. 1996 Aug;14(8):2365-9.
- Terrier-Lacombe MJ, Guillou L, Maire G, et al. Dermatofibrosarcoma protuberans, giant cell fibroblastoma, and hybrid lesions in children: clinicopathologic comparative analysis of 28 cases with molecular data—a study from the French Federation of Cancer Centers Sarcoma Group. *Am J Surg Pathol*. 2003 Jan;27(1):27-39.
- Lemm D, Mügge LO, Mentzel T, Höffken K. Current treatment options in dermatofibrosarcoma protuberans. *J Cancer Res Clin Oncol*. 2009 May;135(5):653-65.
- Mentzel T, Beham A, Katenkamp D, Dei Tos AP, Fletcher CD. Fibrosarcomatous ("high-grade") dermatofibrosarcoma protuberans: clinicopathologic and immunohistochemical study of a series of 41 cases with emphasis on prognostic significance. *Am J Surg Pathol*. 1998 May;22(5):576-87.
- Arnaud EJ, Perrault M, Revol M, Servant JM, Banzet P. Surgical treatment of dermatofibrosarcoma protuberans. *Plast Reconstr Surg*. 1997 Sep;100(4):884-95.
- National Comprehensive Cancer Network (NCCN). NCCN clinical practice guidelines in oncology [Internet]. Plymouth Meeting: NCCN; 2021; [access in 2021 May 06]. Available from: https://www.nccn.org/professionals/physician_gls
- Saiag P, Grob JJ, Lebbe C, Malvehy J, Del Marmol V, Pehamberger H, et al. Diagnosis and treatment of dermatofibrosarcoma protuberans. European consensus-based interdisciplinary guideline. *Eur J Cancer*. 2015 Nov;51(17):2604-8.
- Gloster Junior HM, Harris KR, Roenigk RK. A comparison between Mohs micrographic surgery and wide surgical excision for the treatment of dermatofibrosarcoma protuberans. *J Am Acad Dermatol*. 1996 Jul;35(1):82-7.
- DuBay D, Cimmino V, Lowe L, Johnson TM, Sondak VK. Low recurrence rate after surgery for dermatofibrosarcoma protuberans: a multidisciplinary approach from a single institution. *Cancer*. 2004 Mar;100(5):1008-16.
- Snow SN, Gordon EM, Larson PO, Bagheri MM, Bentz ML, Sable DB. Dermatofibrosarcoma protuberans: a report on 29 patients treated by Mohs micrographic surgery with long-term follow-up and review of the literature. *Cancer*. 2004 Jul;101(1):28-38.
- Wacker J, Khan-Durani B, Hartschuh W. Modified Mohs micrographic surgery in the therapy of dermatofibrosarcoma protuberans: analysis of 22 patients. *Ann Surg Oncol*. 2004 Apr;11(4):438-44.

27. Nouri K, Lodha R, Jimenez G, Robins P. Mohs micrographic surgery for dermatofibrosarcoma protuberans: University of Miami and NYU experience. *Dermatol Surg*. 2002 Nov;28(11):1060-4.
28. Robinson JK. Dermatofibrosarcoma protuberans resected by Mohs' surgery (chemosurgery). A 5-year prospective study. *J Am Acad Dermatol*. 1985 Jun;12(6):1093-8.
29. Ratner D, Thomas CO, Johnson TM, Sondak VK, Hamilton TA, Nelson BR, et al. Mohs micrographic surgery for the treatment of dermatofibrosarcoma protuberans. Results of a multiinstitutional series with an analysis of the extent of microscopic spread. *J Am Acad Dermatol*. 1997 Oct;37(4):600-13.
30. Haycox CL, Odland PB, Olbricht SM, Casey B. Dermatofibrosarcoma protuberans (DFSP): growth characteristics based on tumor modeling and a review of cases treated with Mohs micrographic surgery. *Ann Plast Surg*. 1997 Mar;38(3):246-51.
31. Nelson RA, Arlette JP. Mohs micrographic surgery and dermatofibrosarcoma protuberans: a multidisciplinary approach in 44 patients. *Ann Plast Surg*. 2008 Jun;60(6):667-72.
32. Foroozan M, Sei JF, Amini M, Beauchet A, Saiag P. Efficacy of Mohs micrographic surgery for the treatment of dermatofibrosarcoma protuberans: systematic review. *Arch Dermatol*. 2012 Sep;148(9):1055-63.
33. Sarcoma Alliance for Research through Collaboration. Neoadjuvant imatinib in DFSP. *ClinicalTrials.gov* [Internet]. 2005; [access in 2012 Nov 01]. Available from: <http://clinicaltrials.gov/ct2/show/NCT00243191?term=00243191&rank=1>
34. A short course of neoadjuvant Gleevec (Imatinib mesylate) in DFSP (NCT 00176709). *ClinicalTrials.gov* [Internet]. ANO; [access in 2012 Nov 01]. Available from: <http://clinicaltrials.gov/ct2/results?term=00176709>
35. Merlo G, Cozzani E, Comandini D, Trave I, Centurioni MG, Franchelli S, et al. Neoadjuvant imatinib as treatment preceding surgery for vulvar dermatofibrosarcoma protuberans. *Dermatol Ther*. 2021 Mar;34(2):e14860. DOI: <https://doi.org/10.1111/dth.14860>
36. Kamar FG, Kairouz VF, Sabri AN. Dermatofibrosarcoma protuberans (DFSP) successfully treated with sorafenib: case report. *Clin Sarcoma Res*. 2013;3:5.
37. Ong HS, Ji T, Wang LZ, Yu ZW, Zhang CP. Dermatofibrosarcoma protuberans on the right neck with superior vena cava syndrome: case report and literature review. *Int J Oral Maxillofac Surg*. 2013;42(6):707-10.
38. Delyon J, Porcher R, Battistella M, Meyer N, Adamski H, Bertucci F, et al. A multicenter phase II study of pazopanib in patients with unresectable dermatofibrosarcoma protuberans. *J Invest Dermatol*. 2021 Sep;141(4):761-9.e2.