

Accuracy of ultrasound-guided fine needle aspiration cytology (US-FNAC) to detect axillary involvement in breast cancer

Acurácia da citologia de punção aspirativa por agulha fina (PAAF) guiada por ultrassonografia na detecção do comprometimento axilar pelo câncer de mama

Maria Carolina Gouveia¹, Candice Lima Santos², Isabel Cristina Pereira¹, Ariani Impieri Souza³

ABSTRACT

Introduction: Axillary involvement is one of the main prognostic factors in breast cancer. This study aimed to assess the accuracy of ultrasound-guided fine needle aspiration cytology (US-FNAC) to detect axillary involvement in breast cancer and to compare with other methods of axilla assessment: axillary palpation (AP) and isolated axillary ultrasound (A-US). **Methods:** A retrospective accuracy study was performed using data from medical records of patients assisted at a breast cancer service in Recife, Brazil, between 2013 and 2017. A histopathological result (sentinel lymph node and/or axillary dissection) was adopted as a gold standard. Sensitivity, specificity, accuracy, positive predictive value (PPV) and negative predictive value (NPV) of the AP, the A-US and US-FNAC were calculated. **Results:** 206 tumors were analyzed. The AP was truly positive in 34.0% of the results similar values were obtained for A-US (36.4%). The lowest incidence of false negative was in the US-FNAC (16.5%). Axillary involvement was identified in 82 (39.8%) cases. The US-FNAC was performed in 79 cases, 51 (64.5%) were identified as true positive and 13 (16.5%) were false negative. When analyzing the comparative results of AP, A-US and the US-FNAC of the axilla with histopathology, it was observed that AP presented an accuracy of 69.9% (95%CI=63.1-76.1), better than the A-US, which its accuracy was 68% (95%CI=61.1-74.3). The US-FNAC showed high specificity (100%, 95%CI=81.9-100%), of PPV at 100% (95%CI=94.3-100%), but with a low NPV (53.6%, 95%CI=33.9-72.5). The best NPV was the AP (59.7%, 95%CI=50.5-68.4). The US-FNAC accuracy was 83.5% (95%CI=73.5-91.0). **Conclusion:** The good accuracy associated to the high specificity and the PPV of the US-FNAC suggests it to be a promising examination in the diagnosis of axillary involvement in breast cancer and an ally to better define therapeutic conducts.

Keywords: Neoplasias mamárias; Biópsia com agulha fina; Terapia neoadjuvante; Linfonodo sentinela.

1. Instituto de Medicina Integral Prof. Fernando Figueira (IMIP), Breast surgery - Recife - Pernambuco - Brazil

2. Instituto de Medicina Integral Prof. Fernando Figueira (IMIP), Oncology - Recife - Pernambuco - Brazil

3. Instituto de Medicina Integral Prof. Fernando Figueira (IMIP), Gynecology - Recife - Pernambuco - Brazil

Financial support: none to declare.

Conflicts of interest: The authors declare no conflict of interest relevant to this manuscript.

Correspondence author: Maria Carolina Gouveia.

E-mail: carolinaggoliveira@gmail.com

Received on: July 2, 2020 | **Accepted on:** November 6, 2020 | **Published on:** January 18, 2021

DOI: <https://doi.org/10.5935/2526-8732.20200044>

RESUMO

Introdução: O envolvimento axilar é um dos principais fatores prognósticos no câncer de mama. Este estudo teve como objetivo avaliar a acurácia da citologia aspirativa por agulha fina guiada por ultrassom (AAF-US) para detectar envolvimento axilar no câncer de mama e comparar com outros métodos de avaliação da axila: palpação axilar (PA) e ultrassom axilar isolado (US-A). **Métodos:** Foi realizado um estudo retrospectivo de acurácia com dados de prontuários de pacientes atendidas em um serviço de câncer de mama no Recife, Brasil, entre 2013 e 2017. O resultado histopatológico (linfonodo sentinela e/ou dissecação axilar) foi adotado como padrão ouro. Sensibilidade, especificidade, acurácia, valor preditivo positivo (VPP) e valor preditivo negativo (VPN) do AP, o US-A e o AAF-US foram calculados. **Resultados:** Foram analisados 206 tumores. O PA foi verdadeiramente positivo em 34,0% dos resultados, valores semelhantes foram obtidos para US-A (36,4%). A menor incidência de falso negativo foi no AAF-US (16,5%). Envolvimento axilar foi identificado em 82 (39,8%) casos. O AAF-US foi realizado em 79 casos, 51 (64,5%) foram identificados como verdadeiro positivo e 13 (16,5%) falso negativo. Ao analisar os resultados comparativos do PA, US-A e o AAF-US da axila com a histopatologia, observou-se que o PA apresentou uma acurácia de 69,9% (IC95%=63,1-76,1), melhor que o US-A, cuja acurácia foi de 68% (IC95%=61,1-74,3). O AAF-US mostrou alta especificidade (100%, IC95%=81,9-100%), com VPP em 100% (IC95%=94,3-100%), mas com um baixo VPN (53,6%, IC95%=33,9-72,5). O melhor VPN foi o PA (59,7%, IC95%=50,5-68,4). A acurácia do AAF-US foi de 83,5% (IC95%=73,5-91,0). **Conclusão:** A boa acurácia associada à alta especificidade e ao VPP do AAF-US sugere que este seja um exame promissor no diagnóstico de acometimento axilar no câncer de mama e um aliado para definir melhores condutas terapêuticas.

Descritores: Neoplasias mamárias; Biópsia com agulha fina; Terapia neoadjuvante; Linfonodo sentinela.

INTRODUCTION

Breast cancer is the most common cancer among women. Approximately 2 million women each year are diagnosed with breast cancer and it is responsible for approximately 15% of female cancer deaths in the world.^[1]

When cancer is diagnosed in the early stages, it is considered as good prognosis, having greater chances of cure. Although it is much studied, there is still no universal consensus for screening, diagnosis, treatment, and follow-up on breast cancer. The prognosis is defined by several factors such as age, staging and tumor characteristics.^[2-4]

Axillary involvement is one of the main prognostic factors in breast cancer. For decades, axillary dissection (AD) has been the method of choice for assessing and treating axillary metastases, as well as making decisions in relation to systemic therapy.^[5-7] Sentinel lymph node biopsy (SLNB) was consolidated as a method of choice for the study of these metastases in patients with clinically negative axilla, with low local recurrence rate, without altering survival, resulting in less morbidity.^[6,8-10]

In 40-65% of the cases in which SLNB has positive findings for malignancy, the sentinel lymph node is the only one involved, therefore, AD is not necessarily indicated and its role in this scenario remains uncertain.^[11-14] Studies have demonstrated

the benefit of AD omission in selected patients, even SLNB with evidence of metastasis.^[11-14]

Axilla ultrasound (A-US) alone has moderate sensitivity and specificity in identifying lymph nodes with metastatic involvement, when combined with fine needle aspiration cytology (US-FNAC), this becomes a more accurate method.^[5,6,15-18]

Histopathological assessment after neoadjuvant systemic therapy (performed before surgery), allows to know the response of a determined tumor in this therapy. A complete pathological response (absence of residual disease in the histopathology examination of the surgical specimen) is related to a lower chance of relapse and has better prognosis.^[19,20] Evidence points that the US-FNAC when performed before the neoadjuvant therapy, can be helpful in identifying lymph nodes with a higher degree of involvement, facilitating the option to perform or not the axillary dissection after neoadjuvant therapy, but its role is not completely defined yet.^[10,21-24]

This present study aims to assess the accuracy of US-FNAC to detect axillary involvement in breast cancer and to compare with other methods of axilla assessment, as AP and A-US alone.

METHODS

This is a retrospective study of accuracy, which used the information collected from the medical records

of patients with breast cancer treated at the breast cancer service at the Instituto de Medicina Integral Prof. Fernando Figueira (IMIP), in Recife, Brazil, from June 2013 to December 2017.

The following inclusion criteria were considered: to have invasive breast carcinoma diagnostic, to have axillary histopathological result registered in the medical records and have been treated at IMIP. As exclusion criteria were considered: metastatic disease and tumors with skin or chest wall involvement.

Patients were selected through registries books in which were admitted with suspected or confirmed diagnosis of breast cancer at the breast cancer department at the institution. A consecutive and convenience sample was used. First, we planned to analyze all the patients with breast cancer in the study period, however, we were not able to find all these medical records. Of 1,091, 491 medical records were found.

All the selected patients underwent the A-US. The lymph nodes were defined suspicious when one of the following characteristics was observed: cortical thickness >2mm, eccentric cortical thickening, loss of fatty hilum and round shape. US-FNAC of suspected lymph nodes was performed by one of the breast radiologists from our service, with at least, 2 years of experience.

For the FNA, a 22-gauge needle was inserted into the cortex of the ALN using a manual aspiration. Collected material was analyzed by a breast pathologist. Cytology was considered positive when neoplastic cells were identified.

To identify sentinel lymph nodes, the radioisotopes method was used (38% of the procedures) or blue dye (62% of the procedures), according to availability of the service. The radioisotope (technetium-99m phytate) was injected before surgery, about 2 hours, and the blue dye was applied at the time of the surgery, 10 minutes before axillary incision. ALNs identified by a gamma probe or axillary lymph nodes containing blue dye were regarded as sentinel nodes and removed. Axillary dissection was performed on patients who underwent neoadjuvant chemotherapy; one and two Berg's levels were assessed.

The variables analyzed were sociodemographic data, tumor characteristics and diagnostic tests: AP, A-US and the US-FNAC. The histopathology examination (of SLNB and/or AD) was considered as gold standard for this study. The information was collected from the medical records and entered in an *Excel™* database. The data were reviewed, corrected and submitted to cleaning and consistency tests, before the statistical analysis.

Stata 12.1 was used for data analysis. Records with insufficient data were excluded from the analysis. Frequency tables were created for the categorical variables. For the methods of axilla assessment (AP, A-US and US-FNAC): sensitivity, specificity, accuracy, positive predictive value (PPV) and negative predictive value (NPV) were calculated as

95% confidence interval. The *kappa* coefficient was calculated to assess the agreement between the methods, considering the Landis and Koch (1977)^[25] criteria to classify the strength of association: slight (0-0.20); fair (0.21-0.40); moderate (0.41-0.60); substantial (0.61-0.80); almost perfect (0.81-1).

RESULTS

After reviewing 491 medical records of women suspected or diagnosed with breast cancer, were excluded: 9 cases with histopathological result prior to the selected period of the study, 65 patients had no sufficient information on their medical files for analysis, 25 cases were diagnosed with benign disease, 24 cases of ductal in situ carcinoma, 5 cases of primary tumor in other areas with metastasis in the breast, 24 cases of tumor with skin and/or chest wall involvement, 40 cases due to metastatic disease, 12 performed treatment outside IMIP, and 83 tumors with no residual disease after neoadjuvant chemotherapy without previous axillary histopathology. Thus, 204 women's medical records were analyzed, 2 of them had bilateral tumor, totaling the analysis of 206 tumors as shown in Figure 1.

Patients and tumor characteristics in the overall study population are in Table 1.

The women's mean age was 56 (SD=12.5) years old and the majority (81.6%) were from Recife and adjacent cities.

In relation to the tumor size, 123 (59.7%) tumors found were between 2.1 and 5cm, in AP and 116 (56.0%) were between 2.1 and 5cm in the A-US. The prevalent histological type was invasive ductal carcinoma (IDC) in 170 (82.5%) cases. Regarding to the tumor nuclear grade, grade II tumors prevailed in 114 (55.0%) cases. Most of the tumors presented positive hormone receptor: estrogen receptor (ER) in 153 (74.3%) and progesterone receptor (PR) in 132 (64.1%) tumors. Thirty-two (15.5%) tumors were triple negative and 45 (21.8%) had HER-2 overexpression (this category included patients with pure HER-2 positive and those with HER-2 positive is associated to positive hormone receptor). The clinical stage (CS) II was the most prevalent (69.9%) for all age groups.

The AP was truly positive, in other words, capable of detecting lymph node involvement in 34.0% of the cases and truly negative in 36.0%, similar values were obtained for A-US (36.4% and 31.5%, respectively). The lowest incidence of false negative was in the US-FNAC (16.5%). Axillary involvement was identified in 82 (39.8%) cases, while in the ultrasound, 96 (46.6%) were identified. The US-FNAC was performed in 79 cases (which were positive according to the ultrasound), and 51 (64.5%) were identified as true positive and 13 (16.5%) were false negative (Table 2).

When analyzing the comparative results of AP, A-US and the US-FNAC of the axilla with gold standard (histopathology), it was observed that AP presented the lowest sensitivity (58.3%, 95%CI=49-67.3),

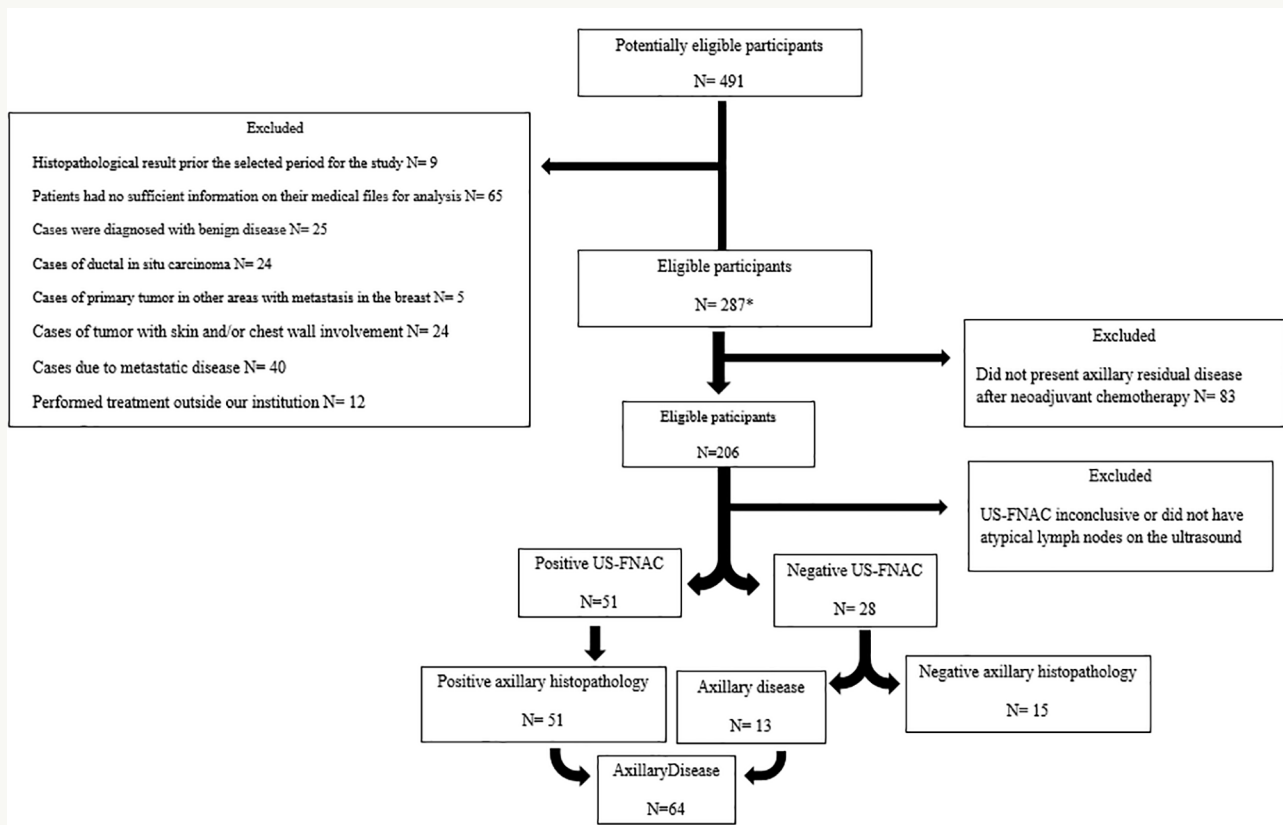


Figure 1. Patients' flowchart.

however, with an accuracy of 69.9% (95%CI=63.1-76.1), it was better than the A-US, whose accuracy was 68% (95%CI=61.1-74.3). The US-FNAC showed high specificity (100%, 95%CI=81.9-100%), of PPV at 100% (95%CI=94.3-100%), but with low NPV (53.6%, 95%CI=33.9-72.5). The best NPV was AP (59.7%, 95%CI=50.5-68.4), followed by A-US (59.1%, 95%CI=49.3-68.4). The US-FNAC accuracy was 83.5% (95%CI=73.5-91.0) (Table 3).

The results of concordance analysis with the *kappa* coefficient had shown moderate agreement (0.60; 95%CI=0.42-0.78) between US-FNAC and histopathology. The *kappa* coefficient of the AP and histopathology was also moderate (0.42; 95%CI=0.30-0.53) and between A-US and histopathology was fair (0.37; 95%CI=0.24-0.49) (Table 4).

DISCUSSION

To design a profile of the studied patients, it was possible to perceive that the most came from the State capital of Pernambuco and adjacent neighboring cities, an expected fact, since these patients have better access to the health service, when compared to those residing in the countryside. The mean age was over 50-years-old, a similar data also found in other studies and it was compatible with the age group risk known worldwide.^[1,26,27]

The most prevalent histological subtype of the tumors assessed was the IDC, followed by the ILC, a similar result is described in the literature.^[17,27-29] The prevalence of tumors with HER-2 overexpression found in this study

did not differ from what has been described on this category, about 20% of the tumors.^[27-29]

Staging and therapeutic planning are of a paramount importance in patients with breast cancer, since the identification of axillary lymph node involvement can change the options of offering clinical or surgical treatment.^[30,31]

The AP is the oldest method used to assess axillary lymph node involvement in breast cancer. In this present study, AP had an accuracy of approximately 70%, with sensitivity of approximately 60% and specificity of 86%, values comparable to those described in the literature, although previous studies have shown a lower sensitivity for AP between 30-40%.^[30,32] This difference could be related to the professionals' experience who have performed AP.^[30,32] The necessity for clinical experience is the main factor limiting the physical axilla examination, reported as the most difficult to differ enlarged lymph nodes from the reactive inflammatory or metastatic involvement.^[30,33,34]

In the present study, the A-US presented accuracy of 68.0% and sensitivity of around 60%, similar results found for AP, however, with a sensitivity discreetly higher than the values described in the literature, which are around 50%.^[30,35]

The US-FNAC is a cost effective and fast performance method and has been used in several services with the objective of defining the axillary involvement of the patient with breast cancer. So, this procedure

Table 1. Patients and tumors characteristics in women with breast cancer assisted at the breast cancer service at IMIP, Recife, Brazil, 2013-2017.

Variables ^w	N=206	%
Age (years) - Mean (SD*) = 56 (±12.5)		
Live in Recife and adjacent cities	167	81.6
Marital status		
In relationship	94	46.6
Not in relationship	106	51.5
No information	6	2.9
Tumor size at axilla palpation (AP)		
≤2cm	41	19.9
2.1-5cm	123	59.7
>5cm	42	20.4
Tumor size on the ultrasound (US)		
≤2cm	76	37.0
2.1-5cm	116	56.0
>5cm	12	6.0
No information	2	1.0
Histological type		
Invasive ductal carcinoma (IDC)	170	82.5
Invasive lobular carcinoma (ILC)	11	5.4
Others	25	12.1
Nuclear tumor grade		
I	35	17.0
II	114	55.0
III	43	21.0
No information	14	7.0
Immunohistochemistry**		
Estrogen receptor	153	74.3
Progesterone receptor	132	64.1
HER-2 overexpression	45	21.8
Triple negative	32	15.5
Clinical staging		
I	29	14.1
II	144	69.9
III***	33	16.0

*Standard deviation; **The same tumor may have more than one immunohistochemical classification; *** Predominated in women under 40-years-old.

could avoid the necessity of a surgical procedure, such as SLNB, and the delay of a possible systemic treatment, due to surgical complications.^[19,36,37]

When the US-FNAC was performed, the diagnosis was improved by an accuracy of around 84%, compared to the values already described in the literature.^[34,38]

Dihge et al. (2016)^[15] in a hospital-based study in Sweden, from 2009 to 2012, 473 women found a

Table 2. Comparative results of AP, A-US and US-FNAC with a gold standard (histopathology) in the diagnosis of axillary involvement due to breast cancer in women assisted at the breast cancer service at IMIP, Recife, Brazil, 2013-2017.

Exam	True (+) N (%)	True (-) N (%)	False (+) N (%)	False (-) N (%)
AP (n=206)	70 (34.0%)	74 (36.0%)	12 (5.8%)	50 (24.3%)
A-US (n=206)	75 (36.4%)	65 (31.5%)	21 (10.2%)	45 (21.8%)
US FNAC (n=79)	51 (64.5%)	15 (19.0%)	0 (0.0%)	13 (16.5%)

AP = Axillary palpation; A-US = Axillary ultrasound; US-FNAC = Ultrasound-guided fine needle aspiration cytology.

sensitivity of 23% and specificity of 95% of the A-US, however, when associated to the US-FNAC, presented improvement on the diagnostic sensitivity, reaching a sensitivity of 73%. This result was close to what was found in the present study, which was 79.7%. Both studies had PPV of 100%, a value which was already described in other studies.^[15,33,34]

The US-FNAC significantly improves the PPV, although, its use is limited, as, in order to perform the test, it is necessary that the suspected lymph node be visualized in the ultrasound and accessible for the puncture, which often reduces the number of patients undergoing this procedure. Of the 473 women who performed the ultrasound on the axilla from Dihge et al. (2016)^[15] study, 55 presented lymph nodes with suspicious characteristics and only 45 underwent the US-FNAC. In this present study, of the 206 patients submitted to the A-US, only 96 had lymph nodes with suspicious characteristics, of which 79 were submitted to the US-FNAC. Despite a high PPV, the high numbers of false negatives (n=13, 16.5%) make the negative examination incapable of excluding the axillary lymph node metastasis.^[11,22,39]

The SLNB has a false-negative rate of around 10-12%, a value that makes it a safe procedure to exclude axillary metastases in breast cancer, considered as gold standard in patients with clinically negative axilla.^[11,22,23,39] Currently, even lower sentinel node false negative rates of around 8% are expected.^[39,40]

This present study showed, by *kappa*, moderate agreement between the results of the US-FNAC and the histopathology, associated to a high PPV. Thus, the inclusion of the US-FNAC as a routine for breast cancer staging helps identify patients who are candidates for neoadjuvant therapies, without the necessity of a surgical procedure, and offers the possibility of a conservative treatment in the axilla, according to the response to this therapy.^[19,23,36,40-42]

When indicated, neoadjuvant therapy has the advantage in permitting the physician to assess the tumor response *in vivo*^[15,19,23] and enables early treatment for micro-metastases, besides, decreasing the risk of delaying systemic treatment due to surgical complications. It also allows time to program and

Table 3. Sensitivity, specificity, accuracy and predictive values of the AP, A-US and US-FNAC with a gold standard (histopathology) in the diagnosis of axillary involvement in breast cancer in women assisted at the breast cancer service at IMIP, Recife, Brazil, 2013-2017.

Exam	Sensitivity % (95%CI)	Specificity % (95%CI)	Accuracy % (95%CI)	PPV % (95%CI)	NPV % (95%CI)
AP (n=206)	58.3 (49.0-67.3)	86.0 (76.9-92.6)	69.9 (63.1-76.1)	85.4 (75.9-92.2)	59.7 (50.5-68.4)
A-US (n=206)	62.5 (53.2-71.2)	75.6 (65.1-84.2)	68.0 (61.1-74.3)	78.1 (68.5-85.9)	59.1 (49.3-68.4)
US-FNAC (n=79)	79.7 (67.8-88.7)	100.0 (81.9-100.0)	83.5 (73.5-91.0)	100.0 (94.3-100.0)	53.6 (33.9-72.5)

AP = Axillary palpation; A-US = Axillary ultrasound; US-FNAC = Ultrasound-guided fine needle aspiration cytology; PPV = Positive predictive value; NPV = Negative predictive value.

Table 4. Level of agreement between AP, A-US and US-FNAC, with the gold standard (histopathology) in the diagnosis of breast cancer in women assisted at the breast cancer service at IMIP, Recife, Brazil, 2013-2017.

Exams	Kappa value (95%CI)	Strength of association*
AP vs. HTP	0.42 (0.30-0.53)	Moderate
A-US vs. HTP	0.37 (0.24-0.49)	Fair
US-FNAC vs. HTP	0.60 (0.42-0.78)	Moderate

individualize the best procedure with or without immediate breast reconstruction for each patient.^[5,15,23,43]

For the analysis of specificity, sensitivity, accuracy, PPV and NPV, patients who underwent neoadjuvant chemotherapy and who obtained axillary histopathology after chemotherapy without any evidence of residual disease were excluded, because in these cases, the axilla could be negative due to a good response to systemic therapy, causing a bias both in identifying false positives and identifying true negatives through the US-FNAC.

The role of the sentinel lymph node when negative is already well established in the literature and it is known that in these cases there is no benefit of the axillary dissection.^[43] However, much is still discussed about the role of axillary dissection when the sentinel lymph node is positive. The Giuliano et al. (2010)^[12] study, which demonstrated that there was no additional benefit with the axillary dissection for selected patients undergoing conservative surgery and up to two compromised sentinel lymph nodes, have changed the conducts throughout the world. Thus, identifying patients as candidates for conservative axilla surgery, even with positive sentinel lymph node, is still a challenge.^[5,44]

The Boughey et al. (2013)^[23] study demonstrated the possibility of performing the sentinel lymph node biopsy after neoadjuvant chemotherapy, safely, when well indicated and using the appropriate technique.^[23]

Among the limitations of this study, it is mentioned that the fact was performed with the data collected

from the medical records, which may not contain all the information properly registered, limiting the sample. Another limitation of this study is that, of the 160 patients who underwent neoadjuvant chemotherapy, 83 did not present axillary residual disease. Of these patients, 67 had positive US-FNAC for neoplasia before the neoadjuvant chemotherapy, of these, 23 showed no evidence of axillary disease after systemic therapy. This result may mean that these 23 patients responded well to chemotherapy and could become candidates for less morbidity surgery if the SLNB was performed after the neoadjuvant therapy.^[23,45]

Much has been evolved in relation to breast cancer. Treatments that were once considered gold standard, but with an important morbidity, which were replaced by less aggressive techniques and with fewer side effects for the patients. In this scenario, it is possible that the US-FNAC is an important ally in the diagnosis of axillary involvement in breast cancer without the necessity of a surgical procedure, thus allowing the option of an early systemic treatment with a possibility of reducing axillary tumor burden.^[36] In properly selected patients, the use of US-FNAC may result in a less aggressive axillary surgical treatment.

Identifying patients with axillary involvement without a surgical procedure is of a great value to better define the therapeutic plan.

CONCLUSION

The good accuracy associated to the high specificity and the PPV of the US-FNAC suggests this to be a promising examination in the diagnosis of axillary involvement in breast cancer and an ally to better define therapeutic conducts.

ACKNOWLEDGEMENTS

We would like to thank Professor José Natal Figueirôa for his contribution on the statistical analysis.

Ethical approval

This research was approved by the Research Ethics Committee at IMIP (CAAE number: 81475317.5.0000.5201).

Funding details

There was no funding support.

Disclosure statement

All the authors declared no conflicts of interests.

REFERENCES

1. World Health Organization (WHO). Preventing cancer [Internet]. Geneva: WHO; 2018; [access in 2019 Apr 12]. Available from: <https://www.who.int/cancer/prevention/diagnosis-screening/breast-cancer/en/>
2. Barke LD, Freivogel ME. Breast cancer risk assessment models and high-risk screening. *Radiol Clin North Am.* 2017 May;55(3):457-74.
3. Kuhl CK, Strobel K, Bieling H, Leutner C, Schild HH, Schrading S. Supplemental breast MR imaging screening of women with average risk of breast cancer. *Radiology.* 2017 May;283(2):361-70.
4. Ray KM, Price ER, Joe BN. Evidence to support screening women in their 40s. *Radiol Clin North Am.* 2017 May;55(3):429-39.
5. Del Riego J, Diaz-Ruiz MJ, Teixidó M, Ribé J, Vilagran M, Canales L, et al. The impact of axillary ultrasound with biopsy in overtreatment of early breast cancer. *Eur J Radiol.* 2018;98:158-64.
6. Park KU, Caudle A. Management of the axilla in the patient with breast cancer. *Surg Clin North Am.* 2018 Aug;98(4):747-60.
7. Boniface J, Frisell J, Andersson Y, Bergkvist L, Ahlgren J, Rydén L, et al. Survival and axillary recurrence following sentinel node-positive breast cancer without completion axillary lymph node dissection: the randomized controlled SENOMAC trial. *BMC Cancer.* 2017 May;17:379.
8. Van Der Ploeg IMC, Nieweg OE, Van Rijk MC, Olmos RAV, Kroon BBR. Axillary recurrence after a tumour-negative sentinel node biopsy in breast cancer patients: a systematic review and meta-analysis of the literature. *Eur J Surg Oncol.* 2008 Dec;34(12):1277-84.
9. Pelosi E, Bellò M, Giors M, Ala A, Giani R, Bussone R, et al. Sentinel lymph node detection in patients with early-stage breast cancer: comparison of periareolar and subdermal/peritumoral injection techniques. *J Nucl Med.* 2004 Mar;45(2):220-5.
10. Krag DN, Anderson SJ, Julian TB, Brown AM, Harlow SP, Constantino JP, et al. Sentinel-lymph-node resection compared with conventional axillary-lymph-node dissection in clinically node-negative patients with breast cancer: overall survival findings from the NSABP B-32 randomised phase 3 trial. *Lancet Oncol.* 2010 Oct;11(10):927-33.
11. Moorman AM, Bourez RLJH, Heijmans HJ, Kouwenhoven EA. Axillary ultrasonography in breast cancer patients helps in identifying patients preoperatively with limited disease of the axilla. *Ann Surg Oncol.* 2014 Sep;21(9):2904-10.
12. Giuliano AE, McCall L, Beitsch P, Whitworth PW, Blumencranz P, Leith AM, et al. Locoregional recurrence after sentinel lymph node dissection with or without axillary dissection in patients with sentinel lymph node metastases: the American College of Surgeons Oncology Group Z0011 randomized trial. *Ann Surg.* 2010 Sep;252(3):426-32;discussion:432-3.
13. Donker M, Van Tienhoven G, Straver ME, Meijnen P, Van de Velde CJH, Mansel RE, et al. Radiotherapy or surgery of the axilla after a positive sentinel node in breast cancer (EORTC 10981- 22023 AMAROS): a randomised, multicentre, open-label, phase 3 non-inferiority trial. *Lancet Oncol.* 2014 Nov;15(12):1303-10.
14. Straver ME, Meijnen P, Van Tienhoven G, Van de Velde CJH, Mansel RE, Bogaerts J, et al. Sentinel node identification rate and nodal involvement in the EORTC 10981-22023 AMAROS trial. *Ann Surg Oncol.* 2010 Jul;17(7):1854-61.
15. Dihge L, Grabau DA, Rasmussen RW, Bendahl PO, Rydén L. The accuracy of preoperative axillary nodal staging in primary breast cancer by ultrasound is modified by nodal metastatic load and tumor biology. *Acta Oncol.* 2016 Aug;55(8):976-82.
16. Reyna C, Lee MC, Frelick A, Kahkpour N, Laronga C, Kiluk JV. Axillary burden of disease following false-negative preoperative axillary evaluation. *Am J Surg.* 2014 Oct;208(4):577-81.
17. Ministério da Saúde (BR). Secretaria de Atenção à Saúde. Portaria conjunta nº 19, de 03 de julho de 2018. Diretrizes diagnósticas e terapêuticas do carcinoma de mama. *Diário Oficial da União, Brasília (DF), 03 jul 2018; Seção 1: 1-40.*
18. National Comprehensive Cancer Network (NCCN). NCCN clinical practice guidelines in oncology (NCCN Guidelines®). Breast cancer [Internet]. Plymouth: NCCN; 2019; [access in ANO Mês dia]. Available from: https://www.nccn.org/professionals/physician_gls/pdf/breast.pdf
19. Reyal F, Hamy A, Piccart MJ. Neoadjuvant treatment: the future of patients with breast cancer. *ESMO Open.* 2018 May;3(4):e000371.
20. Tadros AB, Yang WT, Krishnamurthy S, Rauch GM, Smith BD, Valero V, et al. Identification of patients with documented pathologic complete response in the breast after neoadjuvant chemotherapy for omission of axillary surgery. *JAMA Surg.* 2017 Jul;152(7):665-70.
21. Boland MR, Prichard RS, Daskalova I, Lowery AJ, Evoy D, Geraghty J, et al. Axillary nodal burden in primary breast cancer patients with positive pre-operative ultrasound guided fine needle aspiration cytology: management in the era of ACOSOG Z011. *Eur J Surg Oncol.* 2015 Apr;41(4):559-65.
22. Kuehn T, Bauerfeind I, Fehm T, Fleige B, Hausschild M, Helms G, et al. Sentinel-lymph-node biopsy in patients with breast cancer before and

- after neoadjuvant chemotherapy (SENTINA): a prospective, multicentre cohort study. *Lancet Oncol*. 2013 Jun;14(7):609-18.
23. Boughey JC, Suman VJ, Mittendorf EA, Ahrendt GM, Wilke LG, Taback B, et al. Sentinel lymph node surgery after neoadjuvant chemotherapy in patients with node-positive breast cancer: the ACOSOG Z1071 (Alliance) clinical trial. *JAMA*. 2013 Oct;310(14):1455-61.
 24. Choi HJ, Kim I, Alsharif E, Park S, Kim JM, Ryu JM, et al. Use of sentinel lymph node biopsy after neoadjuvant chemotherapy in patients with axillary node-positive breast cancer in diagnosis. *J Breast Cancer*. 2018 Dec;21(4):433-41.
 25. Landis JR, Koch GG. The measurement of observer agreement for categorical data. *Biometrics*. 1977 Mar;33(1):159-74.
 26. Ministério da Saúde (BR). Instituto Nacional de Câncer (INCA). Tipos de câncer. Câncer de mama [Internet]. Brasília (DF): Ministério da Saúde/INCA; 2018; [access in 2019 Mar 16]. Available from: <https://www.inca.gov.br/tipos-de-cancer/cancer-de-mama>
 27. Farina A, Almeida LLR, Paula LEJ, Medeiros RV, Silva MR, Somavilla SB. Perfil epidemiológico, clínico, anátomo patológico e imunohistoquímico das pacientes com câncer de mama em Cuiabá (MT). *Rev Bras Mastologia*. 2017 Jan/Mar;27(1):74-9.
 28. Magalhães G, Brandão-Souza C, Fustinoni SM, Matos JC, Schirmer J. Clinical, sociodemographic and epidemiological profile of woman with breast cancer. *Fundamental Care Online*. 2017 Apr;9(2):473-9.
 29. Borges GS, Rebelo JR, Maman KAS, Zabel MCJ, Almeida AM, Custodio GS, et al. Perfil epidemiológico dos pacientes portadores de câncer de mama atendidos em um ambulatório de mastologia da região do vale do Itajaí. *Rev Bras Oncol Clin*. 2013 Sep;9:88-92.
 30. Valente SA, Levine GM, Silverstein MJ, Rayhanabad JA, Weng-Grumley JG, Ji L, et al. Accuracy of predicting axillary lymph node positivity by physical examination, mammography, ultrasonography, and magnetic resonance imaging. *Ann Surg Oncol*. 2012 Jun;19(6):1825-30.
 31. Leenders MWH, Broeders M, Croese C, Richir MC, Go HLS, Langenhorst BLAM, et al. Ultrasound and fine needle aspiration cytology of axillary lymph nodes in breast cancer. To do or not to do?. *Breast*. 2012 Aug;21(4):578-83.
 32. Pamilo M, Soiva M, Lavast EM. Real-time ultrasound, axillary mammography, and clinical examination in the detection of axillary lymph node metastases in breast cancer patients. *J Ultrasound Med*. 1989;8(3):115-20.
 33. Feng Y, Huang R, He Y, Lu A, Fan ZQ, Fan T, et al. Efficacy of physical examination, ultrasound, and ultrasound combined with fine-needle aspiration for axilla staging of primary breast cancer. *Breast Cancer Res Treat*. 2015 Feb;149(3):761-5.
 34. Alvarez S, López F, Alonso I, López F, Alonso I, Cortés J. Role of sonography in the diagnosis of axillary lymph node metastases in breast cancer: a systematic review. *AJR Am J Roentgenol*. 2006 May;186(5):1342-8.
 35. Barco I, Chabrera C, García-Fernández A, Fraile M, González S, Canales L, et al. Role of axillary ultrasound, magnetic resonance imaging, and ultrasound-guided fine-needle aspiration biopsy in the preoperative triage of breast cancer patients. *Clin Transl Oncol*. 2017 Jun;19(6):704-10.
 36. Gipponi M, Fregatti P, Garlaschi A, Murelli F, Margarino C, Depaoli F, et al. Axillary ultrasound and fine-needle aspiration cytology in the preoperative staging of axillary node metastasis in breast cancer patients. *Breast*. 2016 Dec;30:146-50.
 37. O'Leary DP, O'Brien O, Relihan N, McCarthy J, Ryan M, Barry J, et al. Rapid on-site evaluation of axillary fine-needle aspiration cytology in breast cancer. *Br J Surg*. 2012 Jun;99(6):807-12.
 38. Brancato B, Crocetti E, Bianchi S, Catarzi S, Risso GG, Bulgaresi P, et al. Accuracy of needle biopsy of breast lesions visible on ultrasound: audit of fine needle versus core needle biopsy in 3233 consecutive samplings with ascertained outcomes. *Breast*. 2012 Aug;21(4):449-54.
 39. Cody HS. Current surgical management of breast cancer. *Curr Opin Obst Gynecol*. 2002 Feb;14(1):45-52.
 40. Corso G, Scalzi AM, Vicini E, Morigi C, Veronesi P, Galimberti V. Sentinel lymph node biopsy management after neoadjuvant treatment for breast cancer care. *Future Oncol*. 2018 Jun;14(15):1423-6.
 41. Yu Y, Cui N, Li HY, Wu YM, Xu L, Fang M, et al. Sentinel lymph node biopsy after neoadjuvant chemotherapy for breast cancer: retrospective comparative evaluation of clinically axillary lymph node positive and negative patients, including those with axillary lymph node metastases confirmed by fine needle aspiration. *BMC Cancer*. 2016;16(1):808.
 42. Schipper RJ, Van Roozendaal LM, Vries B, Pijnappel RM, Beets-Tan RGH, Lobbes MBI, et al. Axillary ultrasound for preoperative nodal staging in breast cancer patients: is it of added value?. *Breast*. 2013 Dec;22(6):1108-13.
 43. Bromham N, Schmidt-Hansen M, Astin M, Hasler E, Reed MW. Axillary treatment for operable primary breast cancer. *Cochrane Database Syst Rev*. 2017 Jan;1(1):CD004561.

44. Giuliano AE, Ballman K, McCall L, Beitsch P, Whitworth PW, Blumencranz P, et al. Locoregional recurrence after sentinel lymph node dissection with or without axillary dissection in patients with sentinel lymph node metastases: long-term follow-up from the American College of Surgeons Oncology Group (Alliance) ACOSOG Z0011 randomized trial. *Ann Surg.* 2016 Sep;264(3):413-20.
45. Mamounas EP. Timing of determining axillary lymph node status when neoadjuvant chemotherapy is used. *Curr Oncol Rep.* 2014 Feb;16(2):364.