

# Vesiculobullous Paraneoplastic Dermatomyositis: A Case Report and Review of the Literature

Dermatomiosite vesiculobolhosa paraneoplásica: relato de caso e revisão da literatura

Nurimar Conceição Fernandes<sup>1</sup>, Roberta de Oliveira Boabaid<sup>2</sup>

## ABSTRACT

Paraneoplastic vesiculobullous dermatomyositis is a rare disease characterized by proximal myopathy and typical cutaneous lesions which appear in a patient diagnosed with a malign neoplasia. In the present case, dermatomyositis developed four months after the detection of a breast carcinoma (T3N0M0) followed by radical mastectomy and lymph node dissection. A clinical favourable response to prednisone was observed although the coexistence of an active internal malignancy have been detected in the follow-up (an asynchronous left breast carcinoma and a primitive endometrial cancer).

**Keywords:** Dermatomyositis. Myositis. Breast Neoplasms.

1. Hospital Universitario Clementino Fraga Filho - UFRJ, Associate professor - Dermatology Service - Rio de Janeiro - RJ - Brazil.

2. Hospital Universitario Clementino Fraga Filho - UFRJ, Specialization Course in Dermatology - Dermatology Service - Rio de Janeiro - RJ - Brazil.

**Financial support:** none to declare.


**Conflicts of interest:** The authors declare no conflict of interest relevant to this manuscript.

**Correspondence author:** Nurimar Conceição Fernandes, Hospital Universitario Clementino Fraga Filho - UFRJ, Associate professor - Dermatology Service - Rio de Janeiro - RJ - Brazil.

E-mail: nurimarfernandes@terra.com.br

**Received on:** January 24, 2020 | **Accepted on:** June 7, 2020 | **Published on:** Apr 7, 2022

**DOI:** <https://doi.org/10.5935/2526-8732.20220123>

 This work is licensed under a Creative Commons Attribution-NonCommercial-ShareAlike 4.0 International License. (<http://creativecommons.org/licenses/by-nc-sa/4.0/>).

## INTRODUCTION

Adult-onset dermatomyositis (DM) is an idiopathic inflammatory myopathy frequently associated with underlying cancer including breast, ovary, lung and cervix carcinoma. Many consider dermatomyositis a paraneoplastic syndrome, as up to 32% of patients with the disease will develop cancer<sup>(1)</sup>. The characteristic skin findings are heliotrope sign, Gottron's papules and poikyloderma. Vesicle formation in DM is rare and occurs mainly in women from 50 to 70 years old. The bullous lesions develop mainly on extensor surfaces of arms, knees and thorax. About 68% of cases are in association with malign neoplasia of ovarian, breast, lungs, colon, stomach, uterus and nasopharynx<sup>(2)</sup>. The diagnosis is established on criteria of classic DM and vesiculobullous cutaneous rash. The histopathological features of subepidermal bullae and dermal edema, lymphocytic infiltrate and mucin deposit are not specific<sup>(3)</sup>. The histopathology skin exam is not essential to the diagnosis. The etiology is still unknown<sup>(3)</sup>. Two cases of paraneoplastic vesiculobullous DM have been published from 2011 until now in females with breast cancer (Table 1). To our knowledge this is the first description of paraneoplastic vesiculobullous DM developed in the context of three carcinomas.

## CASE DESCRIPTION

Female, 54 years old, with right breast carcinoma diagnosed in July 2017; she was submitted to a radical right mastectomy and axillar ganglionic dissection in January 2018. The histopathological and immunohistochemical exams revealed an infiltrating carcinoma Grade III in association with intraductal carcinoma, intermediary degree with vascular and perineural invasion: ER+ 100%, PR+ 100%, HER- 2. Two sentinel lymph nodes free from neoplasia. Neither chemotherapy nor radiotherapy was added. In March 2018, she noticed erythema on face, thorax, abdomen and limbs, proximal arms and legs' weakness besides dysphagia to solids. The dermatological examination revealed heliotrope, Gottron sign, poikiloderma in the thorax, desquamative

erythematous plaques (gluteal areas, thighs) and vesiculobullous formation in the extremities (Figures 1,2 and 3). In June 2018, a booking consultation with oncologist who prescribed hormone therapy with anastrozole. The histopathology of bullous skin biopsy revealed spongiosis, dermoepidermal cleavage besides inflammatory infiltrate mainly lymphocytic and perivascular.

In July 2018, hospitalization with a clinical diagnosis of vesiculobullous dermatomyositis. The introduction of prednisone (1mg/kg/day), improved myositis, dysphagia and dysphonia in a period of three months of corticotherapy.

Initial laboratory findings: ESR= 68mm (normal: 20mm/h); LDH= 501U/l (normal: 140-271U/l); AST= 111U/l (normal: 10-35U/l); ALT= 64U/l (normal: 10-35U/l); CRP=9,6mg/l (normal: 0,1mg/l); CPK= 65U/l (normal: 10-145U/l). The aspartate aminotransferase (AST) and alanine aminotransferase (ALT) levels normalized but erythrocyte sedimentation rate (ESR) remained high after three months.

In January 2019, endometrial cancer (IIIC) was detected and treated by total abdominal hysterectomy plus salpingo-ooforectomy; adjuvant chemotherapy was started with carboplatin and paclitaxel (n=6).

In March 2019, left breast cancer was diagnosed (pT1No) and treated by segmentectomy; radiotherapy and tamoxifen are scheduled.

In October 2019, after a slow tapering the patient achieved a 10mg/day maintenance dose of prednisone, with complete remission of the skin lesions and myositis.

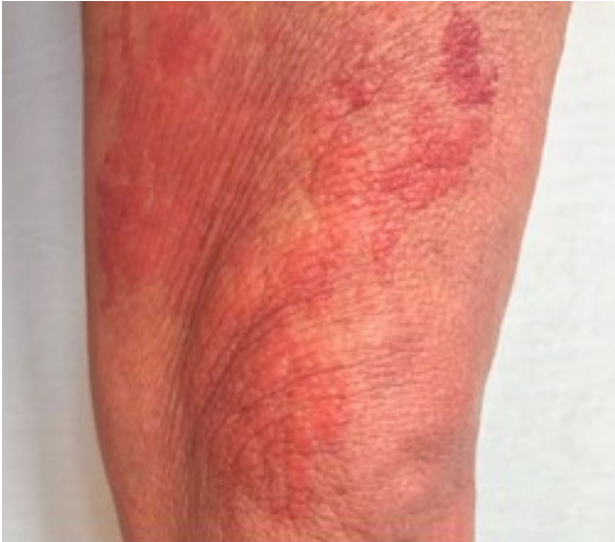The informed consent was obtained for publication of this case report.

## DISCUSSION

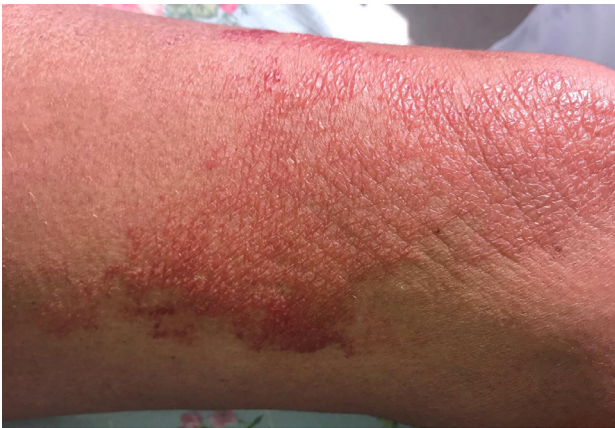Patients with pathognomonic skin rashes (heliotrope, Gottron's papules and/or Gottron sign of DM), are accurately classified with Euler/ACR criteria without muscle biopsy data (Figures 3, 4 and 5). For DM patients without muscle involvement, a skin biopsy is recommended<sup>(4,5)</sup>.

**Table 1.** Vesiculobullous paraneoplastic dermatomyositis: 2020 – 2011.

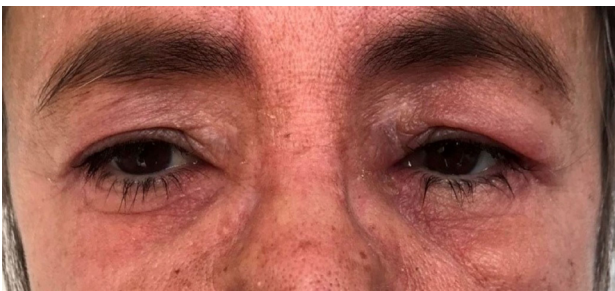Author	N°of cases	Gender		Age years	Clinical picture	Neoplasms	Treatment	Follow-up
		M	F					
XU/ 2012 <sup>(3)</sup>	1	M	-	47	DM vesiculobullous	nasopharyngeal carcinoma	radiotherapy chemotherapy corticoid	3 months
Caratta/ 2011 <sup>(8)</sup>	1	M	--	72	DM vesiculobullous	Prostate-carcinoma tongue carcinoma	radiotherapy corticoid chemotherapy	-
Mebazza/ 2011 <sup>(11)</sup>	2	--	F	47	DM vesiculobullous	breast carcinoma	surgery chemotherapy radiotherapy	35 months



**Figure 1.** Asymmetrical vesiculobullous lesions.

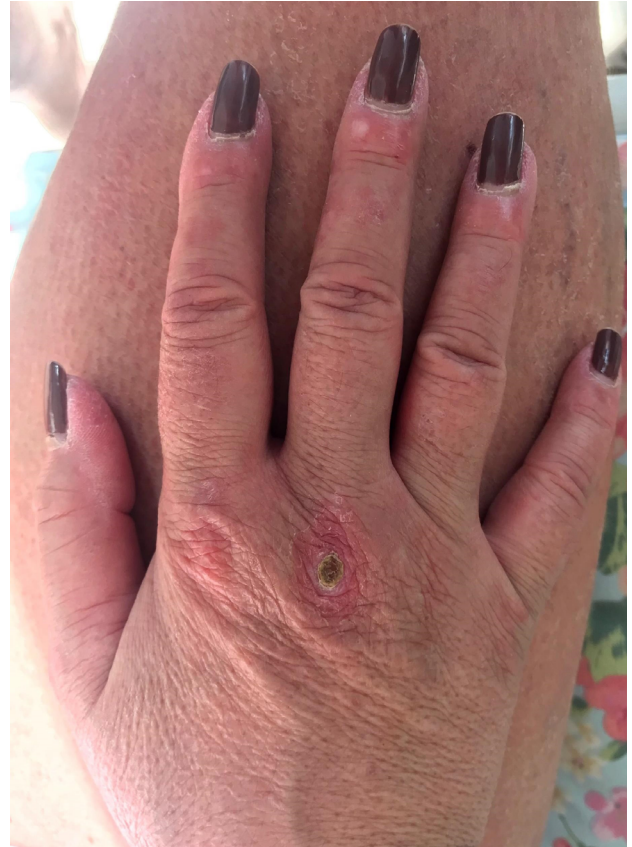

**Figure 2.** Asymmetrical vesiculobullous lesions.

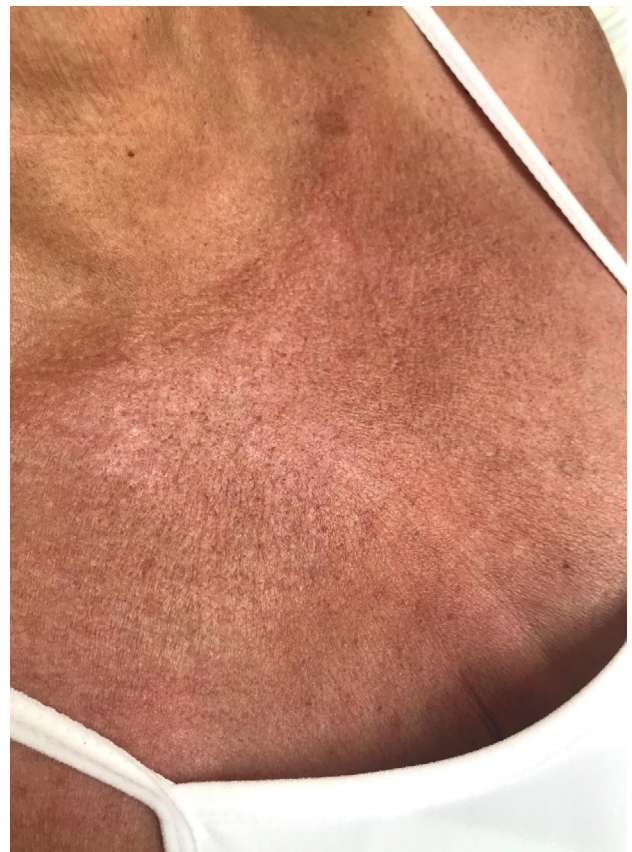

**Figure 3.** Violaceous erythema and edema (eyelids).

The presence of the hallmark cutaneous manifestations of DM, besides proximal muscle weakness (an objective evidence of muscle inflammation characteristic of DM) and the elevation in the level of AST and ALT (indicators of muscle disease activity in DM) established the diagnosis<sup>(4,5)</sup>. The histopathology of vesiculobullous DM is not specific; usually a subepidermal blister is seen along with dermal edema and mucin deposition; other bullous diseases such as lupus erythematosus, bullous pemphigoid, dermatitis herpetiformis were ruled out by histopathological features.



**Figure 4.** Gottron's sign and erythematous papule on the knuckles and interphalangeal joints of dorsal fingers.



**Figure 5.** Polkyoderma (thorax). Shawl sign.

Bullae may develop in LE as a manifestation of aggressive liquefactive degeneration of the epidermal basal layer, resulting in basal cell dissolution simulating histopathologic appearance of toxic epidermal necrolysis. Bullous pemphigoid reveals subepidermal blister with an inflammatory cell infiltrate containing eosinophils in the superficial dermis. Dermatitis herpetiformis (microabscess in the papillary tips) and pemphigus (acantholysis) are also considered in the differential diagnosis.

Symmetric myositis affects at first the muscle of pelvic girdle and afterwards the scapular girdle and later the neck flexural muscles in weeks or months. The involvement of the striated muscle of the hypopharynx and the upper third of the esophagus causes the dysphagia. An elevation in the level of serum CPK is sensitive and specific laboratory indicator of muscle disease activity but normal levels can be found even in case of active myositis<sup>(5)</sup>. The paraneoplastic DM presents more frequently vasculitis and develops less specific anti-myositis antibodies in comparison with DM without neoplasia<sup>(6)</sup>. The ANA is frequently positive in 80% of patients<sup>(7)</sup>. In the present case, the titer 1:640 became negative in the first three months of treatment.

Myositis-specific antisynthetase auto antibodies which anti-Jo1 is more frequently associated to lung interstitial disease, arthritis and Raynaud phenomenon<sup>(5)</sup>. In this case, anti-Jo1 and anti-M2 were non-reactive. The therapeutic plan for paraneoplastic DM should follow some principles: prednisone (1 mg/kg/day) is the first choice although some authors propose a lower dose (0.5mg/kg/day) plus topical corticoid and hydroxychloroquine (400mg/day) besides photoprotection<sup>(8)</sup> or even intravenously immunoglobulin (400mg/kg day for 5 days monthly)<sup>(9)</sup>. Some laboratory data are essential: levels of AST and ALT are expected to be normal in the seventh week; in the present case it occurred in the tenth week. The remission of cutaneous lesions, dysphonia and increasing proximal muscle force occurred after three months. The clinical improvement is the most reliable indicator of the therapeutic response. After clinical and laboratorial remission, prednisone can be tapered (5mg at weekly interval) till the maintenance dose (20mg) for one year<sup>(2)</sup>. The corticotherapy does not prolong the survival but increases the muscle force and preserves its function. The older age, the impairment of muscle force, the compromise of patient's general status are factors suggested to be associated with a poor prognosis and mortality in the first year<sup>(10)</sup>. A retrospective study of 13 cases of paraneoplastic DM in breast cancer revealed the following profile: the DM was diagnosed before cancer in three patients; both diagnoses at the same time in two and after in eight. Bullous lesions were observed in two patients and the survival from the diagnosis of DM was thirty – three months. The paraneoplastic DM can follow an independent course from neoplasia or a typical course of the syndrome<sup>(6,11,12,13)</sup>.

Synchronous breast cancer is detected simultaneously in both breasts before the first therapy; the asynchronous breast cancer is detected after cancer's diagnosis in one first affected breast in anytime. It can be primitive or metastatic. The criteria for primitive/metastatic tumor are variable, controversial and faulty. They are based upon histopathological types, distant presence or absence of metastasis and signs of local dissemination from the first compromised breast. According to the mentioned criteria both breast cancers were considered asynchronous and the endometrial cancer, a primitive one<sup>(14,15)</sup>.

The bibliographic review on the subject between 2020 and 2011 shows four cases of the vesiculobullous DM, with two breast cancers in women in the same age group as the case under description with a 35 - month follow-up. Corticoid was not prescribed for these cases (Table1)

## CONCLUSION

Because of the poor prognosis associated with malignancies, correct diagnosis and immediate search for potential underlying tumor is critical in patients with vesiculobullous DM.

## AUTHOR'S CONTRIBUTION

**Nurimar Conceição Fernandes:** Collection and assembly of data, Conception and design, Data analysis and interpretation, Final approval of manuscript, Manuscript writing, Provision of study materials or patient

**Roberta de Oliveira Boabaid:** Collection and assembly of data, Provision of study materials or patient

## REFERENCES

- Laidler NK. Dermatomyositis as a paraneoplastic phenomenon in oesophageal cancer. *BMJ Case report*. 2018; 11(1): e227387.doi:10.1136/bcr2018-227387
- Shen WC, Hsu CJ. Vesiculobullous dermatomyositis: case report and review of literature. *Dermatomyositis Sinica*. 2018; 36(3):169-70.
- Xu T, Hong S. A case of vesiculobullous dermatomyositis: a marker of internal malignancy. *Int J Dermatol*. 2012; 51(5):594-6.
- Leclair V, Lundberg IE. New myositis classification criteria-what we have learned since Bohan and Peter. *Curr Rheumatol Rep*. 2018; 20(4):18.
- Lundberg IE, Tjärnlund A, Bottai M, Werth VP, Pilkington C, de Visser M, et al. 2017 European League Against Rheumatism/American College of Rheumatology classification criteria for adult and juvenile idiopathic inflammatory myopathies and their major subgroups. *Arthritis Rheumatol*. 2017; 69(12):2271-82.
- Cardoso A, Gonçalves C. Dois casos de dermatomiosite: tão iguais e tão diferentes. *Med Int*. 2009; 16:117-23.

7. Castro AS, Barroso A, Parente B. Dermatomiosite como primeira manifestação de uma neoplasia pulmonar. *Rev Port Pneumol*. 2013; 19(4):179-83.
8. Caratta PR, Mafor T, Pamplona M, Schau B, Estrella RR. Dermatomiosite vesículobolhosa como manifestação paraneoplásica de tumores sincrônicos de próstata e língua: relato de caso. *Rev Bras Reumat*. 2011; 51(4):394-400.
9. Esposito ACC, Munhoz T, Ocanha JP, Miot HA. Syndrome in question. *An Bras Dermatol*. 2016; 91(3):387-9.
10. Zangrilli A, Papoutsaki M, Bianchi L, Teoli M, Chimenti S. Bullous dermatomyositis: a marker of poor prognosis and aggressive internal malignancy? *Acta Derm Venereol*. 2008; 88(4):393-4.
11. Mebazaa A, Boussen H, Nouira R, Gamoudi A, Rachal K. Dermatomyositis and breast cancer: a multicenter Tunisian retrospective study of 13 cases. *Tunis Med*. 2011; 89(1):18-22.
12. López Gamboa VR; Blanzan MJ, Sardoy A, Campana AV, Nocito MJ. Dermatomiositis paraneoplásica relacionada a cancer de mama: asociacion clínica en dos pacientes. *Rev Fac Med Univ Nac Cordoba*. 2015; 72(2):119-22.
13. Travassos AR, Borges-Costa J, Filipe P, Marques MS. Malignance associated with dermatomyositis a retrospective single-center study with 33 patients. *Acta Reumatol Port*. 2013; 38:92-7.
14. Cancer de Mama. Condutas do INCa/MS, INCA/MS – Procedures. *Rev Bras de Cancerol*. 2001; 47(1):9-19.
15. Garcia AM, Vuoto HD, Candás GB, González Zimmermann A, Uriburu JL, Isetta JAM, Cogorno L, Bernabó OL. Carcinoma de Mama Bilateral. *Rev argent mastologia*. 2009; 28(98):16-31.