

Complete laparoscopic resection of primary leiomyosarcoma of the lower vena cava

Ressecção laparoscópica completa de leiomiossarcoma primário da veia cava inferior

Roberto Heleno Lopes^{1,2} , Antônio Carlos Rodrigues do Nascimento³, Alexandre Ferreira Oliveira^{1,2}, Frederico Augustus Martins de Resende², João Baptista de Paula Fraga⁴, Isolino Geraldo Almeida^{5,6}

ABSTRACT

The inferior vena cava leiomyosarcoma is a rare type of retroperitoneal sarcoma. Due to the small number of cases reported in literature, there is no well-defined protocol, based on randomized studies, on the most appropriate treatment for this neoplasia. Studies show that surgical resection R0 is the main curative treatment. We report the case of a patient submitted to surgical R0 resection of leiomyosarcoma of inferior vena cava by videolaparoscopy with good evolution in the postoperative period.

Keywords: Laparoscopy; Leiomyosarcoma; Vena Cava, Inferior.

RESUMO

O leiomiossarcoma da veia cava inferior é um tipo raro de sarcoma retroperitoneal. Devido ao pequeno número de casos relatados na literatura, não existe um protocolo bem definido, baseado em estudos randomizados, sobre o tratamento mais adequado para essa neoplasia. Estudos mostram que a ressecção cirúrgica R0 é o principal tratamento curativo. Relatamos o caso de um paciente submetido à ressecção cirúrgica R0 de leiomiossarcoma de veia cava inferior por videolaparoscopia com boa evolução no pós-operatório.

Descritores: Laparoscopia; Leiomiossarcoma; Veia cava inferior.

1. Hospital of Federal University of Juiz de Fora, Department of Surgical Oncology - Juiz de Fora - Minas Gerais - Brazil.
2. Monte Sinai Hospital, Department of Oncology Surgery - Juiz de Fora - Minas Gerais - Brazil.
3. Hospital of Federal University of Juiz de Fora, Resident of General Surgery - Juiz de Fora - Minas Gerais - Brazil.
4. Monte Sinai Hospital, Department of Coloproctology - Juiz de Fora - Minas Gerais - Brazil.
5. Hospital of Federal University of Juiz de Fora, Department of vascular surgery - Juiz de Fora - Minas Gerais - Brazil.
6. Monte Sinai Hospital, Department of Vascular Surgery - Juiz de Fora - Minas Gerais - Brazil.

Financial support: none to declare.

Conflicts of interest: The authors declare no conflict of interest relevant to this manuscript.

Correspondence author: Roberto Heleno Lopes.

E-mail: roberto.oncocirurgia@gmail.com

Received on: May 26, 2019 | **Accepted on:** March 6, 2020 | **Published on:** August 6, 2020

DOI: <https://doi.org/10.5935/2526-8732.20200022>

INTRODUCTION

The inferior vena cava sarcoma (IVC) represents 2% of all leiomyosarcomas. It is a tumor of mesenchymal origin of poor prognosis, because approximately 50% of patients submitted to curative surgical resection will present recurrence of the disease. Leiomyosarcoma represents 60% of IVC primary malignancy cases of the inferior vena cava, and until the year 2010 there were less than 300 cases reported in medical literature on this pathology. The diagnosis is more common in sexagenarian women and the segment of the inferior vena cava most affected is located between the hepatic veins and the renal veins.^[1,2]

Surgical R0 resection in monoblock is the only form of curative treatment. The objectives of surgery are complete resection of malignant neoplasia, prevention of locoregional recurrence and venous return preservation. Due to the proximity to abdominal and retroperitoneal structures, enlarged resections may be necessary to obtain free margins. Surgical reconstruction of the vena cava is a controversial subject in the medical literature. Adjuvant treatment with radiotherapy is not related to increased survival in patients with leiomyosarcoma of the inferior vena cava; however, radiotherapy may assist in local disease control.^[2,3]

We report the case of a 73-year-old female patient with IVC leiomyosarcoma who underwent surgical R0 resection by videolaparoscopy. Reconstruction of the vena cava was not performed due to her low blood flow in the preoperative period and to the good development of collateral vascular systems. No neoadjuvant or adjuvant treatment has been performed.

CASE REPORT

R.M.B, 73-years-old, female, presenting abdominal discomfort, started in August 2015, with chronic and progressive evolution without irradiation and without other associated symptoms. The patient underwent these propaedeutic exams in March of 2016. Magnetic resonance image (MRI) upper abdomen floor showing expansive lesion with lush and heterogeneous enhancement after intravenous contrast located up retroperitoneal previously shifting the head of the pancreas and caudal duodenal arc, and keeping in touch with the right wall of the aorta, without definite signs of invasion of these structures and without a cleavage plane with the inferior vena cava, and may represent its primary lesion (Figure 1). Biopsy performed during echoendoscopy revealed histological and immunohistochemical findings compatible with leiomyosarcoma. Tests performed for staging did not demonstrate signs of distant metastasis.

Patient submitted to videolaparoscopic surgery in April 2016 for leiomyosarcoma treatment of the inferior vena cava located below renal veins and above the iliac vein bifurcation (segment I). Six trocars were arranged as follows: umbilical of 10mm, in the right

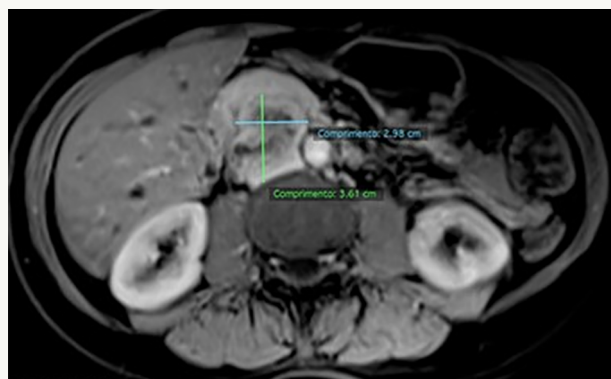


Figure 1. Para-aortic retroperitoneal lesion in the inferior vena cava topography with heterogeneous impregnation by contrast and restricted diffusibility.

flank of 12mm, in the left iliac fossa of 12mm, in the left flank of 5mm, in the right iliac fossa of 5mm and in epigastric region 5mm port. Dissection (Figure 2) and R0 resection of neoplasia and ligation of inferior vena cava with vascular (beige) Endogia® were performed. As in the preoperative examinations, the flow in the inferior vena cava was very low; it was chosen not to use graft or vascular prosthesis, due to the presence of well-developed collateral vascularization. Removal of the surgical piece (Figure 3) in a monoblock was through umbilical portal, Endogia® coated to protect the abdominal wall.

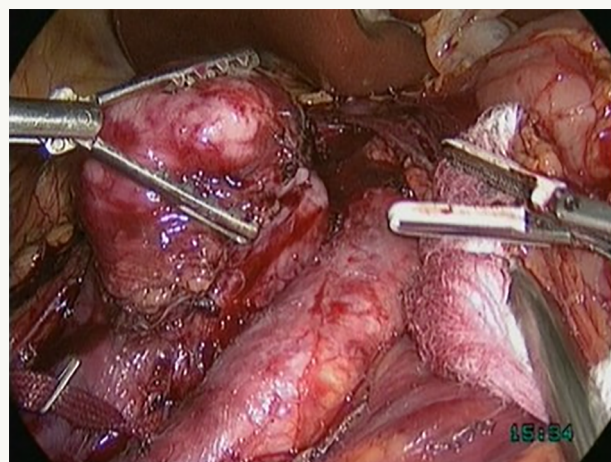


Figure 2. Dissection: distal and posterior repair of the inferior vena cava.

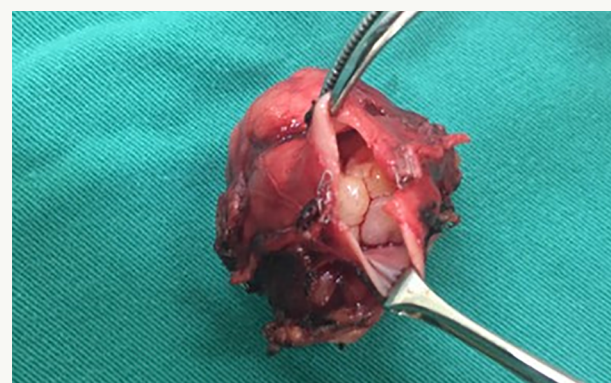

Figure 3. Intraluminal tumour and negative margin.

The surgery time was approximately 2h40min, and there was no intraoperative complication. An oral diet was introduced on the first postoperative day and the patient was discharged on the third postoperative day. Prophylactic heparinization was performed with enoxiparin 1mg/kg once daily for 30 days postoperatively.

Histological and immunohistochemical profile positive for desmin and smooth muscle actin. The diagnosis consistent with grade 1 leiomyosarcoma of 4 centimeters arising from the IVC with endophytic extension. Macro and microscopic negative margins.

After 30 months of follow up, the patient is asymptomatic, with no lower extremity lymphedema or thrombosis and no locoregional disease. She presented liver and lung metastasis, and is currently receiving combined chemotherapy with doxorubicin and olaratumab.

DISCUSSION

Primary leiomyosarcoma of inferior vena cava is a rare neoplasm and of poor prognosis, which develops from the smooth muscle constituents of the media layer of the blood vessel. It is the most common tumor of the venous system where the inferior vena cava and the most affected vessel. IVC leiomyosarcoma presents classification defined by its location: segment I (lower), below the renal vessels (IVC infrarenal); Segment II (middle): between the origin of renal vessels and the hepatic vein; Segment III (superior): between the origin of the hepatic veins to the right atrium (IVC suprahepatic). The majority of tumors are located in the middle segment (50.8%) and lower segment (44.2%). In our study, the patient presented IVC leiomyosarcoma in segment I.^[2,3,4,5,6,7,8]

In patients with metastasis and in those cases where it will not be possible to perform R0 resection, it must be performed neoadjuvant treatment and evaluate the possibility of R0 resection later. For patients submitted to surgical resection the next step is to analyze the margins of the surgical part. In case of free margins, the patient will be monitored and in case of positive margins, should be performed adjuvant treatment.^[3,7,8]

Chemotherapy and radiotherapy are not associated with increased patient survival; however, radiotherapy seems to help in local disease control. Reconstruction of the vena cava after resection of the tumor is a very controversial subject since some authors believe that this procedure would increase intraoperative time by increasing the morbidity of the procedure. In addition they believe that the patient is able to tolerate well the ligation of the inferior vena cava.^[3,4,6,7,8] Other authors argue in favor of the vena cava reconstruction for all patients, since the ligation of the vena cava will compromise venous return and cause lower extremity edema in patients. Reconstruction of the IVC can be done by autologous grafts, prostheses and vascular derivations.^[4,5,7,8]

After a careful literary survey on this subject (BIREME, Portal CAPES, PubMed and RIMA), we did not find studies that report videolaparoscopy as an access way in surgical resection of this type of tumor. All reports mention the laparotomy.

Just only one paper report a laparoscopic excision of an exophytic tumour without any intraluminal extension and no compromising IVC lumen.^[9] About these case we agree with others authors, partial resection of the IVC may lead to increased risk of tumor recurrence and an inadequate resection margin. It has been suggested that patients with leiomyosarcoma of the IVC should undergo complete resection of the portion of the IVC where the tumor is present.^[10]

In our report, the patient underwent total laparoscopic monoblock resection of the inferior vena cava and leiomyosarcoma with free margins, and the surgical time was similar to that of the laparotomy procedure described by other authors. The patient was given oral diet on the first postoperative day and hospital discharge on the third postoperative day, that is, there was a significant reduction in the length of hospital stay, contributing to a reduction in morbidity.

ACKNOWLEDGEMENTS

We thank Dr. Rodrigo Almeida, an oncologist for the initial diagnosis of the patient of this case report and conducting chemotherapy.

AUTHOR'S CONTRIBUTION

Roberto Heleno Lopes: Collection and assembly of data, Conception and design, Data analysis and interpretation, Final approval of manuscript, Manuscript writing, Provision of study materials or patient.

Antônio Carlos Rodrigues do Nascimento: Collection and assembly of data, Manuscript writing.

Alexandre Ferreira Oliveira: Collection and assembly of data, Conception and design, Data analysis and interpretation, Final approval of manuscript, Manuscript writing, Provision of study materials or patient.

Frederico Augustus Martins de Resende: Collection and assembly of data, Conception and design, Data analysis and interpretation, Final approval of manuscript, Manuscript writing, Provision of study materials or patient.

João Baptista de Paula Fraga: Collection and assembly of data, Conception and design, Data analysis and interpretation, Final approval of manuscript, Manuscript writing, Provision of study materials or patient.

Isolino Geraldo Almeida: Collection and assembly of data, Conception and design, Data analysis and interpretation, Final approval of manuscript, Manuscript writing, Provision of study materials or patient.

REFERENCES

1. Cananzi FCM, Mussi C, Bordoni MG, Marrari A, Sanctis R, Colombo P, et al. Role of surgery in the multimodal treatment of primary and recurrent leiomyosarcoma of the inferior vena cava. *J Surg Oncol*. 2016;114(1):44-9.
2. Sulpice L, Rayar M, Levi Sandri GB, Wailly P, Henno S, Turner K, et al. Leiomyosarcoma of the inferior vena cava. *J Visc Surg*. 2016 Jun;153(3):161-5.
3. Alkhalili E, Greenbaum A, Langsfeld M, Marek J, Rana MA, Glew R, et al. Leiomyosarcoma of the inferior vena cava: a case series and review of the literature. *Ann Vasc Surg*. 2016 May;33:245-51.
4. Wachtel H, Jackson BM, Bartlett EK, Karakoussis GC, Roses RE, Bavaria JE, et al. Resection of primary leiomyosarcoma of the inferior vena cava (IVC) with reconstruction: a case series and review of the literature. *J Surg Oncol*. 2015 Mar;111(3):328-33.
5. Illuminati G, Pizzardi G, Calio F, Pacilè MA, Masci F, Vietri F. Outcome of inferior vena cava and noncaval venous leiomyosarcomas. *Surgery*. 2016 Feb;159(2):613-20.
6. Jiang H, Wang YX, Li B, Jiang YY, Miao CL, Liao DX, et al. Surgical management of leiomyosarcoma of the inferior vena cava. *Vascular*. 2015 Jun;23(3):329-32.
7. Ghose J, Bhamre R, Mehta N, Desouza A, Patkar S, Dhadeshwar J, et al. Resection of the inferior vena cava for retroperitoneal sarcoma: six cases and a review of literature. *Indian J Surg Oncol*. 2018 Dec;9(4):538-46.
8. Teixeira Junior FJR, Couto Netto SD, Perina ALF, Torricelli FCM, Teixeira LR, Zerati AE, et al. Leiomyosarcoma of the inferior vena cava: survival rate following radical resection. *Oncol Lett*. 2017 Oct;14(4):3909-16.
9. Suryawanshi PR, Agrawal MM. Laparoscopic excision of leiomyosarcoma of inferior vena cava. *J Minim Access Surg*. 2017 Oct/Dec;13(4):303-5.
10. Yagnik VD. Primary leiomyosarcoma of the inferior vena cava. *J Minim Access Surg*. 2018 Jul/Sep;14(3):264.