






# Rheumatic Immune-Related Adverse Events in Patients with Metastatic Melanoma: Insights for Treatment from a Single Cancer Center

Surian Clarisse C. R. Ribeiro<sup>1</sup> Guilherme G. M. Balbi<sup>1</sup> Bruna G. Bunjes<sup>1</sup> Milton Jose B. Silva<sup>2</sup>  
Danieli C. O. de Andrade<sup>3</sup>

<sup>1</sup> Department of Rheumatology, A. C. Camargo Cancer Center, São Paulo, SP, Brazil

<sup>2</sup> Department of Oncology, A. C. Camargo Cancer Center, São Paulo, SP, Brazil

<sup>3</sup> Department of Rheumatology, Faculdade de Medicina, Universidade de São Paulo, São Paulo, SP, Brazil

**Address for correspondence** Surian Clarisse C R Ribeiro, Departamento de Reumatologia, A.C.Camargo Cancer Center, Rua Professor Antônio Prudente 211, Liberdade, São Paulo, SP, 15099-00, Brazil (e-mail: surian.ribeiro@accamargo.org.br).

Braz J Oncol 2026;22:s00451814174.

## Abstract

**Introduction** Clinical trials that led to the Food and Drug Administration (FDA) approval of systemic cancer therapies have generally excluded patients with autoimmune disease (AID) due to concerns about increased immune-related adverse events (irAEs), disease flares, and potential reductions in the efficacy of immunotherapies.

**Objective** To evaluate the optimal disease-modifying antirheumatic drug (DMARD) for patients with metastatic melanoma and immune-mediated rheumatic disease based on a narrative literature review and a case series from A.C.Camargo Cancer Center.

**Materials and Methods** This retrospective study included 10 adults with disseminated melanoma and immune-mediated diseases who were treated at the Rheumatology Outpatient Clinic at A.C.Camargo Cancer Center in Brazil between January 2020 and September 2024. A narrative literature review was conducted utilizing the Scopus and PubMed databases.

**Results** In this case series, 6 of the total 10 patients were treated with methotrexate (MTX), while those needing enhanced immunosuppression received tocilizumab due to its dual antitumor and anti-inflammatory properties. Furthermore, combining it with BRAF/MEK inhibitors effectively controlled inflammatory symptoms in the joints and skin. Clinical trials indicated that MTX and anti-IL-6 therapies are safe and effective in preventing and treating irAEs induced by immune checkpoint inhibitors (ICIs) and BRAF/MEK inhibitors. Previous case series suggest hydroxychloroquine and anti-IL-17 therapies may also be viable options. However, abatacept, sulfasalazine, and leflunomide should be avoided in patients receiving ICIs.

**Conclusion** When selecting an appropriate DMARD, the potential synergistic or detrimental effects on tumor behavior, the patient's risk for adverse events, melanoma stage, and ongoing cancer treatment should all be considered. Individual cytokine profiles and specific immune cell types may direct future research for managing irAE. Additionally, the degree of immunosuppression experienced by a patient may significantly impact their prognosis and warrants further investigation.

## Keywords

- ▶ adverse drug events
- ▶ immune checkpoint inhibitors
- ▶ molecular targeted therapy
- ▶ immunosuppressants
- ▶ musculoskeletal system

received  
June 4, 2025  
accepted after revision  
October 10, 2025

DOI <https://doi.org/10.1055/s-0045-1814174>.  
ISSN 2526-8732.

© 2026. The Author(s).

This is an open access article published by Thieme under the terms of the Creative Commons Attribution 4.0 International License, permitting copying and reproduction so long as the original work is given appropriate credit (<https://creativecommons.org/licenses/by/4.0/>)  
Thieme Revinter Publicações Ltda., Rua Rego Freitas, 175, loja 1, República, São Paulo, SP, CEP 01220-010, Brazil

## Introduction

Melanoma incidence has been rising in fair-skinned populations over the past several decades. However, since 2011, melanoma-related mortality has declined by approximately 30%, primarily due to the Food and Drug Administration's (FDA) approval of targeted therapies, including immune checkpoint inhibitors (ICIs) and small-molecule kinase inhibitors.<sup>1</sup>

These ICIs are indicated for various cancers, including melanoma,<sup>2</sup> enhancing antitumor immunity by disrupting coinhibitory T-cell signaling but also increase the risk of immune-related adverse events (irAEs). While most are mild and self-limiting, they occur in 40 to 70% of patients, depending on whether ICIs are used as monotherapy or in combination regimens.<sup>2,3</sup> Musculoskeletal irAEs, such as arthralgia, arthritis, myalgia, dry eyes, vasculitis, sarcoidosis, and back pain, are likely underreported in clinical trials, with estimated frequencies ranging from 1 to 5%.<sup>4,5</sup>

Retrospective studies have reported that 10 to 25% of patients with metastatic melanoma have preexisting autoimmune diseases (AIDs).<sup>6,7</sup> However, these patients were primarily excluded from pivotal clinical trials that led to FDA approval of systemic cancer therapies due to concerns about increased irAE susceptibility, potential disease flares, and the possibility of reduced ICI efficacy associated with concurrent immunosuppressive therapy.<sup>8</sup>

Prospective studies have documented higher irAE frequencies in patients with autoimmune conditions, such as psoriasis (Pso), rheumatoid arthritis (RA), polymyalgia rheumatica (PMR), chronic cutaneous lupus, and others.<sup>9</sup> Nevertheless, some retrospective studies suggest the risk of severe irAEs in these patients is comparable to that of the general population, at approximately 8%.<sup>7</sup> Additionally, AID flares can be more common in patients with rheumatic conditions receiving combination ICI therapy.<sup>4,10</sup>

The BRAF/MEK inhibitors, another class of targeted therapies, are used to treat melanoma with specific kinase mutations.<sup>11</sup> Arthralgia is the most frequent adverse event associated with these agents, occurring more frequently with BRAF monotherapy than with combination therapy due to the paradoxical activation of the mitogen-activated protein kinase (MAPK) pathway in synovial tissue.<sup>12</sup> Other possible side effects include myalgia, arthritis, and vasculitis. Although rare, serious conditions such as necrotizing and inflammatory myositis may arise, potentially requiring treatment with corticosteroids or immunosuppressants, as well as therapy discontinuation.<sup>13,14</sup>

This study aims to evaluate the best therapeutic approaches for patients with metastatic melanoma and immune-mediated diseases based on a narrative literature review and a case series of patients treated at the A.C. Camargo Cancer Center's outpatient clinic.

## Materials and Methods

This retrospective study included 10 adults with disseminated melanoma and AIDs who attended the Rheumatology

Outpatient Clinic at the A.C. Camargo Cancer Center in Brazil, between January 2020 and September 2024.

A narrative literature review was conducted using Scopus and PubMed, incorporating the following Medical Subject Headings (MeSH) keywords: "melanoma", "immune checkpoint inhibitors", "targeted therapy", "pre-existing autoimmune disorder", "rheumatic disorder", "immune-mediated adverse event", "disease-modifying antirheumatic drug (DMARD)", "anti-PD-1/PD-L1", and "anti-CTLA-4".

The study was approved by the institution's Ethics Committee, and all patients provided written informed consent.

## Results

There were six patients with preexisting AID, three with RA, one with systemic lupus erythematosus (SLE), one with Pso, and one with inflammatory recurrent serositis. Furthermore, four patients developed rheumatic irAEs after treatment. The patients were followed for 6 months after symptom onset.

### Patients with Preexisting Conditions

There were 6 patients with preexisting AID and stage III to IV melanoma required DMARD for either disease flare or de novo irAEs (n = 4), as shown in ► **Table 1**.

Patient 1 (RA in remission) was not on immunosuppressants when cancer treatment began. However, she experienced RA reactivation after the first nivolumab (anti-programmed cell death protein 1 [PD1]) infusion. She discontinued ICI therapy and was treated with sulfasalazine (SSZ) and hydroxychloroquine (HCQ). Unfortunately, she developed SSZ hypersensitivity, leading to hepatotoxicity and myelotoxicity, which were managed with prednisone (1 mg/kg). She was later transitioned to tocilizumab (TCZ, an interleukin-6 [IL-6] inhibitor, 4 mg/kg every 4 weeks), which enabled her to resume nivolumab while maintaining RA control. Then, ICI was reintroduced, but the patient experienced cancer progression.

Patient 2 (SLE) experienced a mild flare with inflammatory arthralgia in the hands and wrists, which was resolved with low-dose prednisone (< 10 mg/day) and HCQ (5 mg/kg/day). Prednisone was tapered, and the patient remained in rheumatic and cancer remission with HCQ alone.

Patient 3 (Pso in remission) developed severe psoriatic arthritis (PsA) and Pso relapse after the seventh nivolumab dose. Initially managed with prednisone (10–20 mg/day) and one infusion of infliximab (IFX, anti-tumor necrosis factor alpha [TNF $\alpha$ ]), the patient later experienced tumor progression and was switched to methotrexate (MTX) plus secukinumab (SCK, anti-IL17A). This regimen controlled symptoms while allowing corticosteroid tapering.

Patients 4 and 5 (RA in remission) remained stable while receiving ICI therapy and achieved a complete response to cancer. Patient 4 (MTX 15 mg/week, TCZ 162 mg every 2 weeks, and immunotherapy) developed a herpetic tongue ulcer after the fourth dose of nivolumab/ipilimumab, treated with valacyclovir.

**Table 1** Clinical data of patients with AID and melanoma

Case	S, A	Preexisting autoimmune disease/Ab	Stage*	OST	OST duration	AE after OST/CTCAE grade	IS	Response to IS	Response to OST	OST status
1	F, 70	RA/FR+	IV	nivolumab	0,5	RA flare grade 4	PRED SSZ HCQ TCZ	Complete	Progression	Restarted
2	F, 34	SLE/Ro + LAC+	IV	nivolumab	7	SLE Flare grade 2	PRED HCQ	Complete	Complete	Completed
3	M, 59	Psoriasis/No	III	nivolumab	7	APs and Pso flare grade 4	PRED TNFi MTX COS	Complete	Progression	Restarted
4	F, 75	RA/FR+	IV	ipilimumab nivolumab	7	Herpes on the tongue	MTX TCZ	Complete	Complete	Ongoing
5	F, 69	RA/FR+	III	nivolumab	6	–	MTX	Complete	Complete	Ongoing
6	M, 49	Inflammatory recurrent serositis/No	III	dabrafetinib and trametinib	3	AR-like grade 3	PRED MTX	Complete	Stable	Ongoing

**Abbreviations:** A, age, in years; Ab, autoantibody; AE, adverse event; AID, autoimmune disease; APs, activator proteins; COS, cosentyx; CTCAE, Common Terminology Criteria for Adverse Events; F, female; FR, rheumatoid factor; HCQ, hydroxychloroquine; IS, rheumatic immunosuppressant; LAC+, lupus anticoagulant positive; M, male; MTX, methotrexate; OST, oncologic systemic therapy; PRED, prednisone; Pso, psoriasis; RA, rheumatoid arthritis; Ro+, anti-Ro/SSA positive; S, sex; SLE, systemic lupus erythematosus; SSZ, sulfasalazine; TCZ, tocilizumab; TNFi, TNF inhibitor. **Notes:** \*Stage of melanoma. The AE was measured after OST onset. The OST duration was measured in months, OST status was measured after 6 months of IS onset, and response to OST was measured as oncological outcome after 6 months. Response to IS was measured as rheumatic disease response after 6 months of IS.

Patient 5 (history of scleritis and mild arthritis) was on MTX 20 mg/week during nivolumab therapy and did not experience irAEs.

Patient 6 (inflammatory recurrent serositis) developed hand and wrist arthritis after starting dabrafenib (BRAF inhibitor) and trametinib (MEK1/2 inhibitor). Treatment included prednisone 20 mg/day (discontinued in 1–2 months), colchicine, and MTX 15 mg/week to manage symptoms. Targeted therapy was continued, and cancer stabilized.

In retrospective studies, the frequency of AID flares during ICI ranges from 20 to 50%. These flares often resemble previous disease activity, as observed in patients 1, 2, and 3 (►Table 1).<sup>15,16</sup>

Reduced anti-tumor efficacy of systemic therapy due to immunosuppressants treating AID flares is a concern. Brown et al.<sup>15</sup> indicated a lower overall survival (OS) rate for melanoma patients using ICI while having baseline immunosuppression due to AID (11 months, 95%CI: 3.42–18.58) compared with those without immunosuppression (31 months, 95%CI: 20.89–41.11).<sup>15</sup>

Some retrospective studies showed an association between the use of glucocorticoids at the beginning of ICI treatment for metastatic melanoma and reduced OS. However, these studies did not report the reasons for using glucocorticoids, making any conclusions speculative.<sup>17,18</sup> Ricciuti et al. indicated an association between glucocorticoid therapy for oncologic symptoms and poor prognosis of ICI patients. Additionally, those who were treated for AID

with prednisone > 10mg daily did not show significant differences in progression-free survival (PFS) and OS (4.6–3.4 months; hazard ratio [HR]: 0.77;  $p = 0.24$ ) compared to those who received 0 to < 10 mg of prednisone (10.7–11.2 months; HR: 0.93;  $p = 0.77$ ).<sup>19</sup>

Other retrospective studies revealed comparable OS in metastatic melanoma and non-small-cell lung cancer patients, whether they had AID or not.<sup>20</sup> A retrospective observational study that included 146 patients with melanoma, non-small-cell lung cancer, and renal cell carcinoma did not show an association between glucocorticoid use for irAE in the first 30 days from the beginning of ICI and shorter PFS ( $p = 0.077$ ). Moreover, this study demonstrated a possible better OS associated with glucocorticoid use 30 days after ICI started, probably related to immortality bias.<sup>21</sup> The use of physiologic doses of prednisone (< 10mg/day) for the treatment of adrenal insufficiency secondary to ipilimumab therapy in retrospective studies, including patients with non-small-cell lung cancer, suggested that low doses of prednisone may not affect the efficacy of ICI.<sup>19,22</sup>

The HCQ is a DMARD frequently used as a first-line treatment for inflammatory arthropathy secondary to AID or ICI. It has demonstrated safety and effectiveness in managing mild symptoms, as seen in patients 1 and 2, as well as in several case series.<sup>23–25</sup>

Sharma et al. revealed that HCQ enhanced the antitumor efficacy of anti-PD-1 therapy in mouse models by inhibiting palmitoyl-protein thioesterase 1 (PPT1).<sup>26</sup> On the other

hand, Wabitsch et al.<sup>27</sup> suggested that HCQ impairs the response to anti-PD-1 treatment by reducing T-cell activation and tumor infiltration in *in vivo* tumor models. Prospective cohorts are needed to clarify the long-term impact of this drug use on patient response to ICI.

A phase-I/II trial evaluating patients with advanced BRAFV600 mutant melanoma indicated that HCQ combined with dabrafenib and trametinib was safe and effective, with an antitumor effect. It may improve response rates to MAPK-targeted therapy due to its role as a lysosomal inhibitor that blocks autophagy, making it a potentially safe option for treating arthralgia induced by BRAF/MEK inhibitors.<sup>28</sup>

Retrospective studies involving patients with RA and PMR showed the safety and effectiveness of MTX therapy for those receiving ICIs.<sup>29,30</sup> Furthermore, a preclinical study demonstrated that MTX promotes the formation of central memory T-cells and reduces PD1 expression in a melanoma mouse model, without impairing the antitumor effect of ICI.<sup>31</sup> For patients receiving BRAF/MEK inhibitors, MTX may also be a safe treatment for arthritis, myositis, and vasculitis. Based on case reports, this drug is especially relevant, as it could reduce the need for corticosteroids.<sup>13,32</sup>

Some retrospective studies indicated that SSZ monotherapy leads to poorer control of arthritis induced by ICI and a higher incidence of hypersensitivity reactions compared to its use in treating RA patients.<sup>33,34</sup> A preclinical study showed that anti-PD-1/PD-L1 contributes to drug-responsive T-cell effectors in hypersensitivity reactions in SSZ users.<sup>35</sup>

The use of TCZ is an effective treatment for AID flares and irAEs, as evidenced by patients 1 and 4. Observational retrospective studies demonstrated the effectiveness and safety of IL-6 inhibitors in treating rheumatic irAEs and AID flares, such as RA, psoriatic arthritis (APs), and PMR.<sup>36,37</sup> The COLAR open-label clinical study also showed positive outcomes for patients with arthritis and colitis related to ICI treatment with TCZ. This study found that all 18 patients discontinued glucocorticoid therapy, 79% showed symptom improvement, and 26% (n=5) experienced reversible grade-3 and -4 adverse events related to TCZ.<sup>38</sup>

Preclinical studies found that IL-6 inhibitors enhance the tumor-infiltrating T-cell response induced by anti-CTLA-4 therapy in murine models, demonstrating an antitumoral effect.<sup>39</sup> A phase-II clinical trial<sup>40</sup> combining intravenous TCZ with nivolumab and ipilimumab showed a low incidence of grade 3 and 4 irAEs (22% of patients with metastatic melanoma) and a favorable overall response rate (NCT03999749).<sup>40</sup> Another ongoing randomized phase-II trial suggested that subcutaneous TCZ in combination with nivolumab and ipilimumab may reduce the occurrence of grade-3 and -4 irAEs without compromising prognosis (NCT04940299).

Furthermore, in a retrospective study by Petit et al.,<sup>41</sup> 11 patients who received secondary prophylaxis with TCZ were compared to 5 patients who did not, during ICI rechallenge following ICI-induced arthritis. The results revealed that patients on TCZ prophylaxis had a lower rate of arthritis

relapses of 17% during ICI rechallenge, compared to 40% in those who did not receive it.<sup>41</sup>

Tumor necrosis factor inhibitors (TNFi) are another option for treating AID and rheumatic irAEs and may help prevent the latter. Retrospective studies showed that TNFi leads to quicker resolution of colitis and inflammatory arthritis related to ICI treatment, without compromising OS compared to corticosteroid monotherapy.<sup>42,43</sup> Additionally, an ongoing phase I/II clinical trial involving 14 patients with advanced melanoma using ipilimumab and nivolumab, combined with IFX or certolizumab (CTZ) as TNFis, has reported the safety of triple combinations. Grade 3 and 4 irAE occurred in 3 of 6 IFX users and 6 of 8 CTZ users. All CTZ patients showed complete or partial responses to ICI treatment.<sup>44</sup>

However, a cohort of 1,250 melanoma patients treated with ICI revealed lower OS in those using TNFi compared to those receiving glucocorticoids alone for irAE treatment, independent of sex, performance status, comorbidities, disease stage, metastasis, and ICI subtype.<sup>45</sup> A retrospective observational study by Bass et al. demonstrated a shorter time to cancer progression and arthritis control for TNFi compared to MTX. The subanalysis in patients with melanoma showed similar results for arthritis control (HR: 13.44; 95%CI: 2.23–81.09;  $p=0.005$ ) and cancer progression (HR: 6.19; 95%CI: 0.64–59.55;  $p=0.115$ ).<sup>46</sup>

The use of IL-17 inhibitors effectively controlled preexisting APs, Pso, and arthritis induced by ICI treatment while maintaining the anti-tumor effect of immunotherapy in case reports.<sup>47,48</sup> Additionally, Dimitriou et al. conducted a proof-of-concept case study using SCK (anti-IL17A) to treat 2 patients with advanced melanoma and refractory and severe irAEs induced by ipilimumab and nivolumab. The patients presented with grade-2 myocarditis, grade-3 colitis, and grade-3 lichenoid skin rash, all of which were refractory to corticosteroids and TNFi. These conditions were resolved with SCK therapy.<sup>49</sup>

### Patients with Rheumatic irAEs and Metastatic Melanoma

In this case series, four patients diagnosed with stage II to III melanoma received DMARD as a treatment for *de novo* irAEs (► **Table 2**). Also, one patient presented with severe irAEs, including myocarditis and myositis induced by ICI, which led to the discontinuation of immunotherapy.

Patient 7 developed oligoarthritis affecting the bilateral knees and ankles, which did not respond to nonsteroidal anti-inflammatory drugs (NSAIDs) after the tenth dose of nivolumab. She required low-dose prednisone (maximum 20 mg/day) and was treated with HCQ and MTX to control symptoms. She achieved remission within 6 months and was able to maintain HCQ while discontinuing MTX. The patient achieved a complete response with ICI therapy.

Patient 8 had arthritis in the wrists and hands, negative rheumatoid factor, and antinuclear antibodies following the last nivolumab infusion. We introduced SSZ to control the arthritis after completing anti-PD1 therapy, with a good response. She also used acetaminophen and codeine to manage pain symptoms.

**Table 2** Clinical data of patients with rheumatic irAE and melanoma

Case	S, A	Preexisting AID/Ab	Stage*	OST	OST duration	AE after OST	IS	Response to IS	Response to OST	OST status
7	F, 46	No/No	III	nivolumab	10	Oligoarthritis grade 3	NSAID PRED MTX HCQ	Complete	Stable	Completed
8	F, 74	No/No	III	nivolumab	12	AR-like grade 2	SSZ	Complete	Complete	Completed
9	F, 63	No/No	II	nivolumab and ipilimumab	2	Myocarditis and myositis grade 3	PRED MMF	Complete	Stable	Suspended
10	F, 42	No/No	III	trametinib dabrafenib encorafenib binimetinibe	1	Nodosum erythema, myalgia grade 3	PRED MTX	Complete	Stable	Continued

**Abbreviations:** A, age, in years; Ab, autoantibody; AE, adverse event; AID, autoimmune disease; F, female; HCQ, hydroxychloroquine; irAEs, immune-related adverse events; IS, rheumatic immunosuppressant; M, male; MMF, mycophenolate mofetil; MTX, methotrexate; NSAID, non-steroidal anti-inflammatory drugs; OST, oncologic systemic therapy used; PRED, prednisone; S, sex; SSZ, sulfasalazine.

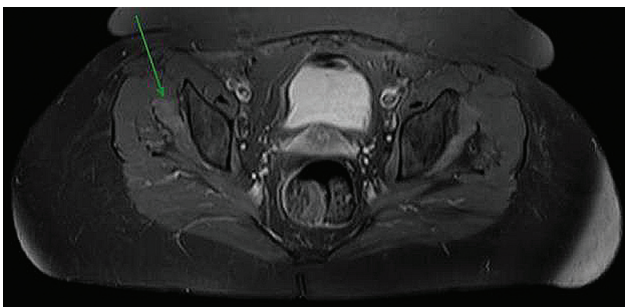
**Notes:** \*Stage of melanoma. The AE was measured after OST onset. The OST duration was measured in months, OST status was measured after 6 months of IS onset, and response to OST was measured as oncological outcome after 6 months. Response to IS was measured as rheumatic disease response after 6 months of IS.

Patient 9 developed myocarditis and myositis after the second nivolumab infusion, presenting with chest pain and CTCA grade 3 proximal limb weakness. Laboratory results indicated elevated creatine kinase and troponin levels. Cardiac and proximal muscle imaging showed inflammatory changes (► **Figures 1–2**). The ICI therapy was discontinued. She was treated with 1g of intravenous methylprednisolone for 3 days, followed by reduced doses of prednisone (maximum 1 mg/kg) and mycophenolate mofetil (MMF) at 3 g/day. She achieved remission 4 months after starting MMF.

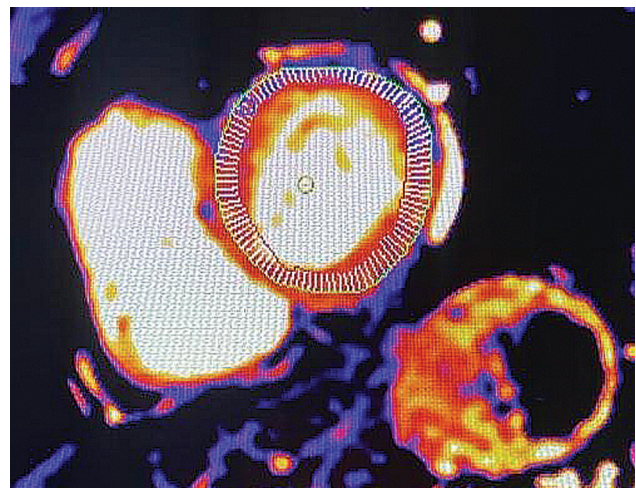
Patient 10 developed grade-4 ICI-induced hepatitis, leading to the interruption of ipilimumab combined with nivolumab therapy before starting BRAF/MEK inhibitor treatment. After beginning trametinib and dabrafenib, she developed painful erythematous cutaneous nodules on her extremities, along with myalgia. She initiated prednisone, improving symptoms, but her condition worsened when trying to reduce the corticosteroid dosage. The targeted

therapy was changed to encorafenib/binimetinib, but the patient continued to experience skin lesions that were refractory to corticoid-sparing treatment due to prior immunotherapy use. Then, MTX started with 10 mg/day of prednisone. After discontinuing steroids, the patient achieved resolution of erythema nodosum-like lesions using a weekly dose of 20 mg MTX combined with encorafenib/binimetinib, despite experiencing mild nausea and hair loss. She had a complete response to systemic cancer therapy.

Rheumatologic irAE occurred in around 16% of the patients with metastatic cutaneous melanoma who received immunotherapy, according to a retrospective study of 415 patients between 2014 and 2020.<sup>50</sup>



**Fig. 1** A T2-weighted (T2)/short-Tau inversion recovery (STIR) magnetic resonance imaging (MRI) scan of Patient 9's thigh muscles. A mild increase in T2/STIR signal (green arrow) was noted in the right gluteus minimus muscle after pulsotherapy with methylprednisolone, suggesting inflammatory myositis.



**Fig. 2** An MRI scan of Patient 9's heart muscles. Tissue analysis using T1-weighted MAPA sequences demonstrates elevated values (1,010 ms, 1.5T) after pulsotherapy with methylprednisolone, suggesting the presence of inflammatory myocarditis.

In some cases, high-dose corticosteroids are required, particularly for severe ICI-related myositis, a potentially life-threatening condition.<sup>51</sup> According to the literature, myositis may be associated with myocarditis in up to 40% of cases, and mortality rates are higher in those cases.<sup>52</sup> Patient 9 received intravenous methylprednisolone therapy and started MMF, achieving prednisone sparing and remission of ICI-induced myositis-myocarditis.

American and European guidelines recommend 1 to 2 mg/kg of intravenous methylprednisolone or a higher dose bolus (500–1,000 mg/day for 3 days) for ICI-related myositis and myocarditis in the presence of severe symptoms of weakness or cardiac compromise.<sup>53,54</sup> In cases refractory to methylprednisolone, intravenous immunoglobulin, abatacept (ABA, a CTLA-4 agonist), MMF, TCZ, and IFX are considered options for controlling myositis and myocarditis, according to some case series.<sup>55,56</sup> Salem et al. reported a 3% mortality rate among 30 patients with ICI-induced myocarditis-myositis screened for respiratory failure, treated with active ventilation and higher doses of ABA combined with ruxolitinib.<sup>57</sup>

The use of BRAF/MEK inhibitors rarely lead to severe irAEs requiring corticosteroid pulses, such as small vessel vasculitis, uveitis, and papillitis.<sup>32</sup> Recommendations for treating mild panniculitis include NSAIDs and topical steroids, while severe cases may require systemic corticosteroids and a reduction in or interruption of targeted therapy.<sup>13,58</sup> Retrospective studies described unexpected toxicities, including rashes, abdominal pain, nausea, vomiting, diarrhea, pneumonitis, hepatitis, kidney injury, and cytokine release syndrome in patients using BRAF/MEK inhibitors who had previously been treated with immunotherapy.<sup>59,60</sup>

Preclinical studies have shown that BRAF inhibitors enhance antigen presentation and boost T-cell recognition of tumor antigens. Meanwhile, MEK inhibitors promote an increase in effector CD8 + T-cells within the tumor microenvironment. As a result, patients treated with BRAF/MEK inhibitors following ICI may experience enhanced immune-cell function and antigen presentation, along with an extended half-life of monoclonal antibodies induced by immunotherapy.<sup>61</sup> In this context, Patient 10 presented uncommon refractory erythema nodosum-like lesions, so MTX was used to spare corticosteroids, allowing for the continuation of BRAF/MEK inhibitor therapy.

## Discussion

In the present case series, all patients with AID continued systemic cancer therapy after controlling irAEs or flares. Furthermore, seven of ten patients received a low dose of a DMARD (MTX in the majority) to maintain stable immune-mediated disease while minimizing corticosteroid use. In clinical practice, we avoid using glucocorticoids or doses exceeding 10 mg/day when an alternative therapy is available, particularly in older patients.

Although this study had a limited sample size and lasted 6 months, it reported two cases where the combination of MTX therapy with BRAF/MEK inhibitors effectively con-

trolled inflammatory symptoms in both joints and skin. Most case series described corticosteroid monotherapy, dose reduction, or suspension of small-molecule kinase inhibitors to manage irAE. Some reports of irAEs induced by BRAF/MEK inhibitors described the use of MTX to treat asymptomatic aortitis in preexisting RA, rituximab for granulomatosis with polyangiitis, and etanercept for toxic epidermal necrolysis.<sup>32,59,62</sup> This case series suggests that MTX may be an option for managing arthritis and panniculitis while allowing continued use of BRAF/MEK inhibitors.

Patients who required enhanced immunosuppression to control inflammatory activity were preferentially treated with TCZ due to its antitumor properties and effectiveness as a DMARD. Some studies suggested that IL-6 inhibitors may be an alternative DMARD for patients at high risk for irAEs, with intense activity of preexisting AID, or for patients requiring ICI rechallenge (NCT03999749, NCT04940299).<sup>40,42</sup>

On the other hand, prospective studies are needed to clarify the safety of TNFi in melanoma patients treated with ICI. The use of ABA should be avoided as a DMARD for ICI-induced arthritis, as it inhibits T-cell activation.<sup>63</sup> However, some case reports and a recent trial of ICI-induced myocarditis and myositis showed a good response to ABA therapy.<sup>55,57,64</sup>

When prescribing SSZ to anti-PD-1/PD-L1 users, caution is necessary due to the risk of hypersensitivity. The present case series highlights two patients with differing outcomes: one experienced severe adverse events induced by SSZ during ICI treatment, and another managed her arthritis successfully with SSZ after discontinuing ICI.

Furthermore, leflunomide (LFN) reduces T-cell clonal expansion and may impair the antitumoral effects of ICI.<sup>63</sup> Guidelines for managing toxicity induced by BRAF/MEK inhibitors recommend LFN for treating rheumatic symptoms.<sup>13</sup> However, a phase-I trial involving melanoma patients using this drug in combination with vemurafenib was terminated due to severe adverse events (NCT01611675).

The limited understanding of the pathophysiology of irAEs hinders the application of more effective therapeutic strategies. Targeting cytokines or their receptors is crucial for managing inflammatory symptoms, mitigating levels of immunosuppression, and enhancing oncological outcomes. Further studies are necessary to evaluate the effectiveness of agents targeting IL-6, IL-12, IL-17, and IL-23 in managing and preventing rheumatic, dermatological, and gastrointestinal irAEs.

Selecting a DMARD for metastatic melanoma patients requires consideration of its potential synergistic or detrimental effects on tumor behavior, patients' risk profile for irAE, the severity of rheumatic manifestations, ongoing cancer treatments, and any comorbidities. Individual cytokine profiles and specific immune cell types may direct future research for managing irAE. Additionally, the degree of immunosuppression experienced by a patient undergoing concurrent rheumatic and cancer therapy may significantly impact their prognosis and warrants further investigation.

### Authors' Contributions

SR and MS: conceptualization, data curation, and writing; GB and BB: data curation; and DA: conceptualization and writing.

### Funding

The authors declare that they did not receive funding from agencies in the public, private or non-profit sectors to conduct the present study.

### Conflict of Interests

The authors have no conflict of interests to declare.

### References

- Saginala K, Barsouk A, Aluru JS, Rawla P, Barsouk A. Epidemiology of Melanoma. *Med Sci (Basel)* 2021;9(04):63. Doi: 10.3390/medsci9040063
- Evangelista GFdB, Figueiredo AB, Silva MJdBe, Gollob KJ. Balancing the good and the bad: controlling immune-related adverse events versus anti-tumor responses in cancer patients treated with immune checkpoint inhibitors. *Immunother Adv* 2022;2(01):ltac008. Doi: 10.1093/immadv/ltac008
- Xu C, Chen YP, Du XJ, et al. Comparative safety of immune checkpoint inhibitors in cancer: systematic review and network meta-analysis. *BMJ* 2018;363:k4226. Doi: 10.1136/bmj.k4226
- Pantuck M, McDermott D, Drakaki A. To treat or not to treat: Patient exclusion in immune oncology clinical trials due to preexisting autoimmune disease. *Cancer* 2019;125(20):3506–3513. Doi: 10.1002/cncr.32326
- Leipe J, Mariette X. Management of rheumatic complications of ICI therapy: a rheumatology viewpoint. *Rheumatology (Oxford)* 2019;58(Suppl 7):vii49–vii58. Doi: 10.1093/rheumatology/kez360
- Khan SA, Pruitt SL, Xuan L, Gerber DE. Prevalence of Autoimmune Disease Among Patients With Lung Cancer: Implications for Immunotherapy Treatment Options. *JAMA Oncol* 2016;2(11):1507–1508. Doi: 10.1001/jamaoncol.2016.2238
- Cortellini A, Buti S, Santini D, et al. Clinical Outcomes of Patients with Advanced Cancer and Pre-Existing Autoimmune Diseases Treated with Anti-Programmed Death-1 Immunotherapy: A Real-World Transverse Study. *Oncologist* 2019;24(06):e327–e337. Doi: 10.1634/theoncologist.2018-0618
- Cappelli LC, Gutierrez AK, Bingham CO III, Shah AA. Rheumatic and Musculoskeletal Immune-Related Adverse Events Due to Immune Checkpoint Inhibitors: A Systematic Review of the Literature. *Arthritis Care Res (Hoboken)* 2017;69(11):1751–1763. Doi: 10.1002/acr.23177
- Danlos FX, Voisin AL, Dyeve V, et al. Safety and efficacy of anti-programmed death 1 antibodies in patients with cancer and pre-existing autoimmune or inflammatory disease. *Eur J Cancer* 2018;91:21–29. Doi: 10.1016/j.ejca.2017.12.008
- Haanen J, Ernstoff MS, Wang Y, et al. Autoimmune diseases and immune-checkpoint inhibitors for cancer therapy: review of the literature and personalized risk-based prevention strategy. *Ann Oncol* 2020;31(06):724–744. Doi: 10.1016/j.annonc.2020.03.285
- Min HY, Lee HY. Molecular targeted therapy for anticancer treatment. *Exp Mol Med* 2022;54(10):1670–1694. Doi: 10.1038/s12276-022-00864-3
- Salzmann M, Benesova K, Buder-Bakhaya K, et al. Arthralgia Induced by BRAF Inhibitor Therapy in Melanoma Patients. *Cancers (Basel)* 2020;12(10):3004. Doi: 10.3390/cancers12103004
- Heinzerling L, Eigentler TK, Fluck M, et al. Tolerability of BRAF/MEK inhibitor combinations: adverse event evaluation and management. *ESMO Open* 2019;4(03):e000491. Doi: 10.1136/esmoopen-2019-000491
- Penel N, Blay JY, Adenis A. Imatinib as a possible cause of severe rhabdomyolysis. *N Engl J Med* 2008;358(25):2746–2747. Doi: 10.1056/NEJMc0708896
- Brown LJ, Weppler A, Bhave P, et al. Combination anti-PD1 and ipilimumab therapy in patients with advanced melanoma and pre-existing autoimmune disorders. *J Immunother Cancer* 2021;9(05):e002121. Doi: 10.1136/jitc-2020-002121
- Abdel-Wahab N, Shah M, Lopez-Olivo MA, Suarez-Almazor ME. Use of Immune Checkpoint Inhibitors in the Treatment of Patients With Cancer and Preexisting Autoimmune Disease: A Systematic Review. *Ann Intern Med* 2018;168(02):121–130. Doi: 10.7326/M17-2073
- Pan EY, Merl MY, Lin K. The impact of corticosteroid use during anti-PD1 treatment. *J Oncol Pharm Pract* 2020;26(04):814–822. Doi: 10.1177/1078155219872786
- Chasset F, Pages C, Biard L, et al. Single-center study under a French Temporary Authorization for Use (TAU) protocol for ipilimumab in metastatic melanoma: negative impact of baseline corticosteroids. *Eur J Dermatol* 2015;25(01):36–44. Doi: 10.1684/ejd.2014.2471
- Ricciuti B, Dahlberg SE, Adeni A, Sholl LM, Nishino M, Awad MM. Immune Checkpoint Inhibitor Outcomes for Patients With Non-Small-Cell Lung Cancer Receiving Baseline Corticosteroids for Palliative Versus Nonpalliative Indications. *J Clin Oncol* 2019;37(22):1927–1934. Doi: 10.1200/JCO.19.00189
- Yeung C, Kartolo A, Holstead R, et al. Safety and Clinical Outcomes of Immune Checkpoint Inhibitors in Patients With Cancer and Preexisting Autoimmune Diseases. *J Immunother* 2021;44(09):362–370. Doi: 10.1097/CJI.0000000000000377
- Paderi A, Gambale E, Botteri C, et al. Association of Systemic Steroid Treatment and Outcome in Patients Treated with Immune Checkpoint Inhibitors: A Real-World Analysis. *Molecules* 2021;26(19):5789. Doi: 10.3390/molecules26195789
- Johnson DB, Sullivan RJ, Menzies AM. Immune checkpoint inhibitors in challenging populations. *Cancer* 2017;123(11):1904–1911. Doi: 10.1002/cncr.30642
- Roberts J, Smylie M, Walker J, et al. Hydroxychloroquine is a safe and effective steroid-sparing agent for immune checkpoint inhibitor-induced inflammatory arthritis. *Clin Rheumatol* 2019;38(05):1513–1519. Doi: 10.1007/s10067-019-04451-2
- Richter MD, Crowson C, Kottschade LA, Finnes HD, Markovic SN, Thanarajasingam U. Rheumatic Syndromes Associated With Immune Checkpoint Inhibitors: A Single-Center Cohort of Sixty-One Patients. *Arthritis Rheumatol* 2019;71(03):468–475. Doi: 10.1002/art.40745
- Zitouni NB, Arnault JP, Dadban A, Attencourt C, Lok CC, Chaby G. Subacute cutaneous lupus erythematosus induced by nivolumab: two case reports and a literature review. *Melanoma Res* 2019;29(02):212–215. Doi: 10.1097/CMR.0000000000000536
- Sharma G, Ojha R, Noguera-Ortega E, et al. PPT1 inhibition enhances the antitumor activity of anti-PD-1 antibody in melanoma. *JCI Insight* 2020;5(17):e133225. Doi: 10.1172/jci.insight.133225. Erratum in: *JCI Insight* 2022;7(20):e165688 10.1172/jci.insight.165688
- Wabitsch S, McVey JC, Ma C, et al. Hydroxychloroquine can impair tumor response to anti-PD1 in subcutaneous mouse models. *iScience* 2020;24(01):101990. Doi: 10.1016/j.isci.2020.101990
- Mehnert JM, Mitchell TC, Huang AC, et al. BMM (BRAF Autophagy and MEK Inhibition in Melanoma): A Phase I/II Trial of Dabrafenib, Trametinib, and Hydroxychloroquine in Advanced BRAFV600-mutant Melanoma. *Clin Cancer Res* 2022;28(06):1098–1106. Doi: 10.1158/1078-0432.CCR-21-3382
- McCarter KR, Arabelovic S, Wang X, et al. Immunomodulator use, risk factors and management of flares, and mortality for patients with pre-existing rheumatoid arthritis after immune checkpoint inhibitors for cancer. *Semin Arthritis Rheum* 2024;64:152335. Doi: 10.1016/j.semarthrit.2023.152335

- 30 Vermeulen OCB, Brouwer E, Slart RHJA, et al. Immune checkpoint inhibitor-mediated polymyalgia rheumatica versus primary polymyalgia rheumatica: comparison of disease characteristics and treatment requirement. *Rheumatology (Oxford)* 2024;64(02):771–779. Doi: 10.1093/rheumatology/keae099
- 31 Papadopoulos T, Santinon F, Hudson M, Del Rincon SV. Examining methotrexate's safety and efficacy in combination with immune checkpoint inhibitors to control immune related inflammatory arthritis in cancer. *J Immunol* 2023;210(Suppl 1):68.03. Doi: 10.4049/jimmunol.210.Suppl.68.03
- 32 Ichikawa K, Ohno S, Kubo S, Nakajima H. Large-vessel vasculitis possibly induced by BRAF and MEK inhibitors for BRAF V600E positive lung adenocarcinoma. *BMJ Case Rep* 2024;17(05):e255958. Doi: 10.1136/bcr-2023-255958
- 33 Challener G, Kohler MJ, Yokose C, Yin J, Choi H. POS0139 Safety and efficacy of sulfasalazine in treatment of immune checkpoint inhibitor-inflammatory arthritis. *Ann Rheum Dis* 2024;83(Suppl 1):419. Doi: 10.1136/annrheumdis-2024-eular.6118
- 34 Ford M, Sahbudin I, Filer A, Steven N, Fisher BA. High proportion of drug hypersensitivity reactions to sulfasalazine following its use in anti-PD-1-associated inflammatory arthritis. *Rheumatology (Oxford)* 2018;57(12):2244–2246. Doi: 10.1093/rheumatology/key234
- 35 Hammond S, Olsson-Brown A, Grice S, et al. Checkpoint Inhibition Reduces the Threshold for Drug-Specific T-Cell Priming and Increases the Incidence of Sulfasalazine Hypersensitivity. *Toxicol Sci* 2022;186(01):58–69. Doi: 10.1093/toxsci/kfab144
- 36 Dimitriou F, Hogan S, Menzies AM, Dummer R, Long GV. Interleukin-6 blockade for prophylaxis and management of immune-related adverse events in cancer immunotherapy. *Eur J Cancer* 2021;157:214–224. Doi: 10.1016/j.ejca.2021.08.031
- 37 Fa'ak F, Buni M, Falohun A, et al. Selective immune suppression using interleukin-6 receptor inhibitors for management of immune-related adverse events. *J Immunother Cancer* 2023;11(06):e006814. Doi: 10.1136/jitc-2023-006814 .Erratum in: *J Immunother Cancer* 2023;11(7):e006814corr1 10.1136/jitc-2023-006814corr1
- 38 Holmstroem RB, Nielsen OH, Jacobsen S, et al. COLAR: open-label clinical study of IL-6 blockade with tocilizumab for the treatment of immune checkpoint inhibitor-induced colitis and arthritis. *J Immunother Cancer* 2022;10(09):e005111. Doi: 10.1136/jitc-2022-005111
- 39 Hailemichael Y, Johnson DH, Abdel-Wahab N, et al. Interleukin-6 blockade abrogates immunotherapy toxicity and promotes tumor immunity. *Cancer Cell* 2022;40(05):509–523.e6. Doi: 10.1016/j.ccell.2022.04.004
- 40 Weber JS, Puranik A, Mitzutani T, et al. Interleukin-6 receptor blockade with tocilizumab to reduce immune-related toxicity with ipilimumab and nivolumab in metastatic melanoma. *J Clin Oncol* 2024;42( 16 suppl):9538. Doi: 10.1200/JCO.2024.42.16.-suppl.9538
- 41 Petit PF, Daoudlarian D, Latifyan S, et al. Tocilizumab provides dual benefits in treating immune checkpoint inhibitor-associated arthritis and preventing relapse during ICI rechallenge: the TAPIR study. *Ann Oncol* 2025;36(01):43–53. Doi: 10.1016/j.annonc.2024.08.2340
- 42 Johnson DH, Zobniw CM, Trinh VA, et al. Infliximab associated with faster symptom resolution compared with corticosteroids alone for the management of immune-related enterocolitis. *J Immunother Cancer* 2018;6(01):103. Doi: 10.1186/s40425-018-0412-0
- 43 Cappelli LC, Brahmer JR, Forde PM, et al. Clinical presentation of immune checkpoint inhibitor-induced inflammatory arthritis differs by immunotherapy regimen. *Semin Arthritis Rheum* 2018;48(03):553–557. Doi: 10.1016/j.semarthrit.2018.02.011
- 44 Montfort A, Filleron T, Virazels M, et al. Combining Nivolumab and Ipilimumab with Infliximab or Certolizumab in Patients with Advanced Melanoma: First Results of a Phase Ib Clinical Trial. *Clin Cancer Res* 2021;27(04):1037–1047. Doi: 10.1158/1078-0432.CCR-20-3449
- 45 Van Not OJ, Verheijden RJ, Van den Eertwegh AJM, et al. Association of Immune-Related Adverse Event Management With Survival in Patients With Advanced Melanoma. *JAMA Oncol* 2022;8(12):1794–1801. Doi: 10.1001/jamaoncol.2022.5041
- 46 Bass AR, Abdel-Wahab N, Reid PD, et al. Comparative safety and effectiveness of TNF inhibitors, IL6 inhibitors and methotrexate for the treatment of immune checkpoint inhibitor-associated arthritis. *Ann Rheum Dis* 2023;82(07):920–926. Doi: 10.1136/ard-2023-223885
- 47 Ma VT, Lao CD, Fecher LA, Schiopu E. Successful use of secukinumab in two melanoma patients with immune checkpoint inhibitor-induced inflammatory arthropathy. *Immunotherapy* 2022;14(08):593–598. Doi: 10.2217/imt-2021-0274
- 48 Li YJ, Msaouel P, Campbell M, Hwu P, Diab A, Kim ST. Successful management of pre-existing psoriatic arthritis through targeting the IL-23/IL-17 axis in cancer patients receiving immune checkpoint inhibitor therapy: a case series. *RMD Open* 2024;10(03):e004308. Doi: 10.1136/rmdopen-2024-004308
- 49 Dimitriou F, Cheng PF, Saltari A, et al. A targetable type III immune response with increase of IL-17A expressing CD4<sup>+</sup> T cells is associated with immunotherapy-induced toxicity in melanoma. *Nat Cancer* 2024;5(09):1390–1408. Doi: 10.1038/s43018-024-00810-4
- 50 Asher N, Bar-Hai N, Ben-Betzalel G, et al. Exploring the clinical significance of specific immune-related adverse events in melanoma patients undergoing immune checkpoint inhibitor therapy. *Melanoma Res* 2024;34(05):439–449. Doi: 10.1097/CMR.0000000000000985
- 51 Nakagomi Y, Tajiri K, Shimada S, et al. Immune Checkpoint Inhibitor-Related Myositis Overlapping With Myocarditis: An Institutional Case Series and a Systematic Review of Literature. *Front Pharmacol* 2022;13:884776. Doi: 10.3389/fphar.2022.884776
- 52 Hamada N, Maeda A, Takase-Minegishi K, et al; YCU irAE Working Group. Incidence and Distinct Features of Immune Checkpoint Inhibitor-Related Myositis From Idiopathic Inflammatory Myositis: A Single-Center Experience With Systematic Literature Review and Meta-Analysis. *Front Immunol* 2021;12:803410. Doi: 10.3389/fimmu.2021.803410
- 53 Schneider BJ, Naidoo J, Santomaso BD, et al. Management of Immune-Related Adverse Events in Patients Treated With Immune Checkpoint Inhibitor Therapy: ASCO Guideline Update. *J Clin Oncol* 2021;39(36):4073–4126. Doi: 10.1200/JCO.21.01440
- 54 Haanen J, Obeid M, Spain L, et al; ESMO Guidelines Committee. Electronic address: clinicalguidelines@esmo.org. Management of toxicities from immunotherapy: ESMO Clinical Practice Guideline for diagnosis, treatment and follow-up. *Ann Oncol* 2022;33(12):1217–1238. Doi: 10.1016/j.annonc.2022.10.001
- 55 Jespersen MS, Fanø S, Stenør C, Møller AK. A case report of immune checkpoint inhibitor-related steroid-refractory myocarditis and myasthenia gravis-like myositis treated with abatacept and mycophenolate mofetil. *Eur Heart J Case Rep* 2021;5(11):ytab342. Doi: 10.1093/ehjcr/ytab342
- 56 Solimando AG, Crudele L, Leone P, et al. Immune Checkpoint Inhibitor-Related Myositis: From Biology to Bedside. *Int J Mol Sci* 2020;21(09):3054. Doi: 10.3390/ijms21093054
- 57 Salem JE, Bretagne M, Abbar B, et al. Abatacept/Ruxolitinib and Screening for Concomitant Respiratory Muscle Failure to Mitigate Fatality of Immune-Checkpoint Inhibitor Myocarditis. *Cancer Discov* 2023;13(05):1100–1115. Doi: 10.1158/2159-8290.CD-22-1180
- 58 Mössner R, Zimmer L, Berking C, et al. Erythema nodosum-like lesions during BRAF inhibitor therapy: Report on 16 new cases and review of the literature. *J Eur Acad Dermatol Venereol* 2015;29(09):1797–1806. Doi: 10.1111/jdv.13039

- 59 Grogan N, Swami U, Bossler AD, Zakharia Y, Milhem M. Toxicities with targeted therapies after immunotherapy in metastatic melanoma. *Melanoma Res* 2018;28(06):600–604. Doi: 10.1097/CMR.0000000000000493
- 60 Xia CY, Wang DY, Mason R, et al. Activity of targeted therapy after failure of first-line immunotherapy in BRAF-mutant metastatic melanoma. *J Clin Oncol* 2018;36( 15 suppl):9532. Doi: 10.1200/JCO.2018.36.15\_suppl.9532
- 61 Vanneman M, Dranoff G. Combining immunotherapy and targeted therapies in cancer treatment. *Nat Rev Cancer* 2012;12(04):237–251. Doi: 10.1038/nrc3237
- 62 Yordanova K, Pfoehler C, Schweitzer LF, Bourg C, Adam L, Vogt T. Etanercept leads to a rapid recovery of a Dabrafenib-/Trametinib-associated toxic epidermal necrolysis-like severe skin reaction. *Skin Health Dis* 2022;3(01):e185. Doi: 10.1002/ski2.185
- 63 Cappelli LC, Shah AA, Bingham CO III. Immune-Related Adverse Effects of Cancer Immunotherapy- Implications for Rheumatology. *Rheum Dis Clin North Am* 2017;43(01):65–78. Doi: 10.1016/j.rdc.2016.09.007
- 64 Salem JE, Allenbach Y, Vozy A, et al. Abatacept for Severe Immune Checkpoint Inhibitor-Associated Myocarditis. *N Engl J Med* 2019; 380(24):2377–2379. Doi: 10.1056/NEJMc1901677